Check for updates

ORIGINAL ARTICLE

Does perivascular fibrin glue application have a preventive effect for the endothelial damage on saphenous vein graft? An experimental model

¿La aplicación de pegamento de fibrina perivascular tiene un efecto preventivo del daño endotelial en el injerto de vena safena? Un modelo experimental

Serdar Badem[1], Nail Kahraman[1], Ezgi Isil-Turhan[2], Temmuz Taner[1], Deniz Demir[1], Didem Melis-Oztas[3], and Murat Ugurlucan[4]*

[1]Department of Cardiovasculary Surgery, Bursa City Hospital, Surgeon, Bursa; [2]Department of Pathology, Bursa City Hospital, Bursa; [3]Department of Cardiovasculary Surgery, Istanbul Education and Research Hospital; [4]Department of Cardiovascular Surgery, Istanbul Medipol University Faculty of Medicine.Turkey

Abstract

Background. *The effect of tissue adhesives on coronary grafts in cardiac surgery is a controversial issue.* **Objective.** *The aim of this study is to investigate the effect of fibrin glue (FG) applied around the saphenous vein grafts (SVG) in preventing cellular damage resulting from intraluminal pressure increase.* **Methods.** *Twenty volunteer patients were included in this ex vivo study. The SVGs remained after coronary artery bypass grafting were connected to the arterial line of the cardiopulmonary bypass circuit. The grafts were divided into two segments and one segment received perivascular FG applied whereas the other part was used plain. SVGs were kept in circulation at 120 mmHg pressure 250 mL/min flow rate for 60 min. The tissues were sent for histopathological examination to determine the endothelial damage.* **Results.** *Endothelial damage was more pronounced in the control group when compared with the FG group. In the FG group, no damage was seen in 13 samples and no Type 3 endothelial damage was observe whereas Type 1 injury was detected in seven specimens, Type 2 injury was observed in seven specimens, and Type 3 injury was detected in two specimens in the control group.* **Conclusion.** *Perivascular application of FG on the SVG showed a protective effect against endothelial damage resulting from increased intraluminal pressure.*

Keywords: *Fibrin glue. Saphenous vein graft. Endothelial damage.*

Resumen

Antecedentes. *El efecto de los adhesivos tisulares sobre los injertos coronarios en cirugía cardíaca es un tema controvertido.* **Objetivo.** *Investigar el efecto del pegamento de fibrina aplicado alrededor de los injertos de vena safena para prevenir el daño celular resultante del aumento de la presión intraluminal.* **Método.** *En este estudio ex vivo fueron incluidos 20 pacientes voluntarios. Los injertos de vena safena que quedaron después del injerto de derivación de la arteria coronaria se conectaron a la línea arterial del circuito de derivación cardiopulmonar. Los injertos se dividieron en dos segmentos y a uno de ellos se le aplicó pegamento de fibrina perivascular, mientras que la otra parte se usó sola. Los injertos de vena safena se mantuvieron en circulación a una presión de 120 mmHg y una velocidad de flujo de 250 ml/min durante 60 minutos. Los tejidos se enviaron para examen histopatológico para determinar el daño endotelial.* **Resultados.** *El daño endotelial fue más pronunciado en el grupo de control*

***Correspondence:**
Serdar Badem
E-mail: serdarbadem@hotmail.com

Date of reception: 01-03-2022
Date of acceptance: 24-07-2022
DOI: 10.24875/CIRUE.M22000539

Cir Cir (Eng). 2023;91(2):206-211
Contents available at PubMed
www.cirugiaycirujanos.com

2444-0507/© 2022 Academia Mexicana de Cirugía. Published by Permanyer. This is an open access article under the terms of the CC BY-NC-ND license (http://creativecommons.org/licenses/by-nc-nd/4.0/).

que en el grupo de pegamento de fibrina. Se observó lesión de tipo 2 en siete muestras del grupo de pegamento de fibrina y lesión de tipo 3 en dos muestras del grupo de control. **Conclusiones.** *La aplicación perivascular de pegamento de fibrina en los injertos de vena safena mostró un efecto protector contra el daño endotelial resultante del aumento de la presión intraluminal.*

Palabras clave: *Pegamento de fibrina. Injerto de vena safena. Daño endotelial.*

Introduction

Coronary artery bypass grafting is performed worldwide for the relief of angina symptoms and long survival in the presence of coronary artery disease. Although there are attempts to develop technical and medical procedures to increase graft patency, new studies are still needed. Saphenous veins are frequently used as grafts due to the insufficient number of arterial grafts. Graft patency rates depend on many factors and are affected by the patient's risk factors, high arterial pressure, and surgical techniques. The overall angiographic patency rates for arteries were 95.7%, 90.1%, and 92.2% on early, 1-year, and 5-year angiograms, respectively, in a study. The angiographic patency rates of saphenous vein grafts (SVG) were 93.1%, 85.6%, and 91.3% on early, 1-year, and 5-year angiograms, respectively, in the same study[1]. Many factors such as endothelial damage, intimal hyperplasia and intraluminal thrombus are among the causes of early SVG failure[2]. Minimizing SVG damage will significantly reduce patients' mortality and morbidity rates.

The SVGs are prone to pulsatile arterial pressure related damage in the post-operative period. Permanent injury occurs especially in the endothelial layer and an inflammatory process begins. Uncontrolled proliferation and cell migration in endothelial cells, hyperplasia in vascular smooth muscle cells and formation of myofibroblasts result in neointimal hyperplasia[3,4]. Therefore, SVG occlusion starts and patency is shortened. To prevent damage due to intraluminal arterial pressure in vein grafts; there are studies in the literature regarding perivenous support, tissue adhesives, and various medical treatments[3-6].

The aim of this study is to investigate the effect of perivascular application of fibrin glue (FG), which is used as a tissue adhesive, against endothelial damage and intimal thickening in SVG.

Material and methods

This *ex vivo* study was conducted following approval from the Local Ethics Committee (Bursa City Hospital Ethics Committee, Date: 16/06/2021, No: 2021-11/4). In this study, 20 excess SVG from patients who underwent coronary artery surgery at our institution were used. Average length of 4 cm excess SVG were divided into two segments. Perivascular FG was applied to one segment and was included in the treatment group. The other saphenous vein was not treated with FG and was included in the control group. A total of 40 SVGs were studied, from 20 subjects in each group.

The intraluminal pressure was provided with the cardiopulmonary bypass machine which was used during coronary artery bypass grafting in each patient. The experiment began after the patient was transferred from the operating room after CABG surgery. Appropriate cannulae were connected to both ends of the SVG. An arterial line was connected to one end of the saphenous vein and a venous line was connected to the other end, and an arterial system model was created with a cardiopulmonary bypass machine (Fig. 1). A manometer was connected to the venous line to record the pressure within the SVG. FG was sprayed on the outer surface of one of the SVGs and left to dry for 3 min. The other SVG did not receive any treatment. This arterial system model was exposed to blood flow for 60 min with a mean pressure of 120 mmHg. After the experiment, the materials were collected for histopathological examination.

The patients who received emergency operation, whom underwent off-pump surgery, had insufficient excess saphenous vein graft, had hematologic and oncologic comorbidities, and were not volunteered were excluded from the study.

Histopathological examination

The extracted grafts were kept in 10% buffered formaldehyde solution for 24 h. After tissue sampling and routine tissue follow-up procedures, 5 μm-thick sections were taken from the samples fixed in the formalin of the material and embedded in paraffin, and stained with hematoxylin-eosin (H&E). Preparations stained with H&E were examined and the preparations that best represented vessel morphology were selected.

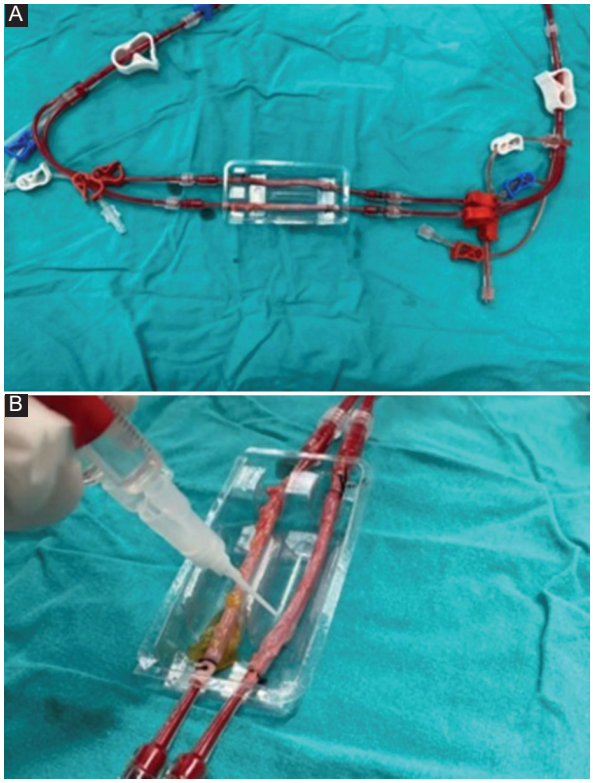

Figure 1. A: *setting up the experimental setup and creating an arterial model with saphenous veins.* **B:** *perivascular fibrin glue applied to one of the saphenous vein grafts, prepared from the same patient, for the purpose of external support.*

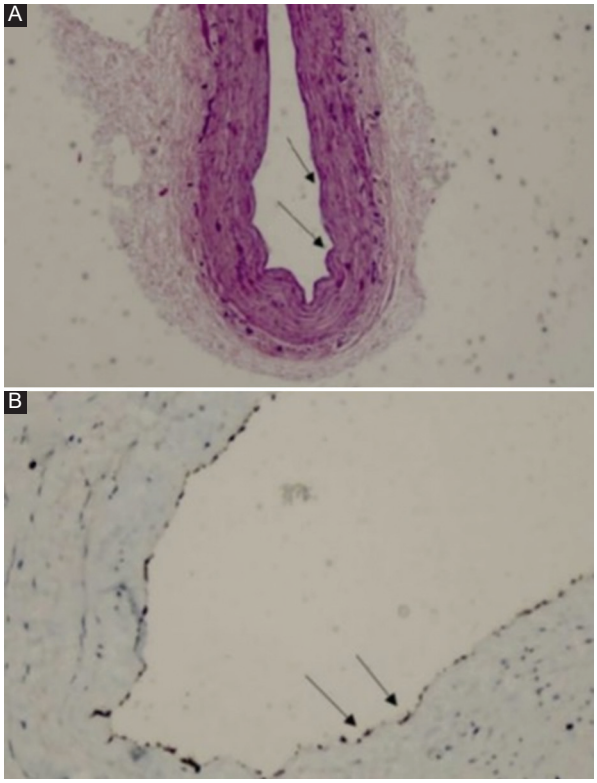

Figure 2. A: *all endothelial cells are in contact with each other, no separation between layers (H&E, ×4).* **B:** *endothelial layer shows all-round labeling with CD31 (CD31 immunohistochemistry, ×10).*

In the immunohistochemical study, endothelial markers CD31 (clone EP78) and CD34 (clone QBend-10) dyes were used. Immunohistochemical staining was done with an automatic stainer (Ventana BenchMark Ultra) according to the protocols recommended by the instructions of use of the manufacturers.

The histomorphological classification of endothelial damage was made according to the classification made by Ip et al. as follows[7].

No damage: All endothelial cells are interconnected. There is no change in cell sizes, no separation between layers (Fig. 2).

- Type 1 damage: Endothelial cell integrity is preserved and all the cells are in contact with each other, but a decrease in the diameter of the endothelial cells is observed. There are slight separations in the intima and/or media layers of the vessel (Fig. 3).
- Type 2 damage: The connections between endothelial cells are broken in places and there is loss of endothelial cells in places. There are more distinct separations in the intima and/or media layers of the vessel (Fig. 4).

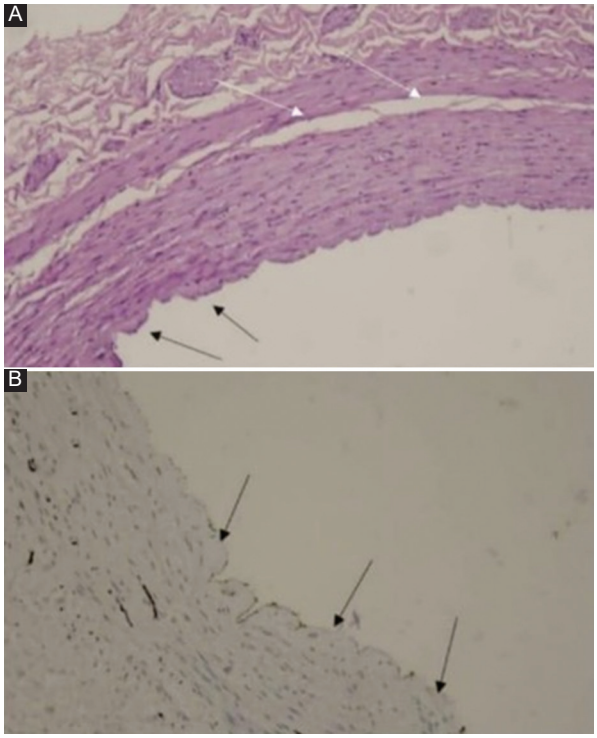

Figure 3. A: *slight loss of endothelial cells (black arrows) and slight separation in the tunica media (white arrows) (H&E, ×4).* **B:** *local endothelial cell losses are observed between CD31-marked endothelial cells (black arrows) (CD31 immunohistochemistry, ×20).*

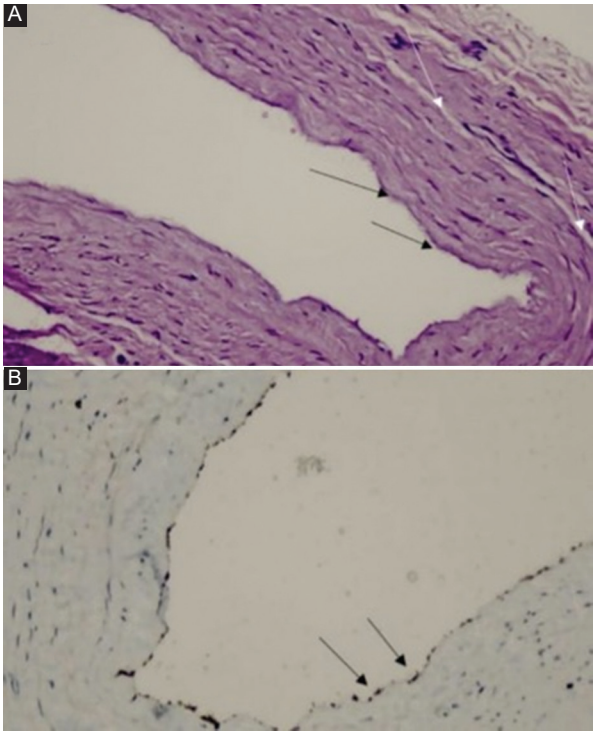

Figure 4. A: *there are local losses (black arrows) in endothelial cells and significant separation in the media layer (H&E, ×10).* **B:** *endothelial cells labeled with CD34 and areas of loss of endothelial cells not labeled with CD34 are seen (black arrows) (CD34 immunohistochemistry, ×10).*

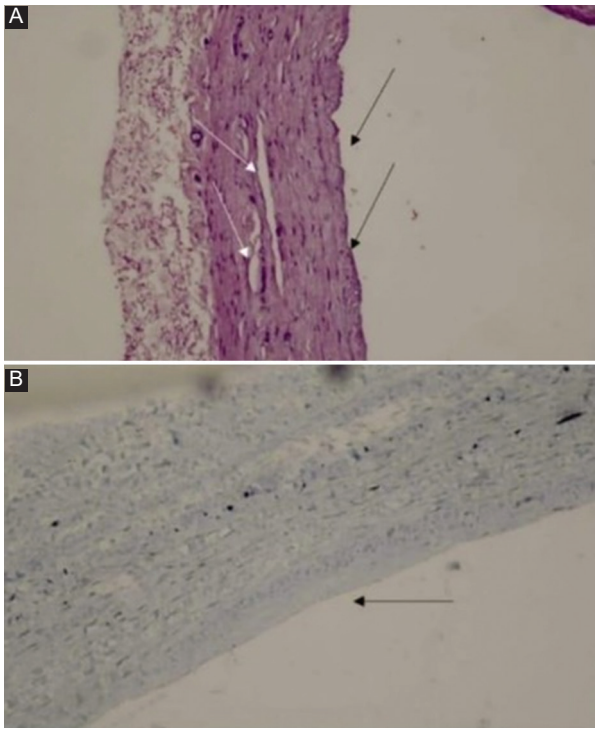

Figure 5. A: *significant loss of endothelial cells (black arrows) and stratification (white arrows) (H&E, ×10).* **B:** *no labeling of the endothelium with CD31 (black arrow) (CD31 immunohistochemistry, ×10).*

– Type 3 damage: The endothelial cell layer is lost. There are significant separations in the intima and/or media layer of the vessel (Fig. 5).

Statistical analysis

Data were categorical and calculated using IBM SPSS Statistics v.25. The Chi-square method was used to analyze two independent categorical data. Pearson Chi-square method was used for analysis if the expected count below 20% of the cells was < 5. Fisher's Exact Test was used when over 20% of the cells' expected count was < 5. Continuity correction was used when the expected value over 20% of the cells was between 5 and 25, and Pearson Chi-square were used if the expected value over 20% of the cells was > 25. $p < 0.05$ was accepted as statistically significant.

Results

According to the endothelial injury classification, no significant injury was observed in four specimens, Type 1 injury was detected in seven specimens, Type 2 injury was observed in seven specimens, and Type 3 injury was detected in two specimens in the control group. In the FG treatment group, endothelial damage was not observed in 13 samples, Type 1 damage was observed in five samples and Type 2 damage was observed in two samples. No Type 3 endothelial damage was observed in the FG treatment group.

There was no significant change in saphenous vein diameter in the group treated with FG. Endothelial damage secondary to intraluminal pressure developed less. The increase in SVG diameter and endothelial damage due to severe distension in the SVG occurred in the control group compared to the treatment group. While no serious damage was observed in the histopathological examination of SVG taken from the FG treatment group, severe endothelial damage and tunica media defects were observed in the control group. Endothelial damage was significantly less in the FG treatment group, as demonstrated in the evaluation of results between groups (Table 1).

Discussion

Coronary artery bypass grafting continues to be an important surgical treatment to increase the quality and duration of life in patients with coronary artery disease affecting more than one vessel. Long-term

Table 1. Distribution of saphenous vein injury in the groups as per classification

Vascular damage class	Group 1 (FG) (n = 20)	Group 2 (control) (n = 20)	p value
No injury n (%)	13 (65)	4 (20)	0.004
Type 1 endothelial damage n (%)	5 (25)	7 (35)	0.490
Type 2 endothelial damage n (%)	2 (10)	7 (35)	0.127
Type 3 endothelial damage n (%)	0 (0)	2 (10)	0.487

success is determined by graft success. Neointimal hyperplasia may develop in a short time, especially in venous grafts, and early occlusions may occur.

In this study, which was carried out by creating an *ex vivo* model; human SVG was used. This study shows that perivenous support with FG and exposed to arterial pressure can reduce endothelial damage in SVG.

FG was used as a topical surgical adhesive. It consists of human fibrinogen and bovine thrombin activated with calcium chloride. It is an agent that can be absorbed without the development of foreign body reaction and extensive fibrosis by increasing wound healing as well as its hemorrhage-stopping effect[8].

Fibrin and fibrin degradation products are chemotactic agents on vascular tissue. FG applied around the venous graft increases smooth muscle and fibroblastoid cell migration. In this way, it promotes outward remodeling or adhesion formation between the vessel and the underlying tissue. An intact endothelial layer prevents thrombus formation within the vessel and thus limits the migration of smooth muscle cells into the intima. Besides external vascular support, the protection of the endothelial layer and its modulating effect on smooth muscle cell migration may further reduce the stimulus for intimal hyperplasia[9]. Due to the stretching of the SVG wall due to increased intraluminal pressure, phosphorylation of p38 mitogen-activated protein kinase is induced and has been shown to cause apoptosis[10].

Therefore, as a result of mechanical stress, it causes destruction of alpha actin filament in venous smooth muscle cells[11]. Loss of endothelial integrity due to mechanical stress causes activation of coagulation factors and endothelial growth factors, resulting in platelet aggregation[12]. Venous smooth muscle cells differentiate. Matrix metalloprotease activity is increased, leading to increased expression of cytoskeleton-associated proteins that promote migration and proliferation of smooth muscle cells[13].

The protective effect of FG backing on human SVG segments is comparable to our previous findings of perivenous cyanoacrylate adhesive backing. We have shown that perivenous cyanoacrylate adhesive support provides external support to the graft without any chemotactic effect in SVGs and provides primary protection of the graft against damage from excessive stress[14].

Stooker et al. performed a similar study on the saphenous vein under lower intraluminal pressure (60 mmHg) and explained that by providing adequate external vein support with FG, they prevented excessive stretching and prevented endothelial damage at low pressures[15]. The difference of our study from this study is; We demonstrated the protective effect of FG against changes in SVG under 120 mmHg pressure. The results of our study are shown in table 1 in detail. Ip et al. divided coronary artery endothelial injury into three types[7].

Endothelial damage was defined as: Type 1 injury: normal morphology despite functional changes in the endothelial layer; Type 2 injury: endothelial layer detachment, local peeling, and preservation of the inner elastic lamina and medial layer despite intimal damage; and Type 3 damage: peeling of the endothelial layer followed by the formation of lower endothelial tissue and intimal and medial damage in the corresponding classification. He reported that especially Type 3 injury may result in stenosis and occlusion in the coronary artery. No Type 3 endothelial injury was observed in our FG treatment group (Table 1).

Okazaki et al. classified endothelial injury into five stages[16]. The classification includes Stage 1: normal morphology; Stages 2 and 3: minor or diffuse adhesion of blood cells (corresponding to Type 1 injury); Stage 4: rare isolated separation in endothelial cells (corresponding to Type 2 injury); and Stage 5: generalized lack of endothelial cells (corresponding to Type 3 injury). In particular, development of Type 3 (Stage 5) injury and widespread formation of a subendothelial layer will lead to platelet aggregation and the formation of thrombus as a result of contact between blood components and this layer. This will trigger smooth muscle proliferation and migration with

mitogen factors; hence, this may result in early or late stenosis or occlusion in the anastomosis area.

When endothelial damage was classified in our study; while no significant injury was observed in four specimens in the control group, Type 1 injury was detected in seven specimens, Type 2 injury in seven specimens, and Type 3 injury in two specimens. In the FG treatment group, endothelial damage was not observed in thirteen samples, while Type 1 damage was observed in five samples and Type 2 damage was observed in two samples. No Type 3 endothelial damage was observed in the FG treatment group. As shown in the evaluation of the results between groups, endothelial damage was found to be significantly less in the FG group (Table 1).

In this study, we showed that the application of FG on the perivenous SVG provides extravascular support and also prevents endothelial damage due to increased intraluminal pressure and mechanical stress.

Lımıtatıons of the study

Our study has some limitations. The major limitation of our study is the lack of long-term results. Another limitation is that it is conducted with a small number of samples.

Conclusion

Perivascular application of fibrinogen glue on the saphenous vein showed a protective effect against endothelial damage secondary to high intraluminal pressure. External vein graft support with FG may provide adequate protection against SVG injury in the early period and may promote remodeling of the vein graft in line with arterial wall properties.

In this study, FG application showed that it provided external support to the graft without any chemotactic effect and provided primary protection of the graft against endothelial damage caused by high pressure. For this reason, we believe that graft patency rates will be better thanks to the effect of preventing the endothelial damage caused by mechanical and chemical means, as well as the hemorrhage-stopping effect of FG. However, more *in vivo* studies are needed to investigate the effects on the graft in the long-term.

Funding

The authors declare that they have not received funding for this study.

Conflicts of interest

The authors declare that they have no conflicts of interest.

Ethical disclosures

Protection of human and animal subjects. The authors declare that no experiments were performed on humans or animals for this study.

Confidentiality of data. The authors declare that they have followed the protocols of their work center on the publication of patient data.

Right to privacy and informed consent. The authors have obtained the written informed consent of the patients or subjects mentioned in the article. The corresponding author is in possession of this document.

References

1. Sohn SH, Kim SH, Hwang HY, Kim KB. Mid-term outcomes and angiographic patency of redo coronary artery bypass grafting: a comparison between off-pump and on-pump surgery. J Chest Surg. 2021;54:106-16.
2. Kouzi-Koliakos K, Kanellaki-Kyparissi M, Marinov G, Knyazhev V, Tsalie E, Batzios C, et al. Prebypass histological and ultrastructural evaluation of the long saphenous vein as a predictor of early graft failure. Cardiovasc Pathol. 2006;15:336-46.
3. Wan S, Arifi AA, Chan MC, Yip JH, Ng CS, Chow LT, et al. Differential, time-dependent effects of perivenous application of fibrin glue on medial thickening in porcine saphenous vein grafts. Eur J Cardiothorac Surg. 2006;29:742-6.
4. Angelini GD, Lloyd C, Bush R, Johnson J, Newby AC. An external, oversized, porous polyester stent reduces vein graft neointima formation, cholesterol concentration, and vascular cell adhesion molecule 1 expression in cholesterol-fed pigs. J Thorac Cardiovasc Surg. 2002;124:950-6.
5. Stooker W, Niessen HW, Baidoshvili A, Wildevuur WR, Van Hinsbergh VW, Fritz J, et al. Perivenous support reduces early changes in human vein grafts: studies in whole blood perfused human vein segments. J Thorac Cardiovasc Surg. 2001;121:290-7.
6. Wan S, Yim AP, Johnson JL, Shukla N, Angelini GD, Smith FC, et al. The endothelin 1A receptor antagonist BSF 302146 is a potent inhibitor of neointimal and medial thickening in porcine saphenous vein-carotid artery interposition grafts. J Thorac Cardiovasc Surg. 2004;127:1317-22.
7. Ip JH, Fuster V, Badimon L, Badimon J, Taubman MB, Chesebro JH, et al. Syndromes of accelerated atherosclerosis: role of vascular injury and smooth muscle cell proliferation. J Am Coll Cardiol. 1990;15:1667-87.
8. Brennan M. Fibrin glue. Blood Rev. 1991;5:240-4.
9. Nomura H, Naito M, Iguchi A, Thompson WD, Smith EB. Fibrin gel induces the migration of smooth muscle cells from rabbit aortic explants. Thromb Haemost. 1999;82:1347-52.
10. Cornelissen J, Armstrong J, Holt CM. Mechanical stretch induces phosphorylation of p38-MAPK and apoptosis in human saphenous vein. Arterioscler Thromb Vasc Biol. 2004;24:451-6.
11. Goldman J, Zhong L, Liu SQ. Degradation of alpha-actin filaments in venous smooth muscle cells in response to mechanical stretch. Am J Physiol Heart Circ Physiol. 2003;284:H1839-47.
12. Reid MA. Factors controlling smooth-muscle cell proliferation. Arch Pathol Lab Med. 1992;116:1276-80.
13. Johnson JL, van Eys GJ, Angelini GD, George SJ. Injury induces dedifferentiation of smooth muscle cells and increased matrix-degrading metalloproteinase activity in human saphenous vein. Arterioscler Thromb Vasc Biol. 2001;21:1146-51.
14. Kahraman N, Yumun G, Gücü A, Özsin KK, Taner T, Şener E, et al. Administration of perivascular cyanoacrylate for the prevention of cellular damage in saphenous vein grafts: an experimental model. Cardiovasc J Afr. 2016;27:159-63.
15. Stooker W, Niessen HW, Wildevuur WR, van Hinsbergh VW, Fritz J, Jansen EK, et al. Perivenous application of fibrin glue reduces early injury to the human saphenous vein graft wall in an *ex vivo* model. Eur J Cardiothorac Surg. 2002;21:212-7.
16. Okazaki Y, Takarabe K, Murayama J, Suenaga E, Furukawa K, Rikitake K, et al. Coronary endothelial damage during off-pump CABG related to coronary-clamping and gas insufflation. Eur J Cardiothorac Surg. 2001;19:834-9.