Check for updates

ORIGINAL ARTICLE

# Ultrasound biomicroscopy and stability of intraocular lens in patients with myopia after phacoemulsification cataract surgery

## *Ultrabiomicroscopía ultrasónica y estabilidad de la lente intraocular en pacientes con miopía axial sometidos a cirugía de facoemulsificación*

*Jessica P. García-Chávez[1], Mónica M. Meléndez-Abanto[1], Óscar Guerrero-Berger[1], Humberto Wong-Chavarria[2], Héctor J. Pérez-Cano[3], and Cristina Mendoza-Velásquez[1]**

*[1]Departamento de Microcirugía de Segmento Anterior; [2]Imagenología Ocular y Orbitaria; [3]Centro de Investigación Biomédica. Fundación Hospital Nuestra Señora de la Luz I.A.P., Mexico City, Mexico*

## Abstract

**Purpose:** *To evaluate the stability and the refractive error of the different intraocular lens (IOL) after cataract surgery.* **Method:** *Retrospective, observational and single-center study. Patients diagnosed with cataract and myopia who underwent a phacoemulsification surgery with intraocular lens placement without complications were included. All patients underwent a complete ophthalmological examination, ultrasound biomicroscopy was performed at 2 weeks, 1 and 3 months after surgery. Descriptive statistics were performed using measures of central tendency and comparative analyzes. A value of $p < 0.05$ was considered significant.* **Results:** *Thirty-one subjects with a diagnosis of axial myopia and senile cataract were included, 20 women (64.5%) and 11 men (35.5%), with a mean age was 62.8 ± 13.14 years. The IOL displacement were not different for the upper, lower, temporal and nasal quadrants; however, we observed a tendency to inclination to the temporal sector ($p = 0.054$) between the first and third postoperative month. Therefore, the were no significant differences in spherical equivalent between groups postoperatively.* **Conclusions:** *The inclination of the IOL did not change over time after surgery, the changes were similar with the different three types of IOL.*

***Keywords:*** *Phacoemulsification. Intraocular lens. Myopia. Ultrasound biomicroscopy.*

## Resumen

**Objetivo:** *Evaluar la estabilidad y el desplazamiento de diferentes lentes intraoculares (LIO) a los 3 meses y los cambios refractivos asociados después de la facoemulsificación.* **Método:** *Estudio retrospectivo, observacional y unicéntrico. Se revisaron expedientes de pacientes sometidos a cirugía de facoemulsificación con colocación de LIO. Se realizó un examen oftalmológico completo, ultrabiomicroscopía a las 2 semanas, 1 y 3 meses después de la cirugía. Se realizó estadística descriptiva y análisis comparativos. Se tomó como diferencia significativa un valor de $p < 0.05$.* **Resultados:** *Se incluyeron 31 ojos con diagnóstico de miopía y catarata senil, 20 mujeres (64.5%) y 11 hombres (35.5%), con una edad media de 62.8 ± 13.14 años. En cuanto al desplazamiento de la LIO, no se observaron diferencias significativas para los cuadrantes superior, inferior, temporal y nasal. Se observa una tendencia hacia temporal ($p = 0.054$) entre el primer y el tercer mes posoperatorios. El equivalente esférico tampoco mostró diferencias.* **Conclusiones:** *El desplazamiento de la LIO no cambió con el tiempo después de la facoemulsificación. Los cambios fueron similares con los tres diferentes tipos de LIO y al compararlos proporcionan estabilidad refractiva en pacientes miopes.*

***Palabras clave:*** *Facoemulsificación. Lente intraocular. Miopía. Ultrabiomicroscopía.*

***Correspondence:**
Cristina Mendoza-Velásquez
E-mail: cristina_cmv@hotmail.com

Date of reception: 19-09-2021
Date of acceptanca: 27-01-2022
DOI: 10.24875/CIRUE.M23000434

Cir Cir (Eng). 2023;91(1):104-109
Contents available at PubMed
www.cirugiaycirujanos.com

2444-0507/© 2022 Academia Mexicana de Cirugía. Published by Permanyer. This is an open access article under the terms of the CC BY-NC-ND license (http://creativecommons.org/licenses/by-nc-nd/4.0/).

## Introduction

Age-related cataract and myopia are among the main causes of visual disability in both developed and developing countries. With the currently increasing life expectancy worldwide, the impact of age-related cataracts is expected to rise. Pan et al.[1] observed that myopia was associated with a higher prevalence of nuclear and posterior subcapsular cataracts.

Despite achievements in standardizing surgical techniques, developing better intraocular lenses (IOL) power calculation formulas, and more precise biometry techniques, refractive surprises are still a significant problem[2]. After uncomplicated cataract surgery, any changes to the IOL optics can lead to unexpected visual outcomes, such as residual astigmatism or higher-order aberrations, being IOL tilt and decentration among the main contributing factors[3].

Ultrabiomicroscopy (UBM) provides accurate and reliable in vivo imaging of the anterior segment and IOL, making it a useful method to confirm that the IOL is inside the capsular bag and measure the depth of the pseudophakic anterior chamber[4], defined as the distance from the central corneal endothelium to the IOL anterior surface, which serves as an indicator of the IOL axial position. Errors predicting the IOL axial position impact postoperative refractive errors significantly. IOL tilt can cause both spherical and cylindrical errors. Thus, the IOL forward movement from its effective position results in myopia, while backward movement leads to hypermetropia[5]. Capsular bag fibrosis, zonular status, and the IOL characteristics (material, haptic design, and diameter) have been reported to play a significant role in the IOL axial position and the final pseudophakic anterior chamber depth[5]. Although refractive results are not the sole measure of success, predictable refractive results and prompt stabilization serve to improve the patients' function and satisfaction[6].

The objective of this study was to assess the stability and displacement of different IOLs over time as well as their refractive impact on myopic patients after cataract surgery.

## Method

This was a retrospective, observational, and single-center study that reviewed a total of 38 health records, 31 of which met the inclusion criteria: patients who underwent uncomplicated phacoemulsification surgery with IOL placement, treated in the anterior segment unit of our hospital from March through November 2019, after providing their written informed consent. The study was approved by our center Research Ethics Committee. The study design was conducted in observance of the principles of the Declaration of Helsinki (1975) and its revised version from 2013. Data were anonymized regarding collection and analysis to preserve data privacy.

All patients underwent a comprehensive eye examination, including medical history, visual acuity, refraction, keratometry, slit-lamp biomicroscopy, applanation tonometry, and indirect ophthalmoscopy. The surgical technique involved phacoemulsification and aspiration through a clear corneal incision, followed by IOL implantation in the capsular bag. The IOL selection was randomized, and 3 types of IOLs were assigned due to their wide dioptric range: enVista MX60E (Bausch & Lomb, Rochester, New York, United States), ASPHINA CT 509M (Carl Zeiss Meditec, Jena, Germany), and AcrySof MA60MA (Alcon Laboratories, Inc., Fort Worth, TX, United States). Exclusion criteria included any history of ocular trauma, vitreoretinal surgery, and ocular inflammatory diseases. Patients with surgical complications requiring changes to the surgical technique described were also cleared from the study.

The UBM was performed using a Vumax HD SonoMed Escalón device after 2 weeks, and 1 and 3 months after surgery using a 35 MHz transducer that produces images with 50 μm resolution and 4 mm tissue penetration in ocular tissues. The eye examinations were performed under constant room illumination, while the patient was lying on his/her back in the supine position. Accommodation remained constant by asking the patient to focus on a small point of light held 1 m away from the other eye and look at the ceiling, where there is a mirror that duplicates the distance between the patient's eye and the mirror, resulting in a total distance of 4 m, thus allowing for accommodation relaxation. The UBM was performed by the same specialist in eye ultrasounds. Calibrators included in the machine software were used, and the following variables were measured: anterior chamber depth from the center of the cornea at endothelial level to the echoes of the IOL anterior surface, iris, and distance of IOL contact. The optics was considered tilted with differences > 0.1 mm in the distance between the 2 edges of the optics and the plane of the iris in any UBM section.

Descriptive statistics, including measures of central tendency, were used. Before conducting comparative

analyses, the Kolmogorov-Smirnov test was used to assess data distribution, and the proper parametric and non-parametric tests were performed sometime later. P values < 0.05 were considered statistically significant. GraphPad Prism V5.0 software (San Diego, CA, United States) was used for analysis.

## Results

This study included 38 eyes, 7 of which were excluded because they were lost to follow-up. The final study sample included 31 eyes (17 right and 14 left eyes) with a diagnosis of axial myopia and senile cataract. Among these patients, 20 were women (64.5%) and 11 were men (35.5%), with a mean age of 62.8 ± 13.14 years (ranging from 30 to 90 years). The baseline preoperative characteristics are shown on table 1.

Patients were randomized to 3 different groups based on the type of IOL implanted: 9 received enVista MX60E; 10, ASPHINA CT 509M; and 12, AcrySof MA60MA.

The mean age of the enVista group was 68 years; 77.8%, women. The maximum dioptric power used was +18.5 D, and the minimum, +3 D. The range of axial length was 28.4 ± 1.57 mm. The mean age of the ASPHINA group participants was 59 years; 40%, men, the maximum dioptric power used, +12.5 D, the minimum, 0 D, and the range of axial length, 28.9 ± 2.36 mm. Finally, the mean age of the MA60MA group was 67 years; 58.3%, women, the maximum dioptric power used, +16.0 D, the minimum, −5 D, and the range of axial length, 29.9 ± 3.31 mm.

The preoperative anterior chamber depth measured by partial coherence interferometry (Lenstar) increased significantly from a preoperative mean value of 3.603 ± 0.579 mm up to 5.310 ± 0.465 mm at 1 month, and up to 5.309 ± 0.482 mm 3 months after cataract surgery (p < 0.0001).

### *IOL displacement*

Across time, the enVista (Fig. 1), ASPHINA (Fig. 2), and MA60MA (Fig. 3) groups were not statistically different regarding each variable studied. The following p values were obtained in the groups studied: superior p = 0.091; inferior p = 0.104; nasal p = 0.329; and temporal p = 0.054. Similarly, individual comparisons were made for each period (Table 2) The contact distance between the iris and the IOL, measured by UBM, was similar in all postoperative periods without any significant inter-group differences being reported, which is indicative of stability in the capsular bag regardless of the characteristics of the MA60MA, ASPHINA, and enVista IOLs (Fig. 4).

**Table 1. Baseline preoperative characteristics of the patients**

| Characteristics | | p |
|---|---|---|
| Age, years (men/women) | 44-90/30-84 | 0.068* |
| Sex (men/women) ± SD | 35.5/64.5% ± 0.48 | 0.012* |
| Axial length, mm (RE/LE) | 28.9 ± 2.7/29.5 ± 2.5 | 0.533** |
| Anterior chamber depth ± SD | 3.6 ± | 0.58 |

LE: left eye; RE: right eye; SD: standard deviation.
*Mann-Whitney test.
**Student t test.

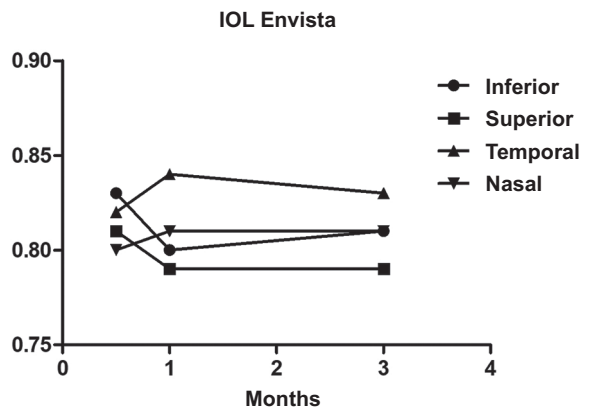


**Figure 1.** *Behavior of the enVista intraocular lens by sectors over time.*

### *Spherical equivalent*

Postoperative refractive stability occurs between weeks 2 and 6. Any axial displacement in the optical position of the IOL would be seen as a change in the anterior chamber depth, as well as a change in the refractive status. However, in our study, no significant differences were found, which could be attributed to the fact that the variation seen in the anterior chamber depth 3 months after surgery is < 1 mm and, therefore, uncapable of creating a clinically significant change in the spherical equivalent (Table 3).

## Discussion

The mechanical stability of IOLs is an important factor that should be taken into consideration because it

**Table 2. Displacement of intraocular lenses by sectors**

| | Week 2 Mean (SD) | Month 1 Mean (SD) | Month 2 Mean (SD) | p |
|---|---|---|---|---|
| Inferior deviation | | | | |
| enVista | 0.8311 (0.082) | 0.799 (0.124) | 0.806 (0.1079) | 0.796* |
| ASPHINA | 0.81 (0.082) | 0.915 (0.189) | 0.912 (0.201) | 0.374* |
| ASPHINA | 0.918 (0.176) | 0.930 (0.186) | 0.892 (0.251) | 0.895* |
| Superior deviation | | | | |
| enVista | 0.81 (0.082) | 0.788 (0.124) | 0.793 (0.115) | 0.904* |
| ASPHINA | 0.786 (0.152) | 0.878 (0.191) | 0.872 (0.196) | 0.454* |
| ASPHINA | 0.883 (0.183) | 0.898 (0.184) | 0.864 (0.243) | 0.924* |
| Temporal deviation | | | | |
| enVista | 0.823 (0.083) | 0.838 (0.123) | 0.828 (0.107) | 0.957* |
| ASPHINA | 0.827 (0.161) | 0.908 (0.214) | 0.930 (0.195) | 0.457* |
| ASPHINA | 0.925 (0.194) | 0.927 (0.189) | 0.905 (0.240) | 0.961* |
| Nasal deviation | | | | |
| enVista | 0.796 (0.080) | 0.808 (0.116) | 0.813 (0.106) | 0.93* |
| ASPHINA | 0.793 (0.155) | 0.891 (0.218) | 0.906 (0.195) | 0.371* |
| ASPHINA | 0.898 (0.195) | 0.886 (0.174) | 0.882 (0.233) | 0.978* |

SD: standard deviation.
*One-way ANOVA.

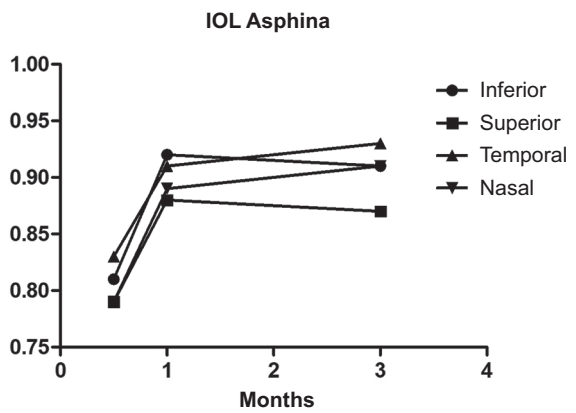


**Figure 2.** *Behavior of the ASPHINA intraocular lens by sectors over time.*

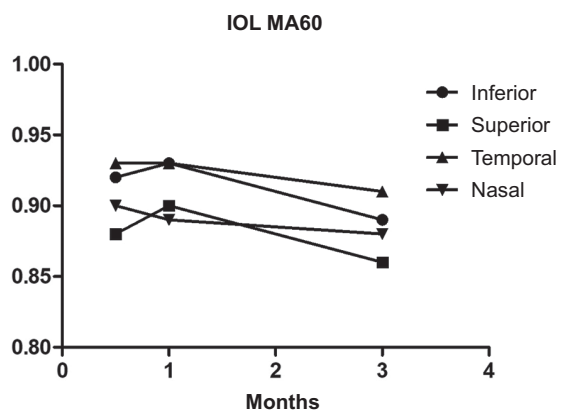


**Figure 3.** *Behavior of the MA60MA intraocular lens by sectors over time.*

impacts the refractive outcomes of cataract surgery, and, consequently, axial displacement can result in residual refractive errors. Postoperative refractive stability occurs between weeks 2 and 6. It has been reported that for every 1 mm change in the anterior chamber depth, there is a variation of 0.32 D in the spherical equivalent in the postoperative period.6 Standardizing procedures regarding UBM, and controlling accommodation and room illumination, are also essential to avoid any physiological changes in the parameters studied. The reproducibility of measurements taken by UBM has already been studied by other authors[7].

The anterior chamber depth increased significantly after surgery (approximately 1.706 mm; $p < 0.0001$) due to a backward movement of the iris diaphragm away from the inner surface of the cornea. It has been documented that IOL axial displacement is one of the main parameters associated with postoperative refractive changes[8]. Findl et al.[9] described that the IOL axial position changes within the first 3 months after surgery, which is why this period was chosen as the cut-off timeframe of our study.

It has been reported that the design of the IOL plays a significant role to determine the postoperative anterior chamber depth. Hayashi et al.[10] proved that, after cataract surgery, IOLs with rigid haptics often have better fixation in the capsule compared to IOLs with flexible haptics. However, the postoperative anterior

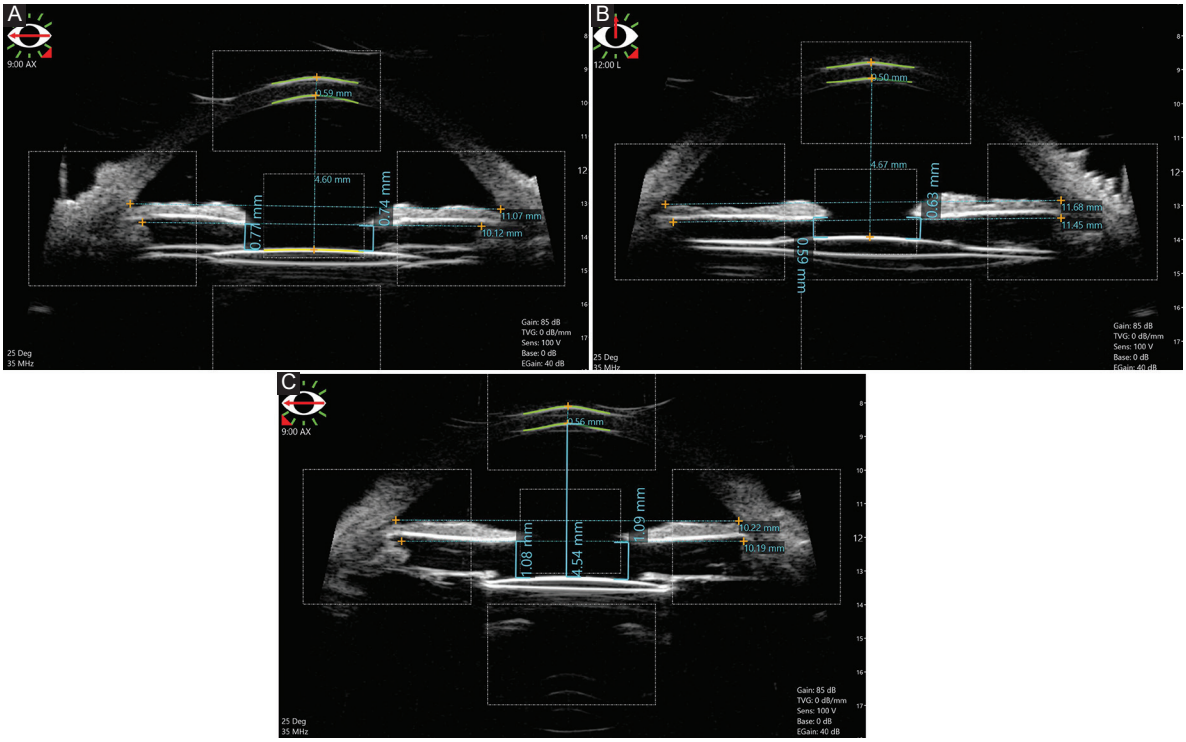


**Figure 4.** *Measurements taken through ultrasound biomicroscopy.* **A:** *MA60MA.* **B:** *ASPHINA.* **C:** *enVista.*

**Table 3. Spherical equivalent**

| | 1 month | 3 months | p |
|---|---|---|---|
| enVista | –0.33 ± 1.01 | –0.57 ± 0.88 | 0.152* |
| ASPHINA | –1.48 ± 1.24 | –1.30 ± 1.02 | 0.202* |
| MA60MA | –1.33 ± 1.13 | –1.47 ± 1.17 | 0.709* |

*Student t test.

chamber depth did not change in eyes with 1-piece IOLs compared to 3-piece IOLs, showing a shallow anterior chamber in the early postoperative period. These results suggest that the axial movement of the 1-piece IOL in the capsular bag is less pronounced than that of the 3-piece IOL. Consequently, they saw that the spherical equivalent in eyes with 1-piece IOLs did not change after surgery, while eyes with 3-piece IOLs showed myopic shifts of nearly 0.4 D. Therefore, they concluded that the postoperative refractive status was more stable with the 1-piece acrylic IOL than with the 3-piece one.

Contrary to these findings, our study demonstrated that the spherical equivalent and the stability of the IOL remained unchanged over time after phacoemulsification being the tilt similar with the 3 different types of IOLs studied, with no significant differences being reported in the spherical equivalent (p = 0.38). New IOLs tend to have better tolerance to tilt and decentration, resulting in minimal impact on the postoperative visual acuity.

## Conclusions

We can conclude that the 3 types of IOLs that exist provide refractive stability to myopic patients. The location and size of the corneal incision reduce postoperative corneal aberrations significantly. However, there are several limitations in our study, the main ones being its retrospective nature and the relatively small sample size, although it is comparable to other studies of IOLs with UBM.

## Acknowledgemets

The authors would like to express their gratitude to Fundación Hospital Nuestra Señora de la Luz I.A.P. Hospital Foundation for their valuable support.

## Funding

None whatsoever.

## Conflicts of interest

None reported.

## Ethical disclosures

**Protection of human subjects and animals in research.** The authors declare that no experiments were performed on humans or animals for this study.

**Patients' data protection.** The authors declare that they have followed the protocols of their work center on the publication of patient data.

**Right to privacy and informed consent.** The authors declare that no patient data appear in this article.

## References

1. Pan CW, Boey PY, Cheng CY, Saw SM, Tay WT, Wang JJ, et al. Myopia, axial length, and age-related cataract: The Singapore Malay Eye Study. Investig Ophthalmol Vis Sci. 2013;54:4498-502.
2. Petternel V, Menapace R, Findl O, Kiss B, Wirtitsch M, Rainer G, et al. Effect of optic edge design and haptic angulation on postoperative intraocular lens position change. J Cataract Refract Surg. 2004;30: 52-7.
3. Ang GS, Duncan L, Atta HR. Ultrasound biomicroscopic study of the stability of intraocular lens implants after phacoemulsification cataract surgery. Acta Ophthalmol. 2012;90:168-72.
4. Pereira FAS, Cronemberger S. Ultrasound biomicroscopic study of anterior segment changes after phacoemulsification and foldable intraocular lens implantation. Ophthalmology. 2003;110:1799-806.
5. Tafti M, Beiki H, Mohammadi S, Latifi G, Ashrafi E, Tafti Z. Anterior chamber depth change following cataract surgery in pseudoexfoliation syndrome: a preliminary study. J Ophthalmic Vis Res. 2017;12: 165-9.
6. Sugar A, Sadri E, Dawson DG, Musch DC. Refractive stabilization after temporal phacoemulsification with foldable acrylic intraocular lens implantation. J Cataract Refract Surg. 2001;27:1741-5.
7. Tello C, Liebmann J, Potash SD, Cohen H, Ritch R. Measurement of ultrasound biomicroscopy images: intraobserver and interobserver reliability. Investig Ophthalmol Vis Sci. 1994;35:3549-52.
8. Iwase T, Tanaka N, Sugiyama K. Postoperative refraction changes in phacoemulsification cataract surgery with implantation of different types of intraocular lens. Eur J Ophthalmol. 2008;18:371-6.
9. Findl O, Drexler W, Menapace R, Bobr B, Bittermann S, Vass C, et al. Accurate determination of effective lens position and lens-capsule distance with 4 intraocular lenses. J Cataract Refract Surg. 1998;24: 1094-8.
10. Hayashi K, Hayashi H. Comparison of the stability of 1-piece and 3-piece acrylic intraocular lenses in the lens capsule. J Cataract Refract Surg. 2005;31:337-42.