Check for updates

ORIGINAL ARTICLE

Synbiotics administration leads to attenuated mucosal inflammatory neutrophil infiltration and increased hematocrit in experimental ulcerative colitis

La administración de simbióticos conduce a la infiltración atenuada de neutrófilos inflamatorios de la mucosa y al aumento del hematocrito en la colitis ulcerosa experimental

Ioannis Varnalidis[1], Orestis Ioannidis[1], Athina Papadopoulou[1], Theophilos Poutahidis[2], Ioannis Taitzoglou[3], Zafeiris Ampas[4], Christos Chatzakis[1], Konstantinos Galanos-Demiris[1], Ioannis Mantzoros[1], Manousos George Pramateftakis[1], Efstathios Kotidis[1], Stamatis Angelopoulos[1], Dimitrios Botsios[1], and Konstantinos Tsalis[1]*

[1]Medical School, Aristotle University of Thessaloniki, Thessaloniki; [2]Laboratory of Pathology, Faculty of Veterinary Medicine, Aristotle University of Thessaloniki, Thessaloniki; [3]Laboratory of Physiology, Faculty of Veterinary Medicine, Aristotle University of Thessaloniki, Thessaloniki; [4]Department of Rural Development, Democritus University of Thrace, Orestadia. Greece

ABSTRACT

Objective: *The objective of the study was to estimate the effects of synbiotics on laboratory, macroscopic, and histopathologic features in dextran sulfate sodium (DSS) experimental colitis.* **Materials and methods:** *A total of 40 Wistar rats received 5% of DSS in their drinking water for 8 days to induce ulcerative colitis (UC). Eight rats were sacrificed to confirm the presence of UC. The remaining rats were randomly assigned to two groups: the synbiotics group, which received synbiotics once per day and the control group, which received tap water for another 8 days.* **Results:** *On the 8th day of DSS administration animals developed UC with bloody diarrhea. In the majority of the hematologic variables studied (hemoglobin [HB], red blood cells, platelets, mean corpuscular volume, and mean corpuscular HB), in bodyweight and histopathologic colitis score there was no significant difference between groups. However, the synbiotics group, compared to control, presented a significantly greater colon length on the 4th day, significantly increased hematocrit (HT) on the 8th day, and a significantly decreased number of myeloperoxidase positive cells on the 8th day. Furthermore, there was a trend toward histopathological and clinical improvement.* **Conclusions:** *Administration of synbiotics in the experimental UC results in an attenuation of mucosal inflammatory neutrophil infiltration and an increase in HT.*

Keywords: *Dextran sulfate sodium. Inflammatory bowel disease. Myeloperoxidase. Prebiotics. Probiotics.*

Resumen

Objetivo: *Estimar los efectos de los simbióticos en la colitis experimental causada por dextrano sulfato de sodio (DSS).* **Material y métodos:** *Cuarenta ratas Wistar recibieron DSS al 5% en su agua de beber por 8 días para inducir colitis ulcerosa (CU). Ocho ratas fueron sacrificadas para confirmar la presencia de CU. Las ratas restantes fueron asignadas*

Correspondence:
*Orestis Ioannidis
Alexandrou Mihailidi, 13
C.P. 54640, Thessaloniki, Greece
E-mail: iorestis@auth.gr

Date of reception: 10-02-2020
Date of acceptance: 01-04-2020
DOI: 10.24875/CIRUE.M20000201

Cir Cir (Eng). 2020;88(4):401-410
Contents available at PubMed
www.cirugiaycirujanos.com

2444-0507/© 2020 Academia Mexicana de Cirugía. Published by Permanyer. This is an open access article under the CC BY-NC-ND license (http://creativecommons.org/licenses/by-nc-nd/4.0/).

aleatoriamente a dos grupos: un grupo que recibió simbióticos una vez al día y un grupo control que recibió agua del grifo por 8 días. **Resultados:** *En el octavo día de la administración de DSS los animales desarrollaron CU con diarrea sanguinolenta. En la mayoría de las variables hematológicas estudiadas (hemoglobina, glóbulos rojos, plaquetas, volumen corpuscular medio, hemoglobina corpuscular media), en el peso corporal y en la clasificación histopatológica de la CU no hubo diferencias significativas entre los grupos. Sin embargo, el grupo con simbióticos, en comparación con el grupo control, presentó una longitud del colon más larga en el cuarto día, un hematocrito muy aumentado en el octavo día y un número de células mieloperoxidasa positivas significativamente reducido en el octavo día. Además, hubo una tendencia hacia un mejoramiento histopatológico y clínico.* **Conclusiones:** *La administración de simbióticos en la CU experimental tiene como resultado una atenuación de la infiltración inflamatoria de neutrófilos de la mucosa y un aumento del hematocrito.*

Palabras clave: *Sulfato de dextrano sódico. Enfermedad inflamatoria intestinal. Mieloperoxidasa. Prebióticos. Probióticos.*

Introduction

The gastrointestinal tract is an important immune organ of the human body and is colonized by a huge population of microorganisms, both nonpathogenic (probiotics) and pathogenic, consisting of 400-500 different species at about 10^{11} cfu per gram of intestinal tissue[1,2]. Intestinal microflora is defined as the population of live microorganisms in the gastrointestinal tract, which acts as a separate ecosystem and affects patients' health and longevity[3,4].

The balance of the intestinal flora can be adjusted with pharmacological or dietary factors, such as the administration of probiotics and prebiotics. Probiotics, as living organisms, when taken in adequate quantities can especially affect the intestine microflora, reduce bacterial translocation and contribute to the restoration of the intestinal epithelial barrier and the maintenance of the functional integrity of the intestinal mucosa[3-8]. Prebiotics are non-degradable food ingredients that have a beneficial effect on the host by eclectically stimulating the proliferation and/or the activity of one single bacteria or a group of bacteria of the large intestine[9]. They contribute to the diversity of the intestinal microflora, increasing the number of protective intestinal bacteria and the production of short chain fatty acids in the colon and decreasing the production of cytokines that promote inflammation[6-8]. Synbiotics, which are defined as the combination of probiotics and prebiotics, seem to protect against inflammation[10].

Ulcerative colitis (UC) is a chronic disease of the gastrointestinal tract, especially the colon that follows an unpredictable course characterized by multiple episodes of flairs and remissions. Several factors, such as genetic, environmental and bacterial, seem to be involved in the pathogenesis of UC[11,12]. Many experimental models have been used to study the pathophysiology and therapy of this inflammatory bowel disease[13]. In rodents, the supplementation of drinking water with dextran sulfate sodium (DSS) can induce an experimental model of UC[12-14]. Per os administration of 5% DSS in the drinking water of BALB/c mice caused acute and chronic colitis with several histopathological similarities to UC[15]; thus, a replicable model of UC in Swiss Webster rats has been developed[16,17]. Furthermore, the clinical, structural, and pathological findings of the experimental colitis with DSS in Wistar and Sprague-Dawley rats are well described[18]. The aim of the current study was to estimate the effects of synbiotics on the clinical, laboratory, macroscopic, and histopathologic features in the Wistar rat model of DSS-induced experimental colitis.

Materials and methods

Animals

A protocol was designed to minimize discomfort and pain in the animals. For the current experimental study, 40 male pathogen-free Wistar rats, 2.5 months old and weighing 250-300 g, were used. All animals during the study were housed in cages of one to four positions, depending on the experiment period, under normal laboratory conditions with temperature between 18°C and 22°C, relative humidity between 55 and 65% and a land-controlled light cycle of 12 h light and 12 h dark. The animals had free access to water and food (*ad libitum*), which was special for rats. The genetic standardization of animal models was a randomized series of the experimental animals and the microbial standardization was normal (conventional) experimental animals. The experiments took place at the physiology laboratory of the Veterinary School of

Aristotle University of Thessaloniki after authorization and approval by the Veterinary Service of Thessaloniki (Number of experimentation approval 13/1144/24-1-08), in accordance with the requirements of the EU Directive 86/609/EEC about protecting animals that are used for experimental or other scientific purposes.

Induction of UC with DSS 5%

Rats received 5% dextran sodium sulfate-DSS (molecular weight: 36 kDa ± 50 kDa; MP Biomedicals Inc., Cleveland, OH, USA) in their drinking water for 8 days until the presence of loose stools, diarrhea, and macroscopic rectal bleeding. After 8 days, DSS was stopped, and eight rats were sacrificed to confirm the presence of the experimental UC.

Groups

Rats were randomly divided into three groups: DSS, CONTROL, and SYNBIOTICS.

DSS group (n = 8): after 8 days of DSS administration, the rats were sacrificed to confirm the presence of experimental UC and study the histopathologic features of the colon. The colonic tissue was examined macroscopically and microscopically to determine the presence of experimental UC and establish baseline measurements to compare the experimental findings.

CONTROL group (n = 16): after the DSS administration had been stopped, these rats received tap water and no other medication. Subgroup CONTROL 4 (n = 8): rats were sacrificed on the 4th day post-DSS. Subgroup CONTROL8 (n = 8): rats were sacrificed on the 8th day post-DSS.

SYNBIOTICS group (n = 16): after the DSS administration had been stopped, these rats received a synbiotic compound (Ecologic® 825-Winclove Bio Industries Amsterdam, The Netherlands) once per day through an orogastric catheter. The synbiotic regimen used was a mixture of probiotics and prebiotics in the form of powder. The active ingredients were: prebiotics, including Cornstarch, maltodextrin, fructo-oligosaccharides, inulin, minerals (potassium chloride, magnesium sulfate, and manganese sulfate), enzymes (amylases; and contained soy), and vanilla; and nine probiotic strains (contained soy and milk components), including *Bifidobacterium bifidum* (W23), *Bifidobacterium lactis* (W51), *B. lactis* (W52), *Lactobacillus acidophilus* (W22), *Lactobacillus casei* (W56), *Lactobacillus paracasei* (W20), *Lactobacillus plantarum* (W62), *Lactobacillus salivarius* (W24), and *Lactobacillus lactis* (W19) with 2.5×10^9 colony-forming units (CFU) per gram. The administrated dose of probiotics was 2×10^8 CFU per rat per day. Subgroup SYNBIOTICS 4 (n = 8): rats were sacrificed on the 4th day post-DSS. Subgroup SYNBIOTICS 8 (n = 8): rats were sacrificed on the 8th day post-DSS.

Euthanasia

Euthanasia was carried out by cardiac puncture and exsanguination, which was performed under deep anesthesia with the intraperitoneal administration of chloral hydrate (400 mg/kg body weight).

Sample recovery

Median laparotomy was performed after shaving the abdomen and using 10% Povidone-iodine solution for skin antisepsis. Under aseptic conditions, a 4-cm midline ventral abdominal incision was made from the height of the xiphoid, allowing entry into the peritoneal cavity, and exposure of the large intestine. The large intestine was mobilized from the ileocecal valve to the anal canal and excised. The distal colon was first opened along the anti-mesenteric border and washed with saline, then was weighed, measured, and photographed and the macroscopic intestinal mucosal lesions were recorded.

Next, the entire large intestine was fixed in neutral formalin for histopathological examination. Furthermore, in every rat, a cardiac puncture was performed to retrieve sufficient amounts of blood for the laboratory examinations. The blood samples were placed in veterinary vials IDEXX VetCollect 1.0 ml with anticoagulant K3 EDTA. A sterile syringe with a needle of 26G diameter was used to obtain 5 ml of blood from each rat.

Body weight and laboratory assessment of colonic inflammation

Body weights were recorded daily. Hemoglobin (HB) concentration, hematocrit (HT), total erythrocyte numbers (red blood cell [RBC]), mean corpuscular volume (MCV), mean corpuscular HB (MCH), and platelets (PLT) count were determined. The blood tests were performed by the veterinary analyzer Scil Vet abc (Animal Blood Counter) with a special program for rats.

Histology, immunohistochemistry, and morphometry

Tissues were fixed in 10% neutral formalin solution and embedded in paraffin. Histopathology sections were cut at a thickness of 4-6 µm and stained with hematoxylin and eosin (HE). Immunohistochemical staining was used for myeloperoxidase (MPO). 5-µm thick formalin-fixed, paraffin-embedded tissue sections were used. The primary antibodies used for MPO immunohistochemistry included rabbit anti-MPO (MPO Ab-1; Thermo Fischer Scientific Lab Vision, Fremont, CA, USA). Heat-induced antigen retrieval was performed with citrate buffer, pH 6, for MPO. Primary antibody binding was detected with goat anti-rabbit IgG polymerized horseradish peroxidase (Chemicon International, Temecula, CA, USA). The signal was detected with diaminobenzidine and tissues were counterstained with hematoxylin[12].

Colitis was graded on a scale of 0-4 with ascending severity (Grade 0: no lesions; Grade 1: minimal lesions; Grade 2: mild lesions; Grade 3: moderate lesions; and Grade 4: severe lesions), which was first used by Berg et al.[19], but was modified later[20].

Neutrophil infiltration was quantified using morphometry by assessment of MPO-stained slides of colon tissue sections. In short, using a technique described elsewhere[12,21], multiple representative high-power fields were captured with a Nikon DS-5M-L1 digital camera (Nikon, Tokyo, Japan) (× 40). Ten images per treatment group were randomly selected. Then, the identified neutrophils in each image were counted using the cell count plug-in of the ImageJ image processing and analysis program (NIH, Bethesda, MD, USA).

Statistical analysis

All data were reported as mean ± standard deviation. Statistical analysis for colon length and blood tests, which presented normal distributions, was performed using deviation analysis (Analysis of variance [ANOVA]) and the comparison of means was made using the Bonferroni correction for *post hoc* pairwise comparisons. Body weights were analyzed with repeated measures ANOVA. Colitis score and MPO, which did not have normal distribution, were analyzed using the non-parametric Kruskal-Wallis test. Statistical analysis was performed using DOE Prisma© Software (GraphPad Software Inc., San Diego CA, USA). $p < 0.05$ was considered statistically significant.

Results

Colitis presentation

On the 8th day of DSS treatment, all animals developed severe colitis with diarrhea and hematochezia.

Body weight

After the first 8 days of DSS administration, body weights decreased in both groups, but the differences were not significant. After 8 days of treatment, the body weight increased in all groups, but the differences were not statistically significant. Figure 1A depicts the results.

Distal colon length

The mean colon length differed between the groups ($p < 0.0001$). The mean colon length increased in both the CONTROL and SYNBIOTICS groups, both in the 4th and 8th post-DSS days compared to the DSS group. The increase was not statistically significant for the control group compared to the DSS on the 4th day, but was significant on the 8th day ($p = 0.0301$), while the increase was significant for the SYNBIOTICS group in both the 4th and 8th days post-DSS ($p = 0.0192$ and $p = 0.004$, respectively). The mean colon length in the SYNBIOTICS group was significantly higher than the CONTROL group on the 4th day ($p = 0.0241$), but not on the 8th day post-DSS. The increase of the colon length from the 4th to the 8th post-DSS day was statistically significant for the CONTROL group ($p = 0.0375$), but not for the SYNBIOTICS group. Figure 1B depicts the results.

Hematological variables

The disease severity and the number of hemorrhagic bowel movements affected the values of HB, HT, erythrocytes, MCV, MCH, and PLT. The hematological variables, except for erythrocytes (RBCs) ($p = 0.96$) and PLTs ($p = 0.40$), differed significantly between the groups. Specifically, statistically significant differences were found for HB ($p < 0.001$), HT ($p < 0.001$), MCV ($p = 0.0016$), and MCH ($p = 0.004$). While HB and HT increased on the 4th day post-DSS in both groups compared to the DSS group, the increase was significant only on the 8th day post-DSS in both the CONTROL ($p = 0.0001$ and $p = 0.0011$) and SYNBIOTICS groups ($p < 0.001$ and $p < 0.001$), respectively. Furthremore,

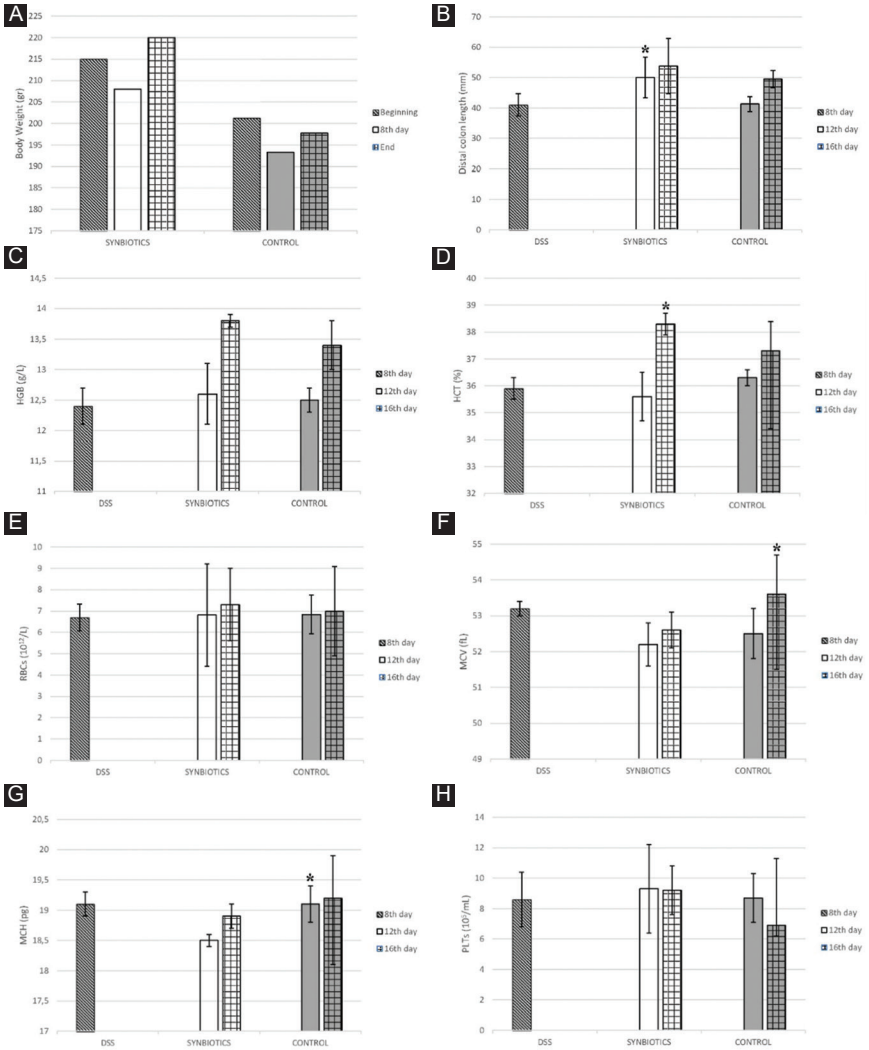

Figure 1. A: *body weight comparison at the beginning, middle and end of the experiment (mean). No statistically significant difference was noted.* **B:** *distal colon length comparison in the three groups. Statistically significant difference between the SYNBIOTICS 4 and CONTROL 4 groups.* **C:** *hemoglobin comparison of the three groups. No statistically significant difference was noted.* **D:** *hematocrit comparison in the three groups. Statistically significant difference between the SYNBIOTICS 8 and CONTROL 8 groups.* **E:** *red blood cell count comparison in the three groups. No statistical significant difference was noted.* **F:** *mean corpuscular volume comparison in the three groups. Statistically significant difference between the SYNBIOTICS 8 and CONTROL 8 groups.* **G:** *mean corpuscular hemoglobin comparison in the three groups. Statistically significant difference between the SYNBIOTICS 4 and CONTROL 4 groups.* **H:** *platelet comparison in the three groups. No statistically significant difference was noted.*

the increases in HB and HT were significant from the 4th to the 8th day post-DSS, both in the CONTROL group ($p = 0.0003$ and $p = 0.0318$) and SYNBIOTICS group ($p < 0.0001$ and $p < 0.0001$). Furthermore, the HT was significantly higher in the SYNBIOTICS group on the 8th post-DSS day compared to the CONTROL group ($p = 0.0318$). Regarding MCV and MCH, there were also statistically significant differences between the groups ($p = 0.0016$ and $p = 0.0040$, respectively). Specifically, both MCV and MCH decreased significantly in the SYNBIOTICS 4 group compared to DSS ($p = 0.0453$ and $p = 0.0188$, respectively). Moreover, MCV increased on the 8th day post-DSS in the CONTROL group compared to the 4th day ($p = 0.0224$) and compared to the SYNBIOTICS group on the 8th day ($p = 0.0453$), while MCH increased in the CONTROL group on the 4th post-DSS day compared to the SYNBIOTICS group. Figure 1C-H depicts these results.

Macroscopic and histopathological findings

After the administration of DSS for 8 days, experimental severe colitis was histopathologically confirmed.

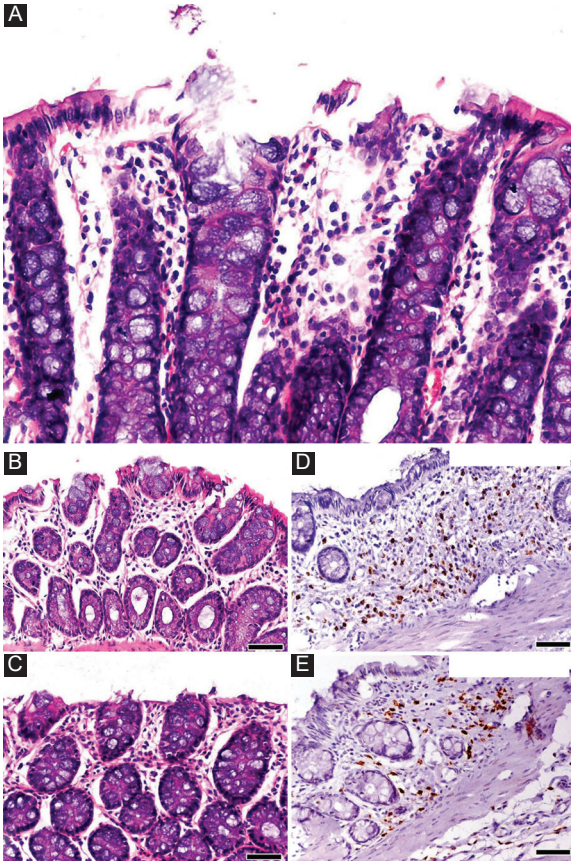

Figure 2. A: *intestinal mucosa of the descending colon after 8 days of dextran sulfate sodium (DSS) administration. Erosion of the epithelium and mild increase of the inflammatory cells were observed.* **B and C:** *after 8 days of treatment, there was no difference in the histopathological findings between the CONTROL group and the SYNBIOTICS group.* **D and E:** *however, regarding the number of myeloperoxidase + cells (neutrophils), there was a significant decrease in the SYNBIOTICS group compared to the CONTROL.*

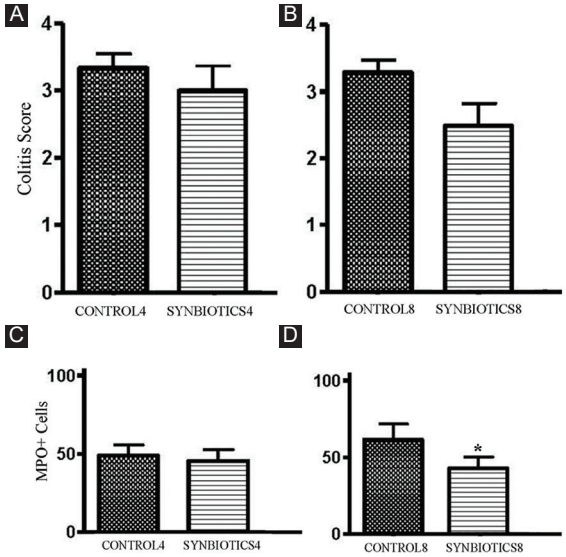

Figure 3. A: *colitis score comparison between the SYNBIOTICS and CONTROL groups on the 4th day post-dextran sulfate sodium (DSS).* **B:** *colitis score comparison between the SYNBIOTICS and CONTROL groups on the 8th day post-DSS.* **C:** *myeloperoxidase (MPO) + cells comparison between the SYNBIOTICS and CONTROL groups on the 4th day post-DSS.* **D:** *MPO + cells comparison between the SYNBIOTICS and CONTROL groups on the 8th day post-DSS. Statistically significant difference between the SYNBIOTICS 8 and CONTROL 8 g.*

Specifically, in the descending colon and in the rectum, multifocal, and diffuse erosions of the intestinal mucosa and enlargement of the lumen of the glands with simultaneous aggregation of a large number of inflammatory cells (mainly neutrophils, lymphocytes, plasma cells and macrophages and, secondarily, eosinophils) were observed (Fig. 2A). Focally and at a more advanced stage, colitis was characterized by a loss of glands, the development of connective tissue and reduction of the mucosa thickness. Furthermore, dysplasia of the glands was noted, with the dysplastic glands being characterized by a helical shape and significant enlargement of their lumen. Dysplastic epithelium displayed a loss of goblet cells, loss of cell nucleus polarity, and cell pleomorphism.

While synbiotics administration slightly decreased the colitis score and led to mild improvement of intestinal mucosal erosions compared to the CONTROL group on both the 4th and 8th post-DSS days, these differences were not significant (Fig. 2B and C). Figure 3A and B depicts these results.

MPO activity

MPO-specific immunohistochemical staining analysis revealed a reduction of MPO positive cells (mainly neutrophils) in the SYNBIOTICS group compared to the control group, but was statistically significant only on the 8th day post-DSS ($p < 0.001$) (Fig. 2D and E). Figure 3C and D depicts these results.

Discussion

The development of UC is attributed to the activation of an immune response in a subset of non-pathogenic colonic bacteria in genetically-predisposed individuals. Clinical and experimental studies have shown that the relative balance between pathogenic and protective bacteria of the intestinal microflora changes in UC[22]. The main pharmaceutical therapy for UC includes the use of anti-inflammatories, immunosuppressants, and antibiotics. Dietary and nutritional factors are required in all types of inflammatory

bowel disease, but this is often overlooked. The role of nutrition is not only significant because it achieves maintenance of the disease in remission but also because it helps in the reduction of its activity. The intestinal microflora is in a synbiotic relationship with eukaryotic mucosal cells and includes approximately 10^{14} bacteria comprising more than 400 different species[23,24]. The necessity of dietary factors in relation to the pathogenesis and therapy of UC has been highlighted in recent years. Nutritional factors can modulate the intestinal immune response, improve the function of the intestinal mucosal barrier, and modify the intestinal flora. Synbiotics (probiotics and prebiotics) present beneficial effects by improving the balance of the gut microbial flora. The use of prebiotics contributes to the increase of intestinal mucous, the maintenance of its functional integrity, the balance of body water and electrolytes, the supply of the body with energy and dietary factors, the increase of resistance to pathogenic microorganisms, the adjustment of the intestinal mucous immune response, and the stimulation of the humoral immune response. Furthermore, prebiotics seem to play a significant role in the maintenance of the intestinal flora or the restoration of the disturbed equilibrium of the intestinal flora. This is achieved by the enhancement of intestinal barrier function, which results in the inhibition of bacterial translocation[25,26]. The most known prebiotics are inulin and oligofructose, carbohydrates that are natural ingredients found in plants[7,27]. Probiotics play a main role in the formulation of the large intestine's natural ecosystem. The most known and widely used probiotic microorganisms belong to the genus *Lactobacillus* and *Bifidobacterium*[28-30]. Probiotics contribute to the maintenance of anatomical and functional integrity of the intestinal mucosa. The administration of probiotics contributes to the improvement and increase of the intestinal epithelial barrier by suspending the epithelial cell apoptosis. Probiotics inhibit the relocation of pathogenic microorganisms, such as *Escherichia coli*, and exclude pathogenic microorganisms by occupying the available natural space for intestine colonization. Furthermore, they excrete antimicrobial substances that destroy pathogenic microorganisms before they can colonize the intestine[23].

The structural changes of the intestinal mucous caused by the administration of DSS allow lumen antigens to penetrate, resulting in increased neutrophil infiltration and an increase of MPO in the intestinal mucous, which triggers an inflammatory reaction. Furthermore, DSS promotes the production of chemokines from the epithelial cells of the intestinal mucous, resulting in a higher concentration of neutrophils. Histopathologically, the experimental models share almost all the morphological characteristics and a similar allocation of lesions with the UC affecting humans. Per os DSS administration lead to the development in all animals of severe colitis with diarrhea and hematochezia and characteristic histopathological findings, as we have already described elsewhere[12,14].

In the current study, with regard to the hematological variables, synbiotics administration lead to significantly increased HT on the 8th post-DSS day compared to control. Many studies have focused on the efficiency of probiotics administration for colitis and included them in UC treatment[31-37]. Recent clinical studies have found that probiotics can play a significant role in the treatment of UC. In one of these, Venturi et al.[38] studied the actions of a probiotic regimen from several species (three chains bifidobacteria, four chains lactobacilli, and one chain of *Streptococcus salivarius* sp. Thermophilus) for 12 months in 20 patients with inactive UC and with intolerance to mesalazine. The results showed that 15 of 20 patients remained under remission. Venturi's study is considered unique in investigating probiotics' action in the stools' flora, noting an increase of bifidobacteria, lactobacilli, and *S. salivarius* without a change in other species. In another double blind study, the probiotic drug *E. coli* Nissle 1917 showed efficacy and safety in maintaining remission equivalent to the gold-standard mesalazine in patients with UC[39]. In another study, the VSL#3 probiotic administration to patients with mild-to-moderate UC that did not respond to conventional therapy resulted in a combined induction of remission/response rate of 77%, with no adverse events[40]. Furrie et al.[41] found similar results in a double-blind clinical study comparing synbiotics with a placebo. The administration of synbiotics to 18 patients caused a significant reduction of inflammatory cytokines (tumor necrosis factor [TNF]-a, and interleukin [IL]-1b) and the histopathological examination revealed a reduction of inflammatory cell infiltration.

Furthermore, synbiotics administration ameliorated epithelial erosion and resulted in a lower colitis injury score and reduction of the intestinal mucosal inflammation, although the differences were not statistically significant. However, increases in colon length were significant for the synbiotics administration compared to the control on the 4th day, but not the 8th. Many experimental studies have shown that the administration of prebiotics, probiotics, and synbiotics can be

effective for UC in many ways. Videla et al.[42] estimated the effectiveness of administering inulin, a prebiotic, for experimental colitis. Experimental colitis was caused by the administration of 5% DSS in rats. The administration of inulin improved the histopathological findings, reduced the release of inflammatory mediators, and reduced the concentration of MPO. In this case, the effect seemed to be mediated by the modification of the intracolonic milieu. Moreover, it has been shown that prior administration of probiotic bacteria reduces mucosal inflammation and damage in DSS-induced colitis. One particular study showed that DSS colitis was associated with significant changes in the fecal anaerobic bacterial flora and these changes were modulated by the administration of probiotic bacteria[43]. Likewise, it has been reported that the administration of synbiotic combinations improves DSS-induced acute colitis and has an anti-inflammatory effect, resulting in improvement in the full clinical appearance of chronic inflammation and the reduction of colonic IL-1a, MPO activity, TNFa, and IL-1a[42].

In our experimental study, the administration of synbiotics 8 days after the administration of DSS caused a statistically significant reduction of the quantity of MPO-positive cells (mainly neutrophils) compared to control. Osman et al.[44] observed that the daily administration of synbiotics (*Bifidobacterium infantis*, oligofructose, and inulin) reduced inflammatory reactions in the experimental DSS colitis in rats, specifically in the MPO activity of the intestinal mucosa of the large bowel, compared to control. Furthermore, there was a statistically significant reduction in bacterial relocation, both at the mesenteric lymph nodes and at the liver lobe in the group that received synbiotics. Fukuda et al.[45] compared the therapeutic results of the administration of prebiotics (glutamine-rich protein and hemicellulose-rich dietary fiber), probiotics (*Lactobacillus* and *Clostridium butyricum*), or antibiotics (vancomycin and metronidazole) in the experimental DSS-colitis in rats. They observed that treatment with the administration of prebiotics significantly reduced mucosal inflammation in contrast with the administration of probiotics or antibiotics. There is an indication that probiotics stimulate the expression of the MUC3 gene that produces mucin, a glycoprotein that is excreted from the epithelial cells in the gastrointestinal system. The expression of mucin increases the protection of the gastrointestinal tract from viruses and microbes[46]. Furthermore, at an experimental level, *L. plantarum* and *Lactobacillus rhamnosus* GG, and the synthetic probiotic mixture VSL#3, can increase the production of IL-10 and the species lactobacilli and bifidobacteria can reduce the production of TNF-a and Interferon (INF)-γ[29,47,48]. Furthermore, it has been demonstrated that probiotics, due to their protective immunomodulatory capacity, prevents the growth of spontaneous colitis in rats that present a deficiency of IL-10 and also reduce the excretion of the pro-inflammatory cytokines TNF-a and INF-γ from the intestinal mucosa[49,50]. The administration of the synthetic probiotic mixture VSL#3 (includes 4 *Lactobacillus* sp., 3 *Bifidobacterium* spp. and *S. salivarius* sub spp. *thermophilus*) seems to restore the function of the intestinal barrier in chronic experimental colitis[7].

Both prebiotics and probiotics have specific actions by which they act and ameliorate UC, and this action in case of synbiotics is enhanced, as synbiotics, as a combination of prebiotics and probiotics, are more effective against UC than prebiotics or probiotics alone. The exact mechanism of actions of synbiotic administration in UC is not yet fully elucidated but it is seems that the synergy between prebiotics and probiotics, rather than the specific action of its one, leads to a modulation of the inflammatory response reducing the production of pro-inflammatory cytokines, increasing the expression of anti-inflammatory cytokines, modulating the immune cell function, and stabilizing the intestinal mucosal barrier[51].

Conclusions

The administration of 5% DSS to Wistar rats produces variably severe symptoms and significant structural and ultrastructural alterations similar to human UC, including epithelial disruption, focal lesions, and superficial inflammation. Collectively, the results of our study suggest a beneficial role of synbiotics in the experimental DSS-induced UC, as animals fed a synbiotics-rich diet exhibited a significant increase in HT and colon length and a trend toward histopathological and clinical improvement, which were associated with a significant decrease in the MPO positive cells that are normally present in colitis and in neutrophil infiltration. Regarding the possible mechanisms of action, prebiotics contribute to the improvement of the epithelial intestinal barrier, to the maintenance of the functional integrity of the intestinal mucous, to the increase of resistance against pathogenic microorganisms, to the adjustment of the intestinal mucosa immune response, and to the stimulation of the humoral immune response. Probiotics initially eliminate pathogenic microorganisms by occupying the available physical

space for colonization in the intestine and secrete antimicrobial substances that destroy pathogenic microorganisms before they colonize the intestine. Moreover, given the fact that they do not induce significant side effects, synbiotics could be included in human UC treatment.

Conflicts of interest

The authors declare that they have no conflict of interest for this work.

Ethical disclosures

Protection of human and animal subjects. The authors declare that the procedures followed were in accordance with the regulations of the relevant clinical research ethics committee and with those of the Code of Ethics of the World Medical Association (Declaration of Helsinki).

Confidentiality of data. The authors declare that no patient data appear in this article.

Right to privacy and informed consent. The authors declare that no patient data appear in this article.

References

1. Anastasilakis CD, Ioannidis O, Gkiomisi AI, Botsios D. Artificial nutrition and intestinal mucosal barrier functionality. Digestion. 2013;88:193-208.
2. Berg RD. The indigenous gastrointestinal microflora. Trends Microbiol. 1996;4:430-5.
3. Collins MD, Gibson GR. Probiotics, prebiotics, and synbiotics: approaches for modulating the microbial ecology of the gut. Am J Clin Nutr. 1999;69:1052S-7.
4. Capurso L, Morelli L. Probiotics, prebiotics, and new foods. J Clin Gastroenterol. 2008;42 Suppl 3:S109-10.
5. Yen PK. Probiotics and prebiotics for bowel health. Geriatr Nurs. 2003;24:192-3.
6. Jeppsson B, Mangell P, Adawi D, Molin G. Bacterial translocation: impact of probiotics. Scand J Nutr. 2004;48:37-41.
7. Looijer-van Langen M, Prajapati V, Dieleman L. Probiotics and prebiotics as functional ingredients in inflammatory bowel disease. Nutr Today. 2008;43:235-42.
8. Ioannidis O, Varnalidis I, Paraskevas G, Botsios D. Nutritional modulation of the inflammatory bowel response. Digestion. 2011;84:89-101.
9. Schrezenmeir J, de Vrese M. Probiotics, prebiotics, and synbiotics-approaching a definition. Am J Clin Nutr. 2001;73 Suppl 2:361S-4.
10. Sapidis N, Tziouvaras C, Ioannidis O, Kalaitsidou I, Botsios D. The effect of glutamine and synbiotics on the healing of colonic anastomosis. Rev Esp Enferm Dig. 2014;106:255-62.
11. Ardizzone S, Porro GB. Inflammatory bowel disease: new insights into pathogenesis and treatment. J Intern Med. 2002;252:475-96.
12. Varnalidis I, Ioannidis O, Karamanavi E, Ampas Z, Poutahidis T, Taitzoglou I, et al. Omega 3 fatty acids supplementation has an ameliorative effect in experimental ulcerative colitis despite increased colonic neutrophil infiltration. Rev Esp Enferm Dig. 2011;103:511-8.
13. Onderdonk AB. Experimental models for ulcerative colitis. Dig Dis Sci 1985;30 Suppl 12:40S-4.
14. Varnalidis I, Ioannidis O, Tsorlini E, Botsios D. Experimental colitis induced by dextran sodium sulphate (DSS): an experimental study in rats. Surg Chron. 2010;15:208-14.
15. Okayasu I, Hatakeyama S, Yamada M, Ohkusa T, Inagaki Y, Nakaya R. A novel method in the induction of reliable experimental acute and chronic ulcerative colitis in mice. Gastroenterology. 1990;98:694-702.
16. Cooper HS, Murthy SN, Shah RS, Sedergran DJ. Clinicopathologic study of dextran sulfate sodium experimental murine colitis. Lab Invest. 1993;69:238-49.
17. Dieleman LA, Palmen MJ, Akol H, Bloemena E, Peña AS, Meuwissen SG, et al. Chronic experimental colitis induced by dextran sulphate sodium (DSS) is characterized by Th1 and Th2 cytokines. Clin Exp Immunol. 1998;114:385-91.
18. Gaudio E, Taddei G, Vetuschi A, Sferra R, Frieri G, Ricciardi G, et al. Dextran sulfate sodium (DSS) colitis in rats: clinical, structural, and ultrastructural aspects. Dig Dis Sci. 1999;44:1458-75.
19. Berg DJ, Davidson N, Kerg R, MDJ, DavidMenon S, Holland G, et al. Enterocolitis and colon cancer in interleukin-10-deficient mice are associated with aberrant cytokine production and CD4(+) TH1-like responses. J Clin Invest. 1996;98:1010-20.
20. Erdman SE, Poutahidis T, Tomczak M, Rogers AB, Cormier K, Plank B, et al. CD4+ CD25+ regulatory T lymphocytes inhibit microbially induced colon cancer in Rag2-deficient mice. Am J Pathol. 2003;162:691-702.
21. Erdman SE, Rao VP, Poutahidis T, Rogers AB, Taylor CL, Jackson EA, et al. Nitric oxide and TNF-alpha trigger colonic inflammation and carcinogenesis in *Helicobacter hepaticus*-infected, Rag2-deficient mice. Proc Natl Acad Sci U S A. 2009;106:1027-32.
22. Sartor RB. Therapeutic manipulation of the enteric microflora in inflammatory bowel diseases: antibiotics, probiotics, and prebiotics. Gastroenterology. 2004;126:1620-33.
23. Ewaschuk JB, Dieleman LA. Probiotics and prebiotics in chronic inflammatory bowel diseases. World J Gastroenterol. 2006;12:5941-50.
24. van Elburg RM, Fetter WP, Bunkers CM, Heymans HS. Intestinal permeability in relation to birth weight and gestational and postnatal age. Arch Dis Child Fetal Neonatal Ed. 2003;88:F52-5.
25. Madsen K, Cornish A, Soper P, McKaigney C, Jijon H, Yachimec C, et al. Probiotic *Bacteria* enhance murine and human intestinal epithelial barrier function. Gastroenterology. 2001;121:580-91.
26. Otte JM, Podolsky DK. Functional modulation of enterocytes by gram-positive and gram-negative microorganisms. Am J Physiol Gastrointest Liver Physiol. 2004;286:G613-26.
27. Saavedra JM, Tschernia A. Human studies with probiotics and prebiotics: clinical implications. Br J Nutr. 2002;87 Suppl 2:S241-6.
28. Reid G, Burton J. Use of *Lactobacillus* to prevent infection by pathogenic *Bacteria*. Microbes Infect. 2002;4:319-24.
29. Osman N, Adawi D, Molin G, Ahrne S, Berggren A, Jeppsson B. *Bifidobacterium* infantis strains with and without a combination of oligofructose and inulin (OFI) attenuate inflammation in DSS-induced colitis in rats. BMC Gastroenterol. 2006;6:31.
30. McCarthy J, Kelly P, Hurley G, Luo F, Chen K, et al. *Lactobacillus* and *Bifidobacterium* in irritable bowel syndrome: symptom responses and relationship to cytokine profiles. Gastroenterology. 2005;128:541-51.
31. Shanahan F. Probiotics in inflammatory bowel disease--therapeutic rationale and role. Adv Drug Deliv Rev. 2004;56:809-18.
32. Chermesh I, Eliakim R. Probiotics--scope and promise in inflammatory bowel disease. Isr Med Assoc J. 2002;4:353-6.
33. Jonkers D, StockbrckbrS R. Probiotics and inflammatory bowel disease. J R Soc Med. 2003;96:167-71.
34. Morris JD, Diamond KA, Balart LA. Do probiotics have a role in the management of inflammatory bowel disease? J La State Med Soc. 2009;161:155-9.
35. Pagnini C, Cominelli F. Probiotics in experimental and human inflammatory bowel disease: discussion points. Dig Liver Dis. 2006;38 Suppl 2:S270-3.
36. Guarner F, Malagelada JR. Role of bacteria in experimental colitis. Best Pract Res Clin Gastroenterol. 2003;17:793-804.
37. Sheil B, Shanahan F, OB, Shan L. Probiotic effects on inflammatory bowel disease. J Nutr. 2007;137 Suppl 2:819S-24.
38. Venturi A, Gionchetti P, Rizzello F, Johansson R, Zucconi E, Brigidi P, et al. Impact on the composition of the faecal flora by a new probiotic preparation: preliminary data on maintenance treatment of patients with ulcerative colitis. Aliment Pharmacol Ther. 1999;13:1103-8.
39. Kruis W, Fric P, Pokrotnieks J, Luk L M, Fixa B, KascKa M, et al. Maintaining remission of ulcerative colitis with the probiotic *Escherichia coli* Nissle 1917 is as effective as with standard mesalazine. Gut. 2004;53:1617-23.
40. Bibiloni R, Fedorak RN, Tannock GW, Madsen KL, Gionchetti P, Campieri M, et al. VSL#3 probiotic-mixture induces remission in patients with active ulcerative colitis. Am J Gastroenterol. 2005;100:1539-46.
41. Videla S, Vilaseca J, AntoInt M, GarcGarclJ, Ant A, Guarner F, Crespo E, et al. Dietary inulin improves distal colitis induced by dextran sodium sulfate in the rat. Am J Gastroenterol. 2001;96:1486-93.
42. Kumar NS, Balamurugan R, Jayakanthan K, Pulimood A, Pugazhendhi S, Ramakrishna BS. Probiotic administration alters the gut flora and attenuates colitis in mice administered dextran sodium sulfate. J Gastroenterol Hepatol. 2008;23:1834-9.
43. Okano H, Shiraki K, Inoue H, Kawakita T, Yamamoto N, Deguchi M, et al. Clinicopathological analysis of liver abscess in Japan. Int J Mol Med. 2002;10:627-30.

44. Igarashi A, Yamaguchi M. Characterization of the increase in bone 66 kDa protein component with healing rat fractures: stimulatory effect of zinc. Int J Mol Med. 2002;9:503-8.
45. Fukuda M, Kanauchi O, Araki Y, Andoh A, Mitsuyama K, Takagi K, et al. Prebiotic treatment of experimental colitis with germinated barley foodstuff: a comparison with probiotic or antibiotic treatment. Int J Mol Med. 2002;9:65-70.
46. Mack DR, Michail S, Wei S, McDougall L, Hollingsworth MA. Probiotics inhibit enteropathogenic *E. coli* adherence *in vitro* by inducing intestinal mucin gene expression. Am J Physiol. 1999;276:G941-50.
47. Dieleman LA, Goerres MS, Arends A, Sprengers D, Torrice C, Hoentjen F, et al. *Lactobacillus* GG prevents recurrence of colitis in HLA-B27 transgenic rats after antibiotic treatment. Gut 2003;52:370-6.
48. Ulisse S, Gionchetti P, DP, D S, Russo FP, Pesce I, Ricci G, et al. Expression of cytokines, inducible nitric oxide synthase, and matrix metalloproteinases in pouchitis: effects of probiotic treatment. Am J Gastroenterol. 2001;96:2691-9.
49. Haller D, Bode C, Hammes WP, Pfeifer AM, Schiffrin EJ, Blum S. Non-pathogenic *Bacteria* elicit a differential cytokine response by intestinal epithelial cell/leucocyte co-cultures. Gut. 2000;47:79-87.
50. Madsen KL, Doyle JS, Jewell LD, Tavernini MM, Fedorak RN. *Lactobacillus* species prevents colitis in interleukin 10 gene-deficient mice. Gastroenterology. 1999;116:1107-14.
51. Roselli M, Finamore A. Use of synbiotics for ulcerative colitis treatment. Curr Clin Pharmacol. 2019. doi:10.2174/1574884715666191226120322.