Check for updates

ORIGINAL ARTICLE

Surgical interventıons to save autogenic dialysis access in aneurysmal arteriovenous fistulas

Intervenciones quirúrgicas para salvar el acceso autogénico de diálisis en las fístulas arteriovenosas aneurismáticas

Metin O. Beyaz[1], Sefer Kaya[1], Senem Urfalı[2], Ibrahim Demir[3], Faruk Turgut[1], and Iyad Fansa[1]*

[1]Department of Cardiovascular Surgery, Tayfur Ata Sökmen Faculty of Medicine, Hatay Mustafa Kemal University, Hatay; [2]Department of Anesthesia and Reanimation, Tayfur Ata Sökmen Faculty of Medicine, Hatay Mustafa Kemal University, Hatay; [3]Department of Cardiovascular Surgery, Kirsehir Education and Research Hospital, Kirsehir. Turkey

Abstract

Objective: *The aim is to share our surgical approaches for the removal of aneurysmatic dilatation by preserving the vascular access pathway in aneurysmatic arteriovenous fistulas (AVF).* **Methods:** *This study includes patients were admitted between September 2017 and May 2022 and were found to have true aneurysms in their upper extremity AVF. Patients were treated with partial aneurysmectomy combined with aneurysmorrhaphy or autologous vein graft interposition after total aneurysmectomy.* **Results:** *Six patients who underwent aneurysmoraphy after partial aneurysmectomy were named Group I. The mean age of the patients was 49, and the aneurysm diameter was 4.1 cm. 14 patients who underwent autologous vein interposition after aneurysmectomy were named Group II. The mean age of the patients was 58, and the aneurysm diameter was 4.4 cm. 13 patients met the need for hemodialysis with new AVF within 31 days (± 4-11 days). Due to the detection of insufficient post-operative flow in 1 patient (flow rate 180-200 mL/min) was taken to dialysis with alternative accesses.* **Conclusion:** *In AVF aneurysms, it is possible to save the vascular access path with surgical treatments applied under elective conditions.*

Keywords: *Arteriovenous fistulas. Aneurysm. Aneurysmectomy. Aneurysmorrhaphy. Graft vein interposition.*

Resumen

Objetivo: *Compartir nuestros abordajes quirúrgicos para la remoción de dilataciones aneurismáticas en fístulas arteriovenosas, preservando la vía de acceso vascular.* **Métodos:** *El estudio incluyó pacientes ingresados entre septiembre de 2017 y mayo de 2022, con aneurismas verdaderos en fístulas arteriovenosas de las extremidades superiores. Los pacientes fueron tratados mediante aneurismectomía parcial combinada con aneurismorrafia o interposición de injerto venoso autólogo después de la aneurismectomía total.* **Resultados:** *Se dividió a los pacientes en dos grupos. El grupo I consistió en 6 pacientes a quienes se realizó aneurismorrafia después de aneurismectomía parcial; la edad promedio fue de 49 años y el diámetro del aneurisma fue de 4.1 cm. El grupo II incluyó 14 pacientes que se sometieron a interposición de injerto venoso autólogo después de la aneurismectomía; la edad promedio fue de 58 años y el diámetro del aneurisma fue de 4.4 cm. Trece pacientes pudieron someterse a hemodiálisis mediante una nueva fístula arteriovenosa dentro de los 31 días (± 4-11 días). En un caso, debido a un flujo posoperatorio insuficiente (180-200 mL/min), se utilizó un acceso alternativo para la diálisis.* **Conclusiones:** *Es posible preservar la vía de acceso vascular en los aneurismas de fístula arteriovenosa mediante tratamiento quirúrgico en condiciones electivas.*

Palabras clave: *Fístulas arteriovenosas. Aneurisma. Aneurismectomía. Aneurismorrafia. Interposición de injerto venoso.*

***Correspondence:**
Ibrahim Demir
E-mail: ibrahimd128@gmail.com

Date of reception: 04-06-2023
Date of acceptance: 08-11-2023
DOI: 10.24875/CIRUE.M23000884

Cir Cir (Eng). 2025;93(5):525-530
Contents available at PubMed
www.cirugiaycirujanos.com

2444-0507/© 2023 Academia Mexicana de Cirugía. Published by Permanyer. This is an open access article under the terms of the CC BY-NC-ND license (http://creativecommons.org/licenses/by-nc-nd/4.0/).

Introduction

Chronic kidney disease refers to progressive loss of kidney function, characterized by kidney damage or an estimated glomerular filtration rate of < 60 mL/min/1.73 m^2 for a duration of 3 months or more, eventually leading to the need for dialysis or transplantation[1]. Arteriovenous fistulas (AVFs) created for hemodialysis purposes are considered the optimal vascular access route[2]. Compared to arteriovenous grafts and catheters used for hemodialysis, AVFs have longer patency and lower complication rates[3]. However, AVFs can be associated with life-threatening bleeding resulting from aneurysmal dilatation, which can occur in up to 60% of cases regardless of the duration of use[4] (Fig. 1). In cases where an aneurysm leads to bleeding, surgical approaches or endovascular methods are commonly employed to control the life-threatening bleeding, often resulting in the removal of the AVF[5,6].

In cases of aneurysms arising from AVF procedures, the continuity of the vascular access pathway and prevention of functional loss can be achieved by electively performing partial resection of the excessive wall of the aneurysm while preserving the wall integrity (aneurysmorraphy)[7]. Another surgical approach under elective conditions may involve aneurysmectomy and autologous venous graft interposition to ensure functional continuity of the vascular access pathway[8].

Methods

Patients

In the retrospective study conducted between September 2017 and May 2022, a total of 20 patients were included in the study. Among them, six patients who underwent partial aneurysmectomy with subsequent aneurysmorraphy for maintaining fistula continuity, and 14 patients who underwent aneurysmectomy with autologous venous graft for maintaining fistula continuity, were included in the study.

Patients with central venous obstructive lesions requiring separate treatment and potentially affecting access patency, those with central venous stenosis or occlusion requiring emergency surgery due to aneurysm rupture, and those with pseudoaneurysms were excluded from the study. Surgical repair indications were determined as thinning or erosion of the skin due to aneurysm, inability to meet dialysis needs, or high blood flow (> 1,500 mL/min). Informed consent forms were obtained from all patients and their families before the surgery.

Ethical consideration

This retrospective study was carried out after the approval of the Hatay Mustafa Kemal Universty Tayfur Ata Sökmen Medical Faculty Ethics Committee (Decision number: 15/Date: May 12, 2022). The hospital authority accepted the study results.

Pre-operative examination

Demographic data for all patients and the results of Doppler ultrasound examinations for all patients were retrospectively extracted from hospital records before the surgery. Aneurysms at the arteriovenous access site were defined as having a diameter larger than 20 mm. Temporary dialysis catheters were placed in all patients scheduled for surgery using the contralateral jugular vein.

Surgical procedure

Except for one patient (a 13-year-old male whose family declined regional block application), all patients who underwent aneurysmorraphy after partial aneurysmectomy were operated under regional block. The block procedure was performed under ultrasound guidance by the anesthesia unit. First, the extension of the aneurysm was determined using Doppler ultrasound, and then a skin incision was made. Healthy venous segments were prepared on both boundaries of the aneurysmatic segment. Heparin (100 units/kg) was administered intravenously. Following proximal and distal clamping, the aneurysm sac was longitudinally incised, and the lumen was irrigated with heparinized saline solution. The thrombus-adherent aneurysmal wall was partially resected. To guide aneurysmorraphy and prevent stenosis, arterial diameter measurement was performed, and a sterile dilatation bougie of 10-12 mm was inserted. The venous lumen was reduced and closed using non-absorbable polypropylene sutures of 6-0/13 mm. The clamps were released to restore blood flow. Excess skin was removed by cutting from both sides of the skin incision (Fig. 2). No adjuvant medical treatment was applied to increase the patency of the AVF.

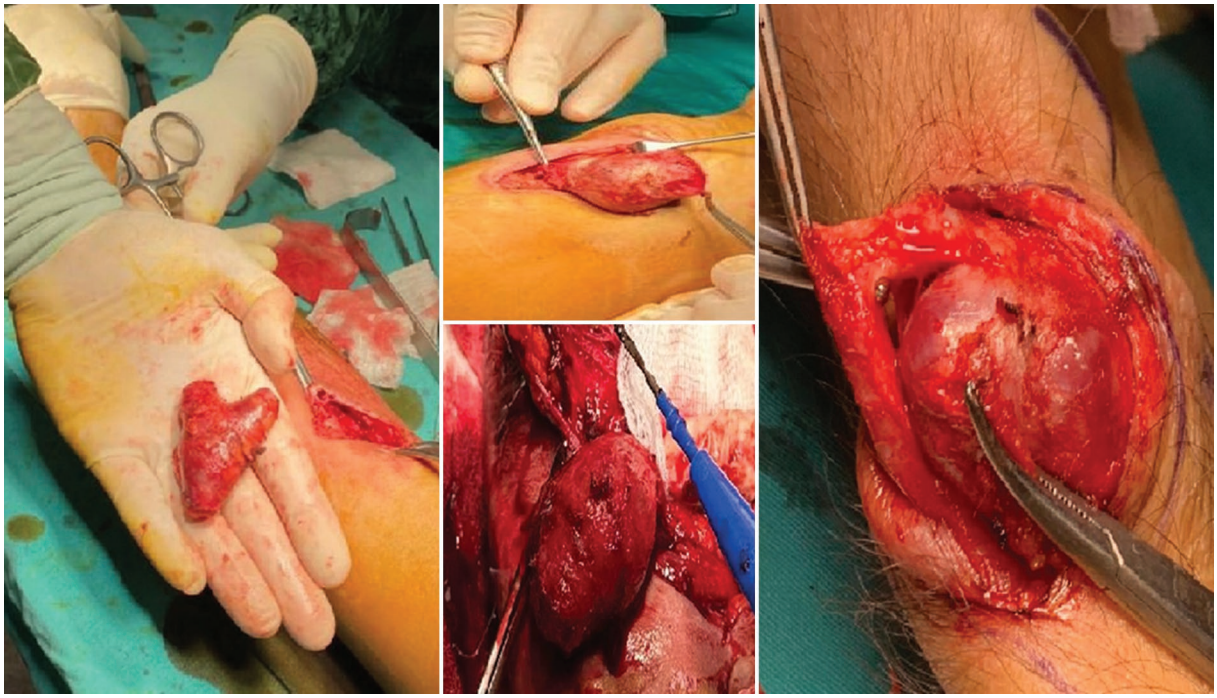

Figure 1. *Huge aneurysmal dilatation of arteriovenous fistulas.*

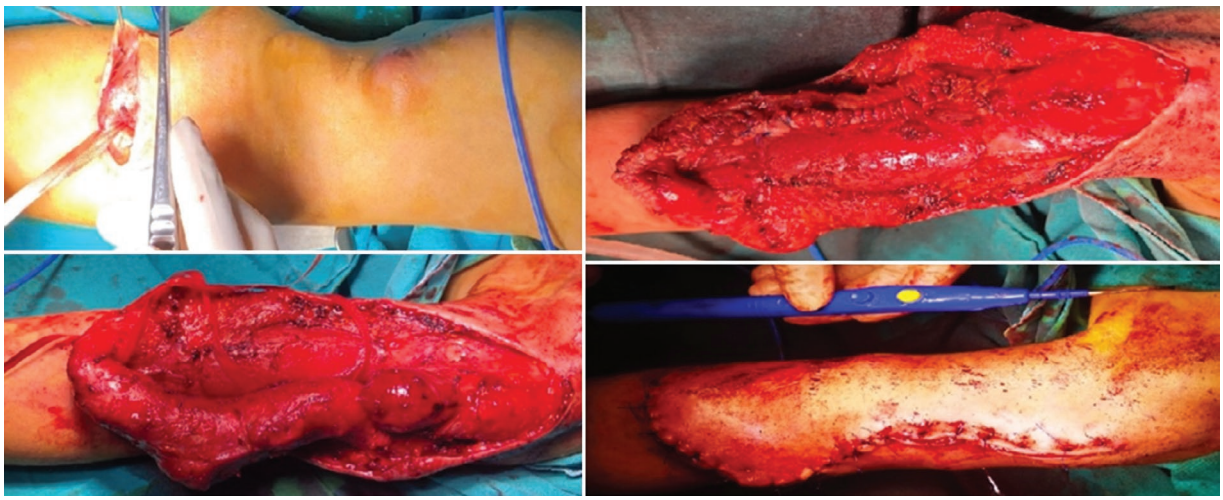

Figure 2. *Preparation of aneurysmatic segment of arteriovenous fistulas and closed skin after skin excision.*

For patients planned for autologous venous interposition after aneurysmectomy, pre-operative evaluation of the great saphenous vein was performed in the operating room conditions using Doppler ultrasound. All patients were operated under general anesthesia. First, the extension of the aneurysm was determined using Doppler ultrasound, and then a skin incision was made. Healthy venous segments were prepared on both boundaries of the aneurysmatic segment. After measuring the aneurysmatic segment with a sterile ruler, the autologous saphenous vein graft was harvested at an appropriate length. No hemoclips were used on the graft side. The branches of the venous graft were ligated using 3-0 silk sutures. Heparin (100 units/kg) was administered intravenously. After clamping, aneurysmectomy was performed. The autologous saphenous graft was anastomosed in the appropriate shape with non-absorbable polypropylene

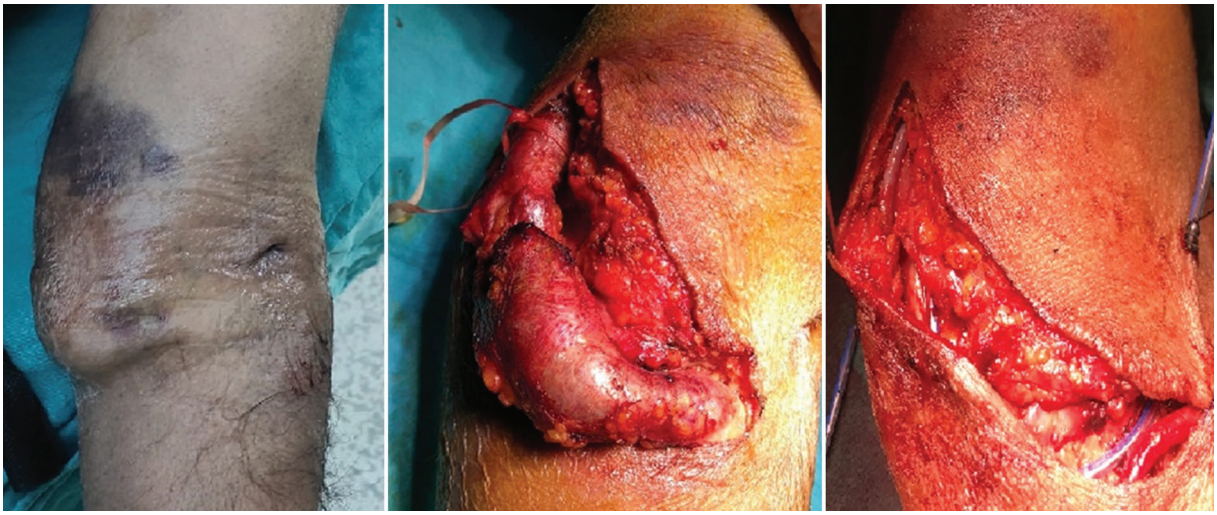

Figure 3. *Autologous venous interposition after aneurysmectomy.*

sutures of 6-0/13 mm in the direction of flow. The clamps were released to restore blood flow. Excess skin was removed by cutting from both sides of the skin incision (Fig. 3). No adjuvant medical treatment was applied to increase the patency of the AVF.

Follow-up

All patients were followed up for a period of 1 month. During this 1-month period, patients underwent hemodialysis with a temporary dialysis catheter. Primary patency was defined as the time from the moment of surgical procedure to the first hemodialysis session occurring within 1 month. Before the first hemodialysis session following the surgical procedure, patients underwent flow measurement using Doppler ultrasound based on clinical memory. In cases where there was suspicion of residual aneurysm or proximal stenosis, intraluminal angiographic imaging was planned.

Statistical analysis

The data were presented as means and standard deviations for continuous variables and as patient counts and percentages for categorical variables. Statistical analysis was performed using IBM Statistical Package for the Social Sciences Statistics version 21.0 software (IBM Corp., Armonk, NY). Comparison of means of continuous variables between the two groups was performed using t-test, and differences were considered significant at a probability level of $p < 0.05$.

Results

In Group I, which consisted of six patients who underwent aneurysmorrhaphy after partial aneurysmectomy, the median age was 49 (13-62 years). The patients had been using the same vascular access for hemodialysis for an average of 13.1 ± 5.2 years. The mean aneurysm diameter in Group I was measured as 4.1 (± 1.8) cm. Five patients in Group I had a history of multiple AVF access pathways. The 13-year-old male patient had a previous AVF access history. One patient, a 37-year-old male, was taken to the emergency operating room due to hemorrhage 2 h after the operation. The bleeding from the aneurysmorrhaphy site was repaired using absorbable polypropylene sutures (6-0/13 mm), and hemostasis was achieved. All Group I patients were able to undergo dialysis through the newly salvaged access pathway for hemodialysis at 30 days. As no findings suggestive of residual aneurysm or proximal stenosis were detected in any of the patients, angiographic imaging was not performed.

In Group II, which consisted of 14 patients who underwent autologous venous interposition after aneurysmectomy, the median age was 58 (49-67 years). The patients had been using the same vascular access for hemodialysis for an average of 9.7 ± 7.6 years. The mean aneurysm diameter in Group II was measured as 4.4 (± 1.7) cm. All Group II patients had a history of multiple AVF access pathways. Two patients, one male, and one female, were taken to the emergency operating room within the first 24 h

postoperatively due to hemorrhage. It was determined that the bleeding was not related to the anastomosis line but originated from the excised surrounding tissues of the aneurysm sac, and hemostasis was achieved. Among the 13 patients in Group II, hemodialysis needs were met with a new AVF within 30 days (± 4-11 days). One patient was switched to alternative AVF routes for dialysis at the 4th week postoperatively due to an ultrasound evaluation indicating a flow rate of 180-200 mL/min. In another patient, upper extremity edema occurred after the surgical procedure, and intraluminal angiographic imaging was performed due to suspicion of proximal stenosis. However, no stenosis or residual aneurysm was found.

Discussion

Chronic kidney failure is being increasingly diagnosed at a high frequency[8]. Hemodialysis, peritoneal dialysis, and kidney transplantation are essential life-saving interventions for patients diagnosed with chronic kidney failure[9]. The number of patients requiring kidney transplantation is increasing at a faster rate than the number of available donors, resulting in wait times of up to 4 years for kidney transplantation[10,11].

According to the guidelines for the diagnosis and treatment of chronic kidney failure, approximately 65% of diagnosed patients require AVF for hemodialysis[12]. Although AVF is the most commonly preferred method for hemodialysis, complications such as aneurysm formation, neurological disorders, and vascular steal syndrome are known to occur[13].

The occurrence of true or false aneurysmal dilation in AVFs is a frequently observed condition[14-16]. In cases where an aneurysm ruptures and starts bleeding profusely, urgent surgical or endovascular intervention is necessary to manage life-threatening hemorrhage[17]. While endovascular methods may successfully eliminate the aneurysm and maintain the continuity of the vascular access pathway dependent on the presence of a stent graft, they may restrict needle access[5]. Although ligation may be life-saving in situations where hemorrhage poses a threat to life, it can result in permanent loss of vascular access pathway[18]. While there is no standardized treatment method for complications associated with AVFs, guidelines recommend preserving the vascular access pathway[5,18,19]. Various aneurysmorrhaphy techniques, including partial aneurysmectomy and autologous venous graft interposition, aim to eliminate the aneurysm while preserving the vascular access pathway[19,20]. There are studies demonstrating the safety and long-term outcomes of the combination of partial aneurysmectomy and aneurysmorrhaphy[21,22]. However, there are no clinical studies comparing the effectiveness and safety of surgical approaches in the treatment of AVF-related aneurysms. Although there is no standard method selection guideline, it is recommended to preserve the vascular access pathway, and if a suitable autologous venous graft is not identified during intraoperative Doppler ultrasound screening, partial aneurysmectomy, and longitudinal aneurysmorrhaphy with prolene are performed. In cases of upper extremity autologous fistula aneurysms, 20 patients were treated with surgical methods in this study series, and technical success was achieved in all patients at the time of the procedure.

Limitations

Although the short follow-up period and numerical imbalance between the groups included in the study are among the limitations of the study, sharing the results without conducting a comparative analysis between the groups eliminates the statistical flaw.

Conclusion

The diagnosis and treatment guidelines for chronic kidney failure recommend intervention for aneurysmal dilations that arise from the use of AVFs, but there is no standardized treatment method. With this study, we aimed to share the early-term outcomes of the two different approaches we implemented. The medium and long-term follow-up results of the surgical methods we applied will guide us in selecting the appropriate method for the future.

Funding

The authors did not receive any funding during this study.

Conflicts of interest

The authors declare no conflicts of interest in this study.

Ethical considerations

Protection of humans and animals. The authors declare that no experiments involving humans or animals were conducted for this research.

Confidentiality, informed consent, and ethical approval. The authors have followed their institution's confidentiality protocols, obtained informed consent from patients, and received approval from the Ethics Committee. The SAGER guidelines were followed according to the nature of the study.

Declaration on the use of artificial intelligence. The authors declare that no generative artificial intelligence was used in the writing of this manuscript.

References

1. Chapter 1: definition and classification of CKD. Kidney Int Suppl (2011). 2013;3:19-62.
2. Hu H, Patel S, Hanisch JJ, Santana JM, Hashimoto T, Bai H, et al. Future research directions to improve fistula maturation and reduce access failure. Semin Vasc Surg. 2016;29:153-71.
3. Huijbregts HJ, Bots ML, Wittens CH, Schrama YC, Moll FL, Blankestijn PJ, et al. Hemodialysis arteriovenous fistula patency revisited: results of a prospective, multicenter initiative. Clin J Am Soc Nephrol. 2008;3:714-9.
4. Saha M, Allon M. Diagnosis, treatment, and prevention of hemodialysis emergencies. Clin J Am Soc Nephrol. 2017;12:357-69.
5. Inston N, Mistry H, Gilbert J, Kingsmore D, Raza Z, Tozzi M, et al. Aneurysms in vascular access: state of the art and future developments. J Vasc Access. 2017;18:464-72.
6. Shemesh D, Goldin I, Zaghal I, Berelowitz D, Verstandig AG, Olsha O. Stent graft treatment for hemodialysis access aneurysms. J Vasc Surg. 2011;54:1088-94.
7. Wang S, Wang MS. Successful use of partial aneurysmectomy and repair approach for managing complications of arteriovenous fistulas and grafts. J Vasc Surg. 2017;66:545-53.
8. Vaidya SR, Aeddula NR. Chronic renal failure. In: StatPearls. Treasure Island, FL: StatPearls Publishing; 2022.
9. Woo K, Cook PR, Garg J, Hye RJ, Canty TG. Midterm results of a novel technique to salvage autogenous dialysis access in aneurysmal arteriovenous fistulas. J Vasc Surg. 2010;51:921-5, 925.e1.
10. Timsit MO, Kleinclauss F, Thuret R. Histoire chirurgicale de la transplantation rénale [History of kidney transplantation surgery]. Prog Urol. 2016;26:874-881.
11. U.S. Department of Health and Human Services. 2007 Annual Report of the U.S. Organ Procurement and Transplantation Network and the Scientific Registry of Transplant Recipients: Transplant Data 1994-2003. Rockville, MD, Richmond, VA, Ann Arbor, MI: United Network for Organ Sharing, Arbor Research Collaborative for Health; 2007.
12. Centers for Medicare and Medicaid Services; Kinney R. 2005 Annual Report: ESRD clinical performance measures project. Am J Kidney Dis. 2006;48(4 Suppl 2):S1-106.
13. Salahi H, Fazelzadeh A, Mehdizadeh A, Razmkon A, Malek-Hosseini SA. Complications of arteriovenous fistula in dialysis patients. Transplant Proc. 2006;38:1261-4.
14. Kordzadeh A, Panayiotopoulos YP. Re: 'aneurysmal degeneration of the inflow artery after arteriovenous access for hemodialysis.' Eur J Vasc Endovasc Surg. 2015;49:354.
15. Mestres G. Response to 'Re: aneurysmal degeneration of the inflow artery after arteriovenous access for hemodialysis.' Eur J Vasc Endovasc Surg. 2015;49:354-5.
16. Valenti D, Mistry H, Stephenson M. A novel classification system for autogenous arteriovenous fistula aneurysms in renal access patients. Vasc Endovascular Surg. 2014;48:491-6.
17. Balaz P, Björck M. True aneurysm in autologous hemodialysis fistulae: definitions, classification and indications for treatment. J Vasc Access. 2015;16:446-53.
18. Sigala F, Kontis E, Saßen R, Mickley V. Autologous surgical reconstruction for true venous hemodialysis access aneurysms--techniques and results. J Vasc Access. 2014;15:370-5.
19. Pasklinsky G, Meisner RJ, Labropoulos N, Leon L, Gasparis AP, Landau D, et al. Management of true aneurysms of hemodialysis access fistulas. J Vasc Surg. 2011;53:1291-7.
20. Georgiadis GS, Lazarides MK, Panagoutsos SA, Kantartzi KM, Lambidis CD, Staramos DN, et al. Surgical revision of complicated false and true vascular access-related aneurysms. J Vasc Surg. 2008;47:1284-91.
21. Almehmi A, Wang S. Partial aneurysmectomy is effective in managing aneurysm-associated complications of arteriovenous fistulae for hemodialysis: case series and literature review. Semin Dial. 2012;25: 357-64.
22. Pierce GE, Thomas JH, Fenton JR. Novel repair of venous aneurysms secondary to arteriovenous dialysis fistulae. Vasc Endovascular Surg. 2007;41:55-60.