Check for updates

CLINICAL CASE

Report of two cases of high cervical injury: an adequate functional result with timely surgical management

Reporte de dos casos de lesión cervical alta: un resultado funcional adecuado con manejo quirúrgico oportuno

Antonio Sosa-Nájera[1], Abrahan A. Tafur-Grandett[2], Alejandro Ceja-Espinosa[1], Raúl Huato-Reyes[1], and Jórge Ortega-Espino[2]*

[1]Department of Neurosurgery, Grupo Neurológico de Alta Especialidad, Hospital Ángeles Morelia, Morelia, Michoacán; [2]Department of Neurosurgery, Centro Médico "Lic. Adolfo López Mateos", Instituto de Salud del Estado de México, Toluca, Estado de México. Mexico

Abstract

Introduction: *Odontoid fractures correspond to 9-15% of cervical spine fractures. Atlas fracture is rare (3-13%)[8].* **Case presentation:** *Male with Anderson and D´Alonzo Type II Odontoid fracture with unstable fragment treated with occipitocervical fixation with occipital plate, C2-C3 transfacet screws; Female with type E Jefferson fracture + anterolateral atloaxial dislocation, treated with occipitocervical fixation, C2-C3-C4 transfacet screws.* **Discussion:** *Anderson and D'Alonzo Type II fractures and Jefferson type E fractures are a surgical emergency due to instability and neurological deficit.*

Keywords: *Type II odontoid fracture. Jefferson fracture. Spinal cord trauma. Occipitocervical fixation. Posterior cervical instrumented fusión.*

Resumen

Introducción: *Las fracturas odontoideas corresponden del 9-15% de las fracturas de la columna cervical. La fractura del atlas es poco común (3-13%)[8].* **Presentación del caso:** *Masculino con fractura de Odontoides tipo II de Anderson y D´Alonzo con fragmento inestable tratado con fijación occipitocervical con placa occipital, tornillos transfacetarios C2-C3; Femenino con fractura de Jefferson tipo E + luxación atloaxoidea anterolateral, tratada con fijación occipitocervical, tornillos transfacetarios C2-C3-C4.* **Discusión:** *Fracturas tipo II de Anderson y D´Alonzo y fracturas de Jefferson tipo E son una urgencia quirúrgica debido a inestabilidad y déficit neurológico.*

Palabras clave: *Fractura de odontoides tipo II. Fractura de Jefferson. Traumatismo Raquimedular. Fijación occipitocervical. Fusión cervical posterior.*

***Correspondence:**
Abrahan A. Tafur Grandett
E-mail: atafur.grandett@hotmail.com

Date of reception: 08-09-2021
Date of acceptance: 21-10-2021
DOI: 10.24875/CIRUE.M21000754

Cir Cir. 2024;92(5):655-660
Contents available at PubMed
www.cirugiaycirujanos.com

2444-0507/© 2021 Academia Mexicana de Cirugía. Published by Permanyer. This is an open access article under the terms of the CC BY-NC-ND license (http://creativecommons.org/licenses/by-nc-nd/4.0/).

Introduction

Odontoid fractures correspond to 9-15% of cervical spine fractures[1]. Of these, the Anderson and D´Alonzo Type II fracture is the most common and occurs in more than 60% of cases[2]. These are usually the result of high energy trauma, such as car accidents or falls from height, most of them are associated with a head injury to the frontal region that indirectly produces an extension injury and predominates in males[3].

According Anderson and D´Alonzo, these fractures can be classified as: Type I: Fracture of the odontoid apex, Type II: Fracture of the odontoid base, Type III: Vertebral body fracture, and Type II odontoid fractures (T II-OF) can be treated surgically or conservatively[1,4].

Various treatments have been proposed for TII-OF with the aim of reducing fracture fragments, stabilizing the fracture, allowing fusion, and reducing pain[5]. In general, the treatment of patients with a fracture of the odontoid process is based on the type of fracture, the age of the patient, the patient's health, the relationship with neurological deficits, and personal preference of the surgeon. Relative indications for surgery include fracture dislocation > 5 mm, angulation > 10 and failed attempts at closed reduction. Surgical treatment may involve anterior odontoid screw fixation or posterior atlantoaxial arthrodesis, resulting in stabilization of the upper cervical spine[5,6].

In cases with indication for surgery for surgery, the purpose of the intervention will be: (A) to release trapped root elements through discectomies, corpectomies, laminectomies, evacuation of collections of expansion of spaces, (B) align vertebral segments by compass or halo traction, manipulation or surgery, (C) stabilize vertebral elements with surgical techniques via anterior, posterior or with double 360° approaches, and (D) stop the clinical-radiological evolution, (E) allow maximum functional recovery[7]. Atlas fracture is rare, accounting for 3-13% of all cervical spine fractures and 1.3-2% of all spinal injuries[8,9]. Unstable atlas fracture is even rare and is mainly caused by vertical falls, traffic accidents and other vertical traumatic forces[9]. Atlas fractures were classified by Jefferson in 1920, into seven types (Table 1)[10].

Jefferson Type E fracture is very dangerous, as displacement of bone blocks can cause spinal cord injury, leading to serious complications such as paraplegia and death.

Therefore, the stability of the atlantoaxial complex must be reconstructed surgically. Treatment is aimed at correcting the dislocation, restoring stability to the atlantoaxial joint, and retaining the maximum degree of motion of the cervical spine[9].

Table 1. Jefferson Classification of Atlas fractures

Type	Anatomical diagnosis
A	Unilateral or bilateral anterior arch fracture
B	Unilateral or bilateral posterior arch fracture
C	Simple fracture of a lateral mass
D	Comminuted lateral mass fracture (the TLA is possibly damaged)
E	True Jefferson fracture in which the anterior and posterior arches of the atlas are fractured bilaterally (unstable atlas fracture)
F	Linear or crossed unilateral anterior arch and posterior arch fractures
G	Isolated TLA break

TLA: transverse ligament of the atlas.

Case presentation

The first case is a 20 years old male who suffers direct head trauma when diving into a pool exerting direct axial force on the cervical spine, refers to paresthesia in upper limbs at the time of trauma, denies loss of alertness, as well as epileptic seizures, 15 points in the Glasgow Coma Scale, motor and sensory system without alterations, global ++/+++ muscle stretch reflexes, intact posterior cords, and multiple SCALP- type cranial vault wounds.

Simple tomography of normal skull and simple crane cervical tomography with 3D reconstruction showing Anderson and D´Alonzo Type II odontoid fracture with unstable left fragment and risk of posterior displacement (Fig. 1). An urgent decision was made to perform a posterior approach for occipitocervical fixation with occipital plate, 4 C2-C3 polyaxial trans facet screws, titanium bars, and Cross Link and subsequent placement of rigid Aspen-type collar (Fig. 2).

The second case is a 29 years old female who has a fall of approximately 6 m in height, exerting vertical force on the cervical spine, refers to a sudden decrease in force in both thoracic limbs, denies other symptoms. To the neurological examination with a 15 points in the Glagow Coma Scale, motor system with force 3/5 on the Daniels scale C5, C6, C7, and C8 myotomes, sensory without alterations, intact posterior cords, global ++/+++ muscle stretch reflexes

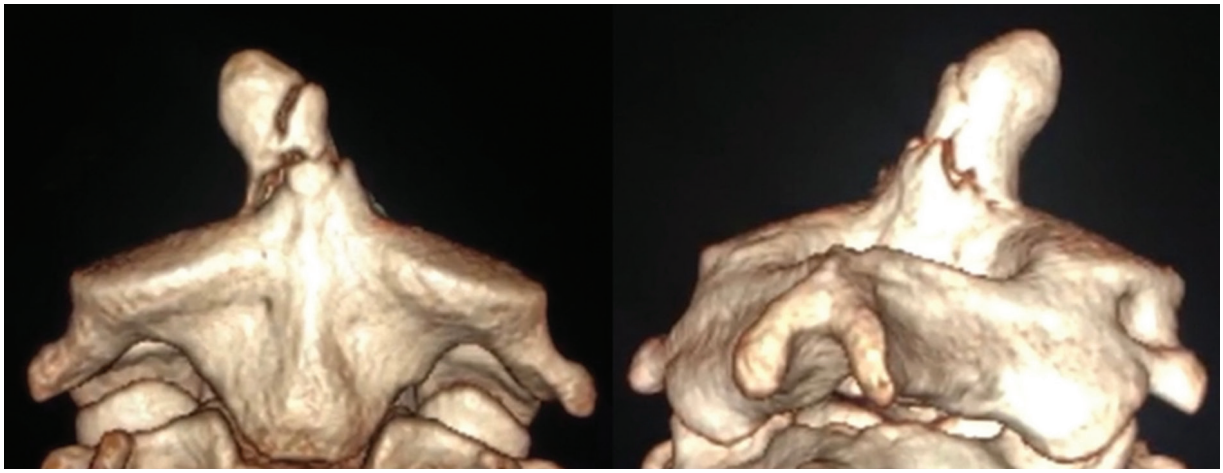

Figure 1. *3D reconstruction of craniocervical CT with Anderson and D´Alonzo Type II odontoid fracture with unstable left fragment and posterior displacement.*

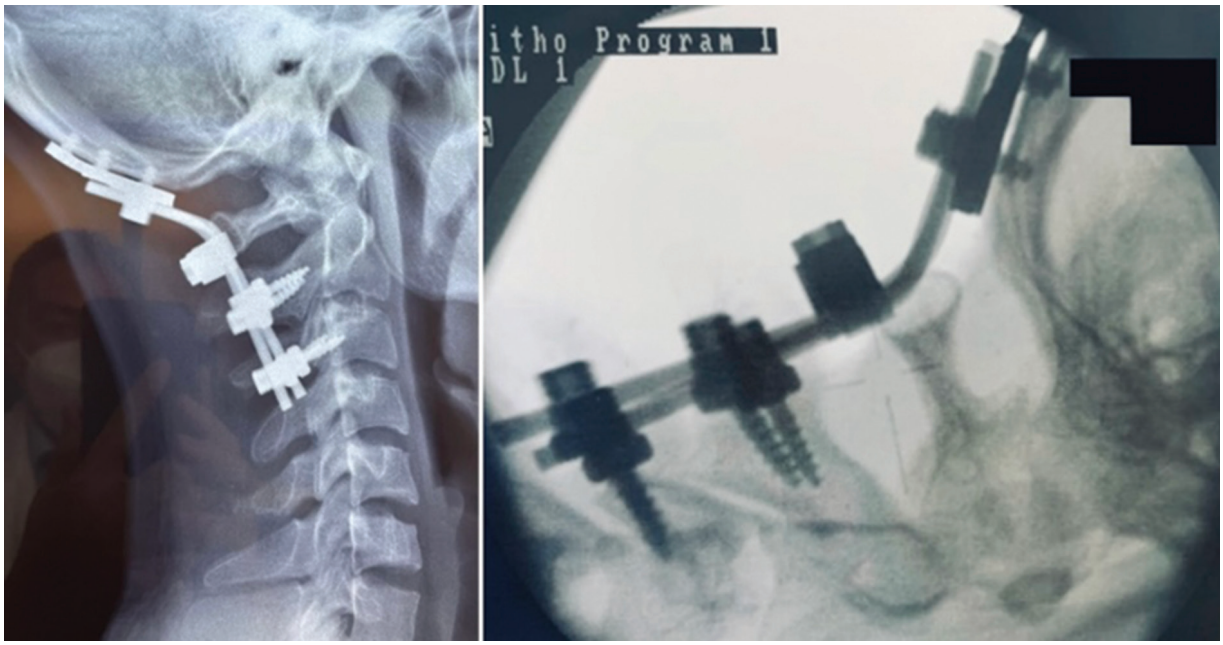

Figure 2. *Occipitocervical fixation with occipital plate, four poly axial trans facet screws C2 C3, titanium bars, and Cross Link.*

craniocervical computerized tomography showing Type E Jefferson fracture + anterolateral atloaxial dislocation (Fig. 3).

It was to decide to perform a posterior approach with occipitocervical fixation with an occipital plate, six polyaxial trans facet screws of C2-C3-C4, titanium bars, and Cross Link and subsequent placement of a rigid Aspen-type collar (Fig. 4).

Both patients in the post-operative period without added neurological deficit, presenting reversal of symptoms on admission, with control radiological studies with adequate placement of prosthetic material, returned home 2 days after the operation (Fig. 5).

Discussion

Odontoid fractures are often caused by high energy trauma, such as fall from a height and traffic accidents[11-13]. Represent 9-15% of all cervical fractures. These injuries are believed to be extremely dangerous due to the potential risk of upper cervical cord injury after traumatic instability. The distribution of odontoid

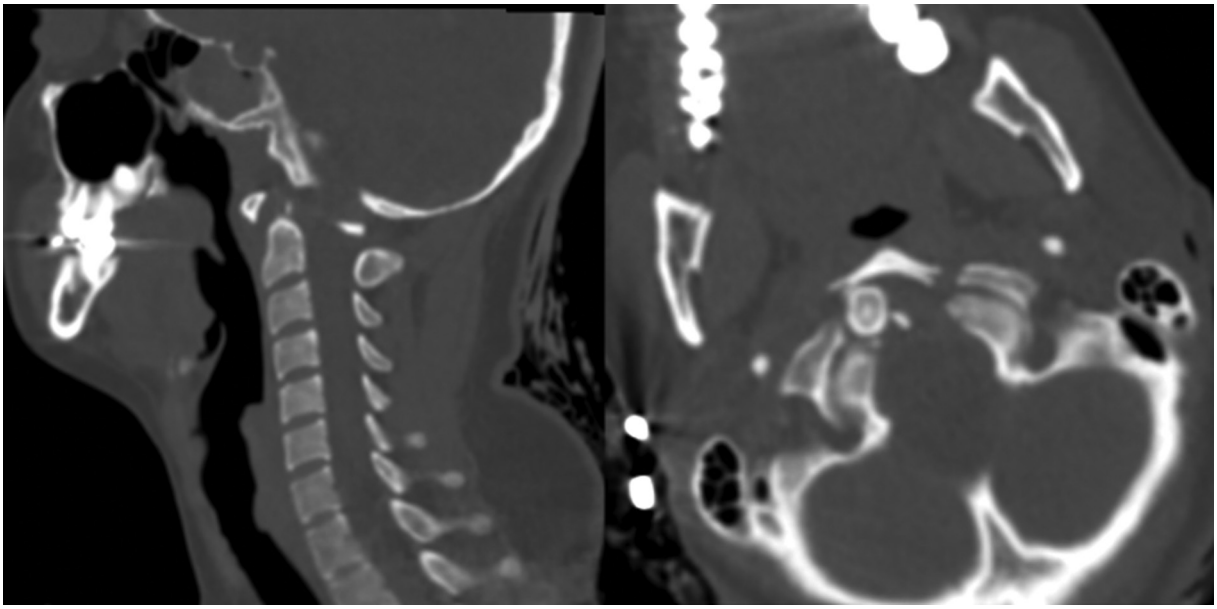

Figure 3. *Craniocervical TC scans showing type E Jefferson fracture + anterolateral atloaxial dislocation.*

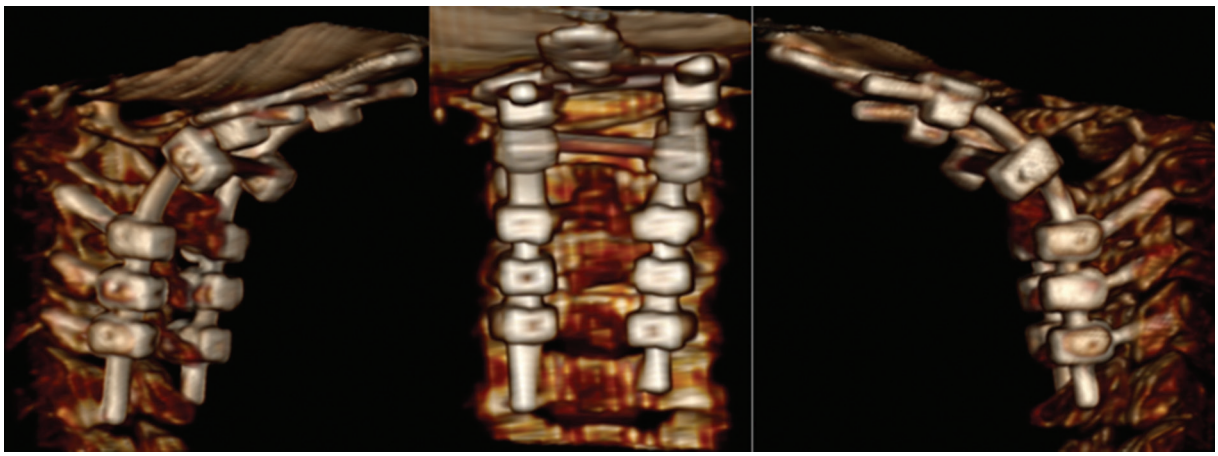

Figure 4. *Occipitocervical fixation with an occipital plate, six polyaxial trans facet screws C2-C3-C4, titanium bars, and Cross Link.*

fractures according to age shows two peaks, one in younger patients (17-30 years), associated with high energy trauma, the other peak occurs in geriatric patients (> 70 years old) and is associated with low energy trauma, such as falls[1,14,15].

Although the majority of patients arriving at the hospital will not have a noticeable neurologic injury, a detailed neurologic evaluation is required, as displaced fracture fragments can compress the spinal cord and lead to cervical myelopathy. In a review of 446 T II-OF, Przybylsky found that 82% of the patients were neurologically intact, 8% had minimal sensory disturbances in the scalp or extremities and 10% had significant neurological deficits[16]. However, in a retrospective analysis of 16 patients with neglected odontoid fractures, Crockard et al.[1] found that all patients had neck pain at 1 year and 69% had clinical signs of myelopathy, including upper extremity weakness and gait disturbances[1,7].

Acceptable options for the initial treatment of all types of odontoid fractures include external cervical immobilization with a hard cervical collar, whereas Type II fractures should be considered for surgical fixation in the context of a 5 mm displacement, communication, Type IIA, and inability to achieve/maintain fracture alignment with external immobilization[3].

Surgeons appear to recognize morbidity as an important factor during the decision-making process and have concluded that morbidity is not an absolute

Figure 5. *Post-surgical result without neurological deficit, with adequate rangers of mobility in cervical flexion and extension, strength 5/5 on the Daniels scale in all four extremities.*

contraindication to surgery. The morbidity that is relevant for surgery is also relevant for non-surgical treatment[1].

Jefferson fractures are associated with other traumatic cervical injuries in up to 50% of cases, most commonly with posteriorly displaced T II-OF[17,18]. Unstable Jefferson fractures are characterized by a tear of the transverse ligament of the atlas (TLA), resulting in lateral displacement of the lateral masses after excessive axial loading[18,19].

At present, the treatment of C1 fractures remains controversial and there are no internationally accepted standards of treatment. For isolated atlas fractures, conservative treatment is the main method, but for unstable atlas fractures, surgical treatment remains the preferred method. It is widely accepted that surgery is indicated for atlas fracture associated with atlantooccipital instability, intraligamentous rupture of the TLA, and for "unstable" atlas fracture[9,20,21].

Anderson and D'Alonzo T II-OF and Jefferson type E fractures are a surgical emergency due to the potential for instability, they present and the secondary neurological deficit for the patient requesting to generate quadriplegia, high cervical injury with ascending spinal cord edema and secondary bulbar injury, cardiorespiratory arrest, and even death, surgical treatment must be individualized for each patient and according to the surgeon's expertise.

The cure rate for T II-OF (with an age range of 18-64 years) treated with posterior atlantoaxial fixation is relatively high[22].

Decision-making for odontoid fracture is challenging and requires careful consideration of many factors related to the nature of the fracture and the patient. The selection of the fixation procedure requires a thorough understanding of the patient´s anatomy and careful preparatory evaluation and planning for successful treatment and favorable clinical outcomes[3].

For Jefferson Type E fractures occipitocervical fixation combined with short-term external immobilization establishes upper cervical stability and prevents further spinal cord injury and damage to nerve function[18].

Occipitocervical fusion with transpedicular fixation has the advantages of reliable fixation, few complications, and high fusion rates[9].

The most important point of treatment for atlantoaxial fracture is to reduce and stabilize the injured segment to prevent further neurological injury. The TLA frequently causes severe instability of the upper cervical spine.

Surgical treatment is always necessary for patients combined with bilateral anterior and posterior arch fractures, and unstable fractures with lesion of the TLA[23,24].

Funding

The authors declare no funding was received.

Conflicts of interest

The authors declare that there are no conflicts of interest.

Ethical disclosures

Protection of human and animal subjects. The authors declare that no experiments were performed on humans or animals for this study.

Confidentiality of data. The authors declare that they have followed the protocols of their work center on the publication of patient data.

Right to privacy and informed consent. The authors have obtained the informed consent of the patients and/or subjects referred to in the article. This document is in the possession of the corresponding author.

References

1. Falavigna A, Righesso O, Da Silva PG, Siri CR, Daniel JW, Veiga JC, et al. Management of Type II odontoid fractures: experience from Latin American spine centers. World Neurosurg. 2017;98:673-81.
2. Fiumara E, Tumbiolo S, Lombardo MC, Maugeri R, Porcaro S, Gioia F, et al. Type II Odontoid Fracture: a case series highlighting the treatment strategies. Acta Neurochir Suppl. 2019;125:317-24.
3. Carvalho AD, Figueiredo J, Schroeder GD, Vaccaro AR, Rodrigues-Pinto R. Odontoid fractures: a critical review of current management and future directions. Clin Spine Surg. 2019;32:313-23.
4. Patel AA, Lindsey R, Bessey JT, Chapman J, Rampersaud R, Spine Trauma Study Group. Surgical treatment of unstable Type II odontoid fractures in skeletally mature individuals. Spine (Phila Pa 1976). 2010;35:S209-18.
5. Clark CR, White AA 3rd. Fractures of the dens. A multicenter study. J Bone Joint Surg Am. 1985;67:1340-8.
6. Grasso G, Leone L, Torregrossa F. Management of odontoid cervical fracture. World Neurosurg. 2019;123:246-7.
7. Ochoa G. Surgical management of odontoid fractures. Injury. 2005;36 Suppl 2:B54-64.
8. Kandziora F, Chapman JR, Vaccaro AR, Schroeder GD, Scholz M. Atlas fractures and atlas osteosynthesis: a comprehensive narrative review. J Orthop Trauma. 2017;31:S81-9.
9. Guo W, Lin Y, Huang J, Hu F, Ding Z, Xiao Z, et al. Treatment strategy of unstable atlas fracture: a retrospective study of 21 patients. Medicine (Baltimore). 2020;99:e20153.
10. Jefferson G. Fracture of the atlas vertebra. Report of four cases and a review of those previously recorded. Br J Surg. 2005;7:407-22.
11. Ni B, Guo Q, Lu X, Xie N, Wang L, Guo X, et al. Posterior reduction and temporary fixation for odontoid fracture: a salvage maneuver to anterior screw fixation. Spine (Phila Pa 1976). 2015;40:E168-74.
12. Ryken TC, Hadley MN, Aarabi B, Dhall SS, Gelb DE, Hurlbert RJ, et al. Management of isolated fractures of the axis in adults. Neurosurgery. 2013;72 Suppl 2:132-50.
13. Hadley MN, Dickman CA, Browner CM, Sonntag VK. Acute axis fractures: a review of 229 cases. J Neurosurg. 1989;71:642-7.
14. Subach BR, Morone MA, Haid RW Jr., McLaughlin MR, Rodts GR, Comey CH. Management of acute odontoid fractures with single-screw anterior fixation. Neurosurgery. 1999;45:812-9; discussion 819-20.
15. Lee PC, Chun SY, Leong JC. Experience of posterior surgery in atlanto-axial instability. Spine (Phila Pa 1976). 1984;9:231-9.
16. Butler JS, Dolan RT, Burbridge M, Hurson CJ, O'Byrne JM, McCormack D, et al. The long-term functional outcome of Type II odontoid fractures managed non-operatively. Eur Spine J. 2010;19:1635-42.
17. Levine AM, Edwards CC. Fractures of the atlas. J Bone Joint Surg Am. 1991;73:680-91.
18. Hu Y, Yuan ZS, Kepler CK, Dong WX, Sun XY, Zhang J. Comparison of occipitocervical and atlantoaxial fusion in treatment of unstable Jefferson fractures. Indian J Orthop. 2017;51:28-35.
19. Kontautas E, Ambrozaitis KV, Kalesinskas RJ, Spakauskas B. Management of acute traumatic atlas fractures. J Spinal Disord Tech. 2005;18:402-5.
20. Hein C, Richter HP, Rath SA. Atlantoaxial screw fixation for the treatment of isolated and combined unstable Jefferson fractures-experiences with 8 patients. Acta Neurochir (Wien). 2002;144:1187-92.
21. Mead LB 2nd, Millhouse PW, Krystal J, Vaccaro AR. C1 fractures: a review of diagnoses, management options, and outcomes. Curr Rev Musculoskelet Med. 2016;9:255-62.
22. Huang DG, Zhang XL, Hao DJ, He BR, Wang XD, Liu TJ. The healing rate of Type II odontoid fractures treated with posterior atlantoaxial screw-rod fixation: a retrospective review of 77 patients. J Am Acad Orthop Surg. 2019;27:e242-8.
23. Cao L, Yang E, Xu J, Lian X, Cai B, Liu X, et al. "Direct vision" operation of posterior atlantoaxial transpedicular screw fixation for unstable atlantoaxial fractures: a retrospective study. Medicine (Baltimore). 2017;96:e7054.
24. Takayasu M, Aoyama M, Joko M, Takeuchi M. Surgical intervention for instability of the craniovertebral junction. Neurol Med Chir (Tokyo). 2016;56:465-75.