Check for updates

ORIGINAL ARTICLE

Comparison of US elastography and chemical shift magnetic resonance imaging in multifidus muscle fatty degeneration

Comparación de la elastografía US y la resonancia magnética con codificación de desplazamiento químico en la degeneración grasa del músculo multífido

Fatıh Kırcın[1], Bahar Yanık[2], Erdogan Bulbul[2], Emrah Akay[2], and Gulen Demırpolat[2]*

[1]Radiology Clinic, Afyonkarahisar Sandikli State Hospital, Afyonkarahisar; [2]Department of Radiology, Balikesir University School of Medicine, Balikesir. Turkey

Abstract

Objective: *The purpose of this study was to investigate the feasibility of the use of shear wave elastography (SWE) in comparison to chemical shift encoding (CSE) magnetic resonance imaging (MRI) for the evaluation of multifidus muscle fatty degeneration in patients with chronic low back pain.* **Method:** *Multifidus muscles were evaluated with the CSE-MRI and SWE examinations in control and patient groups. With the in-phase and out-phase sequences in CSE-MRI, signal intensity index (SII), and signal intensity suppression ratio (SISR) values; with the SWE method, shear wave velocity values were determined. Differences in the mean values of these parameters per level and study group were analyzed by Student's t-test.* **Results:** *SWE revealed significantly lower stiffness at the L2-3 level, consistent with the signal index values (SII-SISR) showing increased fatty infiltration on MRI in the patient group. No such relationship was found at the L4-5 level or in control group.* **Conclusions:** *SWE may be a promising method to show muscle fatty infiltration at L2-3 level in patients with chronic low back pain.*

Keywords: *Fatty infiltration. muscle. Opposed-phase. Shear wave elastography. Stiffness. Low back pain. Magnetic resonance imaging. Multifidus.*

Resumen

Objetivo: *Investigar la viabilidad del uso de la elastografía de ondas de corte en comparación con la resonancia magnética con codificación de desplazamiento químico (RM-CDQ) para la evaluación de la degeneración grasa del músculo multífido en pacientes con dolor lumbar crónico.* **Método:** *Los músculos multífidos se evaluaron con RM-CDQ y elastografía de ondas de corte en los grupos de control y de pacientes. Se consideraron las secuencias en fase y fuera de fase en RM-CDQ, y los valores del índice de intensidad de señal y del índice de supresión de intensidad de señal; con el método de elastografía de ondas de corte se determinaron los valores de velocidad de onda de corte. Las diferencias en los valores medios de estos parámetros por nivel y por grupo de estudio se analizaron mediante la prueba t de Student.* **Resultados:** *La elastografía de ondas de corte reveló una rigidez significativamente menor en el nivel L2-3, consistente con los valores de los índices de señal que muestran una mayor infiltración grasa en la RM en el grupo de pacientes. No se encontró tal relación en el nivel L4-5 ni en el grupo de control.* **Conclusiones:** *La elastografía de ondas de corte puede ser un método prometedor para mostrar la infiltración grasa muscular a nivel L2-3 en pacientes con dolor lumbar crónico.*

Palabras clave: *Infiltración grasa. Lumbalgia. Resonancia magnética. Músculo multífido. Fase opuesta. Elastografía de ondas de corte. Rigidez.*

***Correspondence:**
Erdogan Bulbul
E-mail: drerdoganbulbul@yahoo.com

Date of reception: 22-01-2024
Date of acceptance: 04-04-2024
DOI: 10.24875/CIRUE.M24000748

Cir Cir (Eng). 2024;92(5):620-627
Contents available at PubMed
www.cirugiaycirujanos.com

2444-0507/© 2024 Academia Mexicana de Cirugía. Published by Permanyer. This is an open access article under the terms of the CC BY-NC-ND license (http://creativecommons.org/licenses/by-nc-nd/4.0/).

Introduction

The World Health Organization reports chronic low back pain as one of the leading musculoskeletal problems in the world[1]. Various publications revealed that fatty infiltration of the lumbar multifidus muscle is closely related to low back pain[2-4]. Physical therapy focused on multifidus muscle has been shown to result in regression of fatty infiltration within the muscle, which correlates with functional improvement[5]. Detection of fatty infiltration of lumbar muscles may be highly significant for predicting clinical progression and choosing optimal personalized treatment options[5-8]. Therefore, non-invasive, easily accessible, and reliable imaging techniques are promising tools. Modalities that have been shown useful in the evaluation of intramuscular fatty infiltration include ultrasonography (US), computerized tomography (CT), and magnetic resonance imaging (MRI)[9-13]. Among these different methods, some specific MRI techniques and sequences, such as MR spectroscopy, chemical shift encoded (CSE) imaging stand out[13-15]. CSE MRI is a technique that can show even minimal amounts of fat using different precession frequencies of water and lipid hydrogen protons. Various researchers have shown the feasibility of CSE MR imaging in the evaluation of fatty infiltration of multifidus muscles in individuals with chronic low back pain[16-18].

Sonoelastography which assesses the stiffness of tissues can be performed by US-integrated techniques such as strain elastography and shear-wave elastography (SWE)[19]. The stiffness of tissues can be evaluated by measuring the velocities of shear waves created in soft tissues with the SWE technique[20]. There are various studies examining multifidus muscle stiffness in patients with low back pain using the SWE method[21-23]. To the best of our knowledge, there is only one study evaluating multifidus muscle stiffness and fatty infiltration of lumbar multifidus muscle in the same case group[24].

The primary purpose of this study was to assess whether either technique showed a significant difference between patients with chronic low back pain and control subjects. The secondary purpose of this study was to evaluate the feasibility of the SWE technique in the evaluation of multifidus muscle stiffness as a representative of muscle fatty infiltration, using CSE MRI as a non-invasive quantitative method. In addition, it is aimed to reveal whether fatty infiltration of multifidus muscle can be predicted by SWE measurements by investigating whether there is a correlation between MRI signal index and SWE measurement values in patients with chronic low back pain.

Methods

Study population

Adult patients aged 18-60 years, with chronic low back pain for more than 3 months, who were referred to a tertiary academic center for lumbar MRI examination between September 2020 and April 2021 were prospectively enrolled in this study (n = 305).

Individuals with a history of spinal surgery, any congenital orthopedic pathology other than low back pain, trauma, systemic inflammatory disease, advanced osteodegenerative changes (such as central canal stenosis and nerve root compression), spinal infection, neurological or neoplastic disease, and pregnant women were excluded from the study (Fig. 1). The final patient group consisted of 48 patients with chronic low back pain, 27 were female, and 21 were male, aged 22-59 years. A total of 38 normal control subjects 18 women and 20 men, aged 21-59 years, who did not have low back pain were performed lumbar MRI and did not have the features specified in the exclusion criteria in their history were included. Informed consent was obtained from all participating individuals.

Imaging techniques and image analysis

A 1.5 T MRI scanner (Philips Ingenia, Best, The Netherlands) was used for routine lumbar spinal image acquisition in all participants. In the sagittal plane, T1-weighted images (repetition time [TR]: 430 ms, echo time [TE]: 12 ms, thickness 4 mm, interslice gap 0.4 mm, matrix 240/384r, field of view [FOV] 300 mm, turbo factor [TF] 4, EPI factor 1, and NEX 2) and T2-weighted images (TR: 3000 ms, TE: 120 ms, thickness 4 mm, interslice gap 0.4 mm, matrix 240/384r, FOV 300 mm, TF 17, EPI factor 1, and NEX 2) were obtained. In the axial plane, T2-weighted GRE images (B-FFE) were obtained (TR: 9.6 ms, TE: 4.8 ms, thickness 4 mm, interslice gap 0.4 mm, matrix 148/240r, FOV 160 mm, flip angle (FA) 45°, TF 1, EPI factor 1, and NEX 2). In the control and patient groups who met the criteria, axial images were obtained from the L2-3 and L4-5 levels using an opposed-phase MRI technique, two-point DIXON (mDIXON) sequence

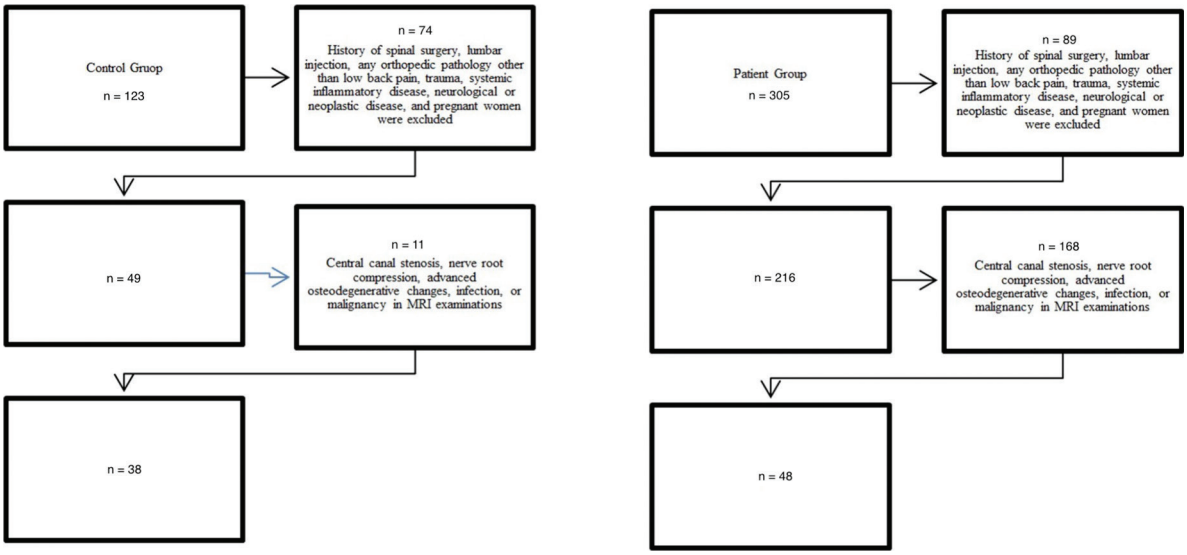

Figure 1. *Flow chart as process illustration for case accumulation and exclusion as performed in this work.*

(TR:5.8 ms, double TE:4.7 ve 2.4 ms, FA 15°, slice thickness 5 mm, interslice gap-2.5 mm, matrix 189/336r, and FOV 400 mm). In-phase and opposed-phase images were obtained from the same anatomical position, and signal intensity (SI) measurements were made at the workstation at both levels. SI measurements were performed with a circular region of interest (ROI) which was manually placed on the central part of the multifidus muscle. Air in the superficial proximity of skin was chosen as a reference region and measurements with the same sized ROI as in the muscle were obtained. Each measurement was acquired 3 times in a single session by the same 5th-year radiology resident. SI index (SII) and SI suppression ratio (SISR) parameters were calculated according to the following formulas using SI values obtained from in and opposed-phase images, as defined in previous articles[17,25];

– The percentage of change in SI of the multifidus muscle:

SII = ([In-phase SI multifidus – Opposed-phase SI multifidus]/[in-phase SI]) × 100

– The percentage of change in SI rate of the multifidus muscle compared with air:

SISR = ([Opposed-phase (SI multifidus/SI air)/In-phase (SI multifidus/SI air)]–1) × 100

Sonoelastography of lumbar multifidus muscles of participants from control and patient groups was performed by a SWE-capable Acuson S2000 US device (Siemens Healthcare, Erlangen, Germany). A 1-6 Mhz broadband convex transducer was used to reduce image noise and provide deep tissue penetration. The same operator performed all ultrasound examinations. Participants were placed in the prone position, and a folded towel was placed under their abdomen to reduce lumbar lordosis. Vertebral levels were defined by sonographic determination of the 12th rib level. Shear wave velocity (SWV) measurements were made in the sagittal plane, at the same anatomical level and side as MRI measurements; approximately 2 cm right side to the midline and parallel to muscle fibers, with the transducer positioned about 10° medialized, without applying any pressure to the probe. SWV measurements were acquired with a ROI of 0.5 cm × 0.6 cm by placing into multifidus muscle from a maximum depth of 5.5 cm. The minimum and maximum SWV values of seven measurements from each examination area were eliminated, and the arithmetic average of the five values was recorded in m/s.

Statistical analysis

Statistical analysis of the obtained data was performed using SPSS for Windows, version 22.0 (IBM Corp, NY, USA). Conformity to the normal distribution of SII, SISR, and SWV values of multifidus muscles at L2-3 and L4-5 levels and other variables were evaluated using analytical methods (Kolmogorov–Smirnov/Shapiro-Wilk tests). The correlation relations between the variables measured at both levels were evaluated

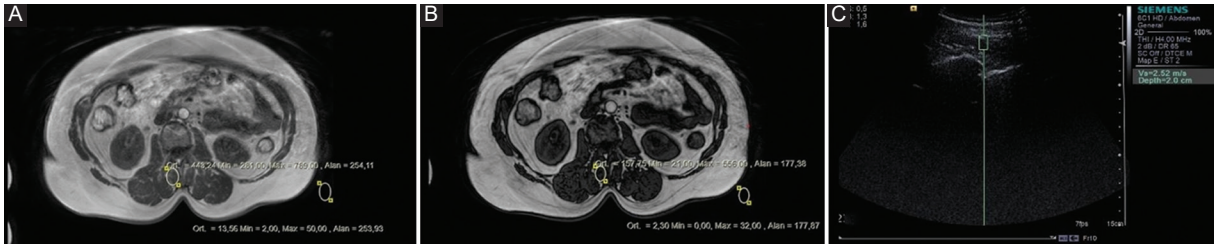

Figure 2. *A 53-year-old female with low back pain.* **A:** *in-phase and* **B:** *opposed-phase images. At the L2-3 level, the SII value and the SISR value are 100.31 and 64.55, respectively.* **C:** *SWV measurement in the multifidus muscle at the same level. The SWV value is 2.52 m/s.*
SII: signal intensity index; SISR: signal intensity suppression rate; SWV: shear wave velocity; **(A-B)** *Ort: mean signal intensity; Min: minimum signal intensity; Max: maximum signal intensity; Alan: Area;* **(C)** *Vs: shear wave velocity.*

by Pearson's correlation test for variables with normal distribution. Group differences for SII, SISR, and SWV values of the multifidus muscles at L2-3 and L4-5 levels were compared using Student's t-test. Cases with a type-1 error level below 5% were interpreted as statistically significant. To investigate intrareader agreement, intraclass correlation coefficients (ICCs) were computed.

Results

The mean age of the control group was 36.16, and the chronic low back pain patient group was 41.79 ($p = 0.019$).

According to the formula, we used in the CSE MRI technique, the semi-quantitative SISR value decreases as the fatty infiltration of the multifidus muscle gradually increases. In the in-phase and out-phase sequences, the fat SI is suppressed, and a higher SII value is obtained according to the formula. In the SWE technique, as the stiffness of tissue decreases, there is a decrease in the SWV value (Figs. 2 and 3). ICCs for SWV, SISR, and SII were 0.73-0.90, 0.80-0.92, and 0.85-0.90, supporting the reproducibility of measurements.

The mean SII and SISR index values obtained from multifidus muscles at L2-3 and L4-5 levels in the control and patient groups by opposed-phase MRI and the mean SWV values measured by SWE from the same levels are given in table 1. There was no statistically significant difference between the control and patient groups regarding SWV, SII, and SISR mean values at L2-3 and L4-5 levels ($p > 0.05$). The correlation between age and multifidus muscle SII, SISR, and SWV values at L2-3 and L4-5 levels in the patient group is shown in table 2. A statistically significant correlation was found between age, and SWV, SII, and SISR values of multifidus muscles at the L2-3 level. As patient age increases, multifidus muscle stiffness decreases, and at MRI, whereas SII increases, SISR decreases, indicating fatty infiltration of the muscle (Fig. 4). At the L4-5 level, no significant correlation between patient age and SWV and SII-SISR index values was noticed.

There was a significant negative correlation between SWV and SII ($r = -0.317$, $p = 0.028$) and a significant positive correlation between SWV and SISR ($r = 0.336$, $p = 0.019$). In other words, as the muscle stiffness decreased, the SII value increased, and the SISR value decreased, indicating fatty infiltration (Fig. 5). No significant correlation was found between SWV and SII ($r = 0.227$, $p = 0.178$) and between SWV and SISR values ($r = -0.174$, $p = 0.236$) for L4-5 level (Table 3).

Discussion

In our study, no statistically significant multifidus muscle stiffness expressing difference was found between the control group and the patient group with low back pain in terms of SWV mean values at L2-3 and L4-5 levels. This result is different from previous studies with the SWE[21-23]. No significant difference was found between the control and patient groups in terms of SWV and signal index values (SII-SISR). In other words, the lack of statistically significant difference between the control and patient groups in SWV values may be due to the similarity of fatty infiltration levels of multifidus muscles in the control and patient groups. It has previously been reported that the multifidus muscle in patients with low back pain was more rigid than the control group, assessed by the SWE method in the prone position and passive state. It has been suggested that this may be caused by increased tonicity, spasm, and fibrotic changes in the multifidus muscle[21,23,26]. Alis et al. reported a significant decrease in

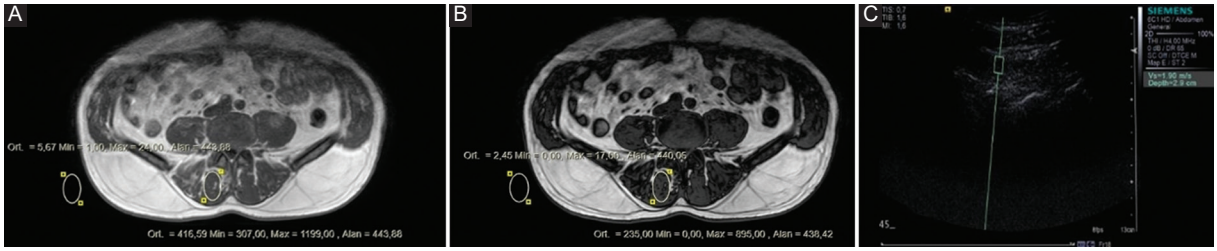

Figure 3. *A 50-year-old male with low back pain.* **A:** *in-phase and* **B:** *opposed-phase images. At the L4-5 level, the SII value and the SISR value are 43.51 and 30.54, respectively.* **C:** *SWV measurement in the multifidus muscle at the same level. The SWV value was 1.90 m/s.*
SII: signal intensity index; SISR: signal intensity suppression rate; SWV: shear wave velocity; **(A-B)** *Ort: mean signal intensity; Min: minimum signal intensity; Max: maximum signal intensity; Alan: Area;* **(C)** *Vs: shear wave velocity.*

Table 1. SWV, SII, and SISR values in the control group and in the patient group

Levels and measurements	Control group mean (± SD)	Patient group mean (± SD)	p*
L2-3 level multifidus muscle			
SWV	2.81 (± 0.82)	2.68 (± 0.88)	0.474
SII	31.93 (± 11.51)	33.23 (± 13.88)	0.640
SISR	101.68 (± 73.53)	87.98 (± 72.63)	0.391
L4-5 level multifidus muscle			
SWV	2.76 (± 0.71)	2.52 (± 0.57)	0.097
SII	35.19 (± 12.99)	33.38 (± 10.89)	0.493
SISR	118.18 (± 70.9)	94.87 (± 74.41)	0.147

*Statistically significant P<0.05. SD: standard deviation; SWV: shear wave velocity; SII: signal intensity index; SISR: signal intensity suppression ratio.

Table 2. Correlation results among age and SWV, SII, and SISR values at the L2-3 and L4-5 levels in the patient group

Parameters	L2-3 multifidus muscle		L4-5 multifidus muscle	
	r*	p**	r*	p**
Age - SWV	−0.305	0.035	−0.228	0.118
Age - SII	0.470	0.001	0.275	0.059
Age - SISR	−0.302	0.037	−0.059	0.692

* r: Pearson correlation coefficient. **Statistically significant p < 0.05. SWV: shear wave velocity; SII: signal intensity index; SISR: signal intensity suppression ratio.

Table 3. Correlation results between SWV and SII values and between SWV and SISR values at the L2-3 and L4-5 levels in the patient group

Levels	SWV-SII		SWV-SISR	
	r*	p**	r*	p**
L2-3 level	−0.317	0.028	0.336	0.019
L4-5 level	0.178	0.227	−0.174	0.236

*r: Pearson correlation coefficient. **statistically significant p < 0.05. SWV: shear wave velocity; SII: signal intensity index; SISR: signal intensity suppression ratio.

the multifidus muscle stiffness at SWE on the same side and at one lower vertebral level in patients with lumbar disc hernia[22]. They suggested that this result may be due to the fatty infiltration of the multifidus muscle. In another study evaluating the stiffness of the lumbar multifidus muscles in patients with chronic low back pain using the strain elastography method and the degree of fatty infiltration was assessed with the B-mode US images, no statistically significant difference was observed between the patients with chronic low back pain and the control group participants in terms of multifidus muscle stiffness in the passive resting state[24]. It has been stated that these different study results may be due to the usage of different sonoelastography methods[21,23]. Since the strain elastography technique is reported to be a user-dependent method, and it's difficult to obtain accurate results, it has been indicated that quantitative results can be achieved with the SWE method, which is a less user-dependent technique[21,23].

It has been previously emphasized in various studies that muscular fatty infiltration may increase depending on age[27-30]. In our study, a decrease in muscle stiffness and an increase in fatty infiltration with increasing age at L2-3 level in the patient group were observed to support this statement. However, no

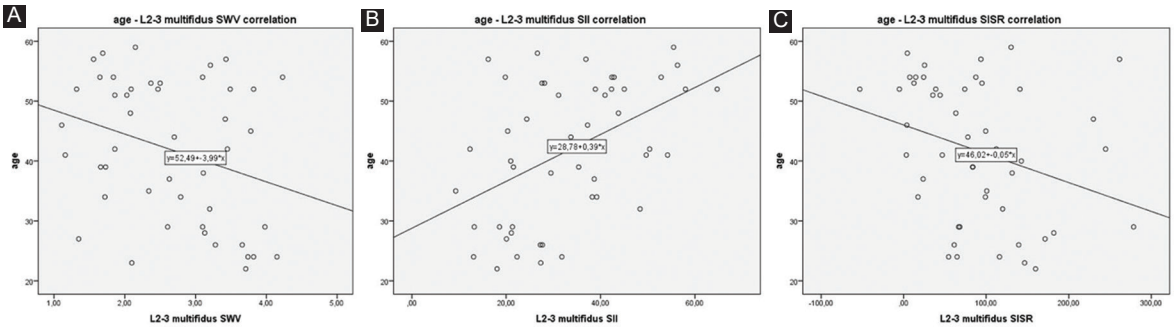

Figure 4. *Point distribution graphics of the L2-3 level.* **A:** *age-SWV,* **B:** *age-SII, and* **C:** *age-SISR correlations have been shown. SII: signal intensity index. SISR: signal intensity suppression rate. SWV: shear wave velocity.*

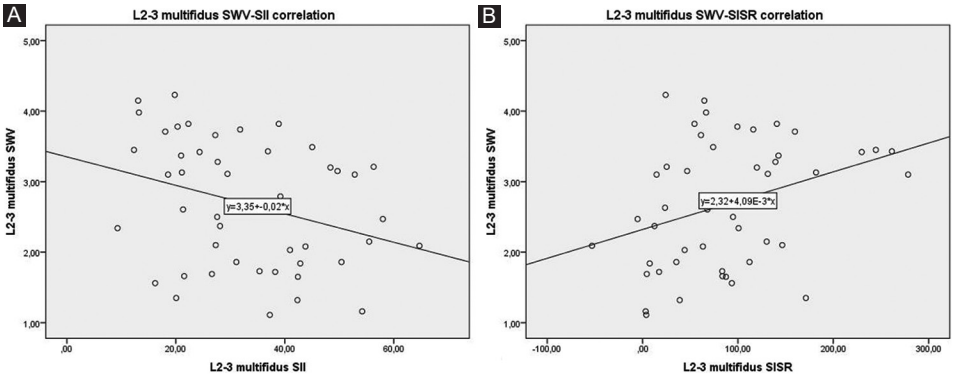

Figure 5. A: *SWV-SII.* **B:** *SWV-SISR point distribution graphics. Correlations of the L2-3 level have been demonstrated. SII: signal intensity index; SISR: signal intensity suppression rate; SWV: shear wave velocity.*

statistically significant correlation was found between age and these parameters at the L4-5 level in the patient group. It was thought that this situation might be due to accompanying fibrotic changes in the muscle, as previously reported in the literature[31,32]. Besides, it might have an adverse effect on the ultrasound waves in the thicker thoracolumbar fascia and subcutaneous fat layer in the caudal part at the L4-5 level[33].

To our knowledge, there is no other study examining the stiffness of multifidus muscles with SWE technique and the muscle fatty infiltration with CSE MRI in the literature. In our study, a correlation was found between SWV values and signals index values indicating that muscle stiffness decreases as fatty infiltration increases in multifidus muscle at the L2-3 level in patients with chronic low back pain. This result is consistent with the knowledge that less rigid sonoelastography values can be detected in muscle tissues with fatty infiltration[31,34]. Our results suggest that SWE may be a promising technique as an alternative method to MRI in detecting muscle fatty infiltration. However, no correlation was found between SWV measurements and CSE MRI signal index values at the L4-5 level. Similarly no statistical correlation between age and these measurement values. This statistical non-significant correlation at the lower lumbar level may be caused by similar factors. One of these factors may be the complex pathophysiological changes at the lower lumbar levels. It has been reported in various studies that different degenerative pathologies such as disc pathologies, spinal stenosis, and spondylolisthesis may cause more intense degeneration in multifidus muscles at lower lumbar vertebral levels[13,35,36]. However, in this study, these pathologies were exclusion criteria. Besides, it has been stated that fibrotic changes also play a role in multifidus muscle degeneration, as this situation causes an increase in stiffness in muscle fibers and bundles and fibrotic proliferation in the connective tissue. This situation can be seen as increased muscle stiffness in sonoelastographic examination[31,32]. It is thought that

another factor that could cause the lack of a statistical correlation between the measurement values at the lower lumbar level could be the lack of a complete methodological standard for sonoelastography examination[21,23,26,37]. There is a large data pool in the literature consisting of different results obtained from various levels and postures in the sonoelastography examination of posterior paraspinal muscles[21,23,26,37]. It is stated that the image is noisier, especially at the L4-5 level, due to the deeper location of the muscle, and a low-frequency transducer is needed. For this reason, we tried to overcome this problem using a low-frequency convex transducer. Moreover, finally, another factor might be the posterior layer of the thoracolumbar fascia which is thicker in the caudal part at the L4-5 level and strongly attenuates ultrasound waves[33].

Our study has some limitations. First, there were the limited number of patients in our control and study groups. Second, since there is no consensus about how to perform the SWE examination of multifidus muscles, our study was based on some application examples in the literature[21,23,26]. Third, our study did not include the participants' body mass index (BMI) values. However, there are studies in the literature reporting no relationship between the fatty infiltration of multifidus muscle and BMI[38,39]. Finally, our study is not supported by the fat fraction measurement, MR spectroscopy data, or histopathological data, which is the gold standard for demonstrating fibrosis and fatty infiltration.

Conclusions

In this study, a statistically significant correlation was found between SWE-assessed muscle stiffness and MRI-assessed fatty infiltration in multifidus muscles at the L2-3 level in the chronic low back pain group but not at the L4-5 level or in control group.

These results suggest that the SWE technique, which is a more practical, easily accessible, and inexpensive method, maybe a promising radiological examination in the detection of multifidus muscle fatty infiltration in symptomatic patients for upper leaves of lumbar paravertebral muscles.

Acknowledgments

The authors would like to thank the ethics committee for the approval of this work.

Compliance with ethical standards

Ethical approval: Informed consent for the study was obtained from all human subjects. The study was approved by the Clinical Research Ethics Committee of our faculty (No. 73023407/604.01.01/37892) and all procedures followed were in accordance with the World Medical Association Declaration of Helsinki: Ethical Principles for Medical Research involving Human Subjects, 2013.

Funding

The authors declare that they have not received funding.

Conflicts of interest

The authors declare no conflicts of interest.

Ethical disclosures

Protection of human and animal subjects. The authors declare that no experiments were performed on humans or animals for this study.

Confidentiality of data. The authors declare that they have followed the protocols of their work center on the publication of patient data.

Right to privacy and informed consent. The authors have obtained approval from the ethics committee for analysis and publication of routinely acquired clinical data and informed consent was not required for this retrospective observational study.

Use of artificial intelligence for generating text. The authors declare that they have not used any type of generative artificial intelligence for the writing of this manuscript nor for the creation of images, graphics, tables, or their corresponding captions.

References

1. Kaplan W, Wirtz V, Mantel A, Béatrice PS. Priority medicines for Europe and the world update 2013 report. Methodology. 2013;2:99-102.
2. Parkkola R, Rytökoski U, Kormano M. Magnetic resonance imaging of the discs and trunk muscles in patients with chronic low back pain and healthy control subjects. Spine (Phila Pa 1976). 1993;18:830-6.
3. Kjaer P, Bendix T, Sorensen JS, Korsholm L, Leboeuf-Yde C. Are MRI-defined fat infiltrations in the multifidus muscles associated with low back pain? BMC Med. 2007;5:1-10.
4. Sollmann N, Bonnheim NB, Joseph GB, Chachad R, Zhou J, Akkaya Z, et al. Paraspinal muscle in chronic low back pain: comparison between standard parameters and chemical shift encoding-based water-fat MRI. J Magn Reson Imaging. 2022;56:1600-8.
5. Woodham M, Woodham A, Skeate JG, Freeman M. Long-term lumbar multifidus muscle atrophy changes documented with magnetic resonance imaging: a case series. J Radiol Case Rep. 2014;8:27.

6. Hebert JJ, Le Cara EC, Koppenhaver SL, Hoffman MD, Marcus RL, Dempsey AR, et al. Predictors of clinical success with stabilization exercise are associated with lower levels of lumbar multifidus intramuscular adipose tissue in patients with low back pain. Disabil Rehabil. 2020;42:679-84.
7. Osorio W, Ceballos C, Moyano J. Effectiveness of acute post-operative pain management by the acute pain service. Cir Cir. 2022;90:197-201.
8. Jermy JE, Copley PC, Poon MT, Demetriades AK. Does pre-operative multifidus morphology on MRI predict clinical outcomes in adults following surgical treatment for degenerative lumbar spine disease? A systematic review. Eur Spine J. 2020;29:1318-27.
9. Flicker PL, Fleckenstein JL, Ferry K, Payne J, Ward C, Mayer T, et al. Lumbar muscle usage in chronic low back pain. Magnetic resonance image evaluation. Spine (Phila Pa 1976). 1993;18:582-6.
10. Hides JA, Stokes MJ, Saide M, Jull GA, Cooper DH. Evidence of lumbar multifidus muscle wasting ipsilateral to symptoms in patients with acute/subacute low back pain. Spine (Phila Pa 1976). 1994;19:165-72.
11. Keller A, Brox JI, Gunderson R, Holm I, Friis A, Reikeras O. Trunk muscle strength, cross-sectional area, and density in patients with chronic lowback pain randomized to lumbar fusion or cognitive intervention and exercises. Spine (Phila Pa 1976). 2004;29:3-8.
12. Hicks GE, Simonsick EM, Harris TB, Newman AB, Weiner DK, Nevitt MA, et al. Cross-sectional associations between trunk muscle composition, back pain, and physical function in the health, aging, and body composition study. J Gerontol A Biol Sci Med Sci. 2005;60:882-7.
13. Kalichman L, Carmeli E, Been E. The association between imaging parameters of the paraspinal muscles, spinal degeneration, and low back pain. Biomed Res Int. 2017;2017:2562957.
14. Takashima H, Takebayashi T, Ogon I, Yoshimoto M, Morita T, Umamura R, et al. Analysis of intra and extramyocellular lipids in the multifidus muscle in patients with chronic low back pain using MR spectroscopy. Br J Radiol. 2018;91:20170536.
15. Han G, Jiang Y, Zhang B, Gong C, Li W. Imaging evaluation of fat infiltration in paraspinal muscles on MRI: a systematic review with a focus on methodology. Orthop Surg. 2021;13:1141-8.
16. Paalanne N, Niinimäki J, Karppinen J, Taimela S, Mutanen P, Takatalo J, et al. Assessment of association between low back pain and paraspinal muscle atrophy using opposed-phase magnetic resonance imaging: a population-based study among young adults. Spine (Phila Pa 1976). 2011;36:1961-8.
17. Yanik B, Keyik B, Conkbayir I. Fatty degeneration of multifidus muscle in patients with chronic low back pain and in asymptomatic volunteers: quantification with chemical shift magnetic resonance imaging. Skeletal Radiol. 2013;42:771-8.
18. Schlaeger S, Inhuber S, Rohrmeier A, Deickmeyer M, Freitag F, Klupp E, et al. Association of paraspinal muscle water-fat MRI-based measurements with isometric strength measurements. Eur Radiol. 2019;29:599-608.
19. Lee SK, Jung JY, Kang YR, Jung JH, Yang JJ. Fat quantification of multifidus muscle using T2-weighted Dixon: which measurement methods are best suited for revealing the relationship between fat infiltration and herniated nucleus pulposus. Skeletal Radiol. 2020;49:263-71.
20. Hug F, Hodges PW, Tucker K. Muscle force cannot be directly inferred from muscle activation: illustrated by the proposed imbalance of force between the vastus medialis and vastus lateralis in people with patellofemoral pain. J Orthop Sports Phys Ther. 2015;45:360-5.
21. Masaki M, Aoyama T, Murakami T, Yanase K, Ji X, Tatehuchi H, et al. Association of low back pain with muscle stiffness and muscle mass of the lumbar back muscles, and sagittal spinal alignment in young and middle-aged medical workers. Clin Biomech (Bristol, Avon). 2017;49:128-33.
22. Alis D, Durmaz ES, Alis C, Erol BC, Okur B, Kizilkilic O, et al. Shear wave elastography of the lumbar multifidus muscle in patients with unilateral lumbar disk herniation. J Ultrasound Med. 2019;38:1695-703.
23. Murillo C, Falla D, Rushton A, Sanderson A, Heneghan NR. Shear wave elastography investigation of multifidus stiffness in individuals with low back pain. J Electromyogr Kinesiol. 2019;47:19-24.
24. Chan ST, Fung PK, Ng NY, Ngan TL, Chong MY, Tang CN, et al. Dynamic changes of elasticity, cross-sectional area, and fat infiltration of multifidus at different postures in men with chronic low back pain. Spine J. 2012;12:381-8.
25. Gokalp G, Yildirim N, Yazici Z, Ercan I. Using chemical-shift MR imaging to quantify fatty degeneration within supraspinatus muscle due to supraspinatus tendon injuries. Skeletal Radiol. 2010;39:1211-7.
26. Koppenhaver S, Gaffney E, Oates A, Eberle L, Young B, Hebert J, et al. Lumbar muscle stiffness is different in individuals with low back pain than asymptomatic controls and is associated with pain and disability, but not common physical examination findings. Musculoskelet Sci Pract. 2020;45:102078.
27. Hadar H, Gadoth N, Heifetz M. Fatty replacement of lower paraspinal muscles: normal and neuromuscular disorders. AJR Am J Roentgenol. 1983;141:895-8.
28. Hebert JJ, Kjaer P, Fritz JM, Walker BF. The relationship of lumbar multifidus muscle morphology to previous, current, and future low back pain: a 9-year population-based prospective cohort study. Spine (Phila Pa 1976). 2014;39:1417-25.
29. Lee SH, Park SW, Kim YB, Nam TK, Lee YS. The fatty degeneration of lumbar paraspinal muscles on computed tomography scan according to age and disc level. Spine J. 2017;17:81-7.
30. Mackintosh S, Young A, Muirhead J, Lee A, Sim JH. A pilot study: can shear wave elastography predict fatty infiltration of the supraspinatus muscle? Sonography. 2020;7:97-109.
31. Brown SH, Gregory DE, Carr JA, Ward SR, Masuda K, Lieber RL. ISSLS prize winner: adaptations to the multifidus muscle in response to experimentally induced intervertebral disc degeneration. Spine. 2011;36:1728-36.
32. Brown E, Yoshitake Y, Shinohara M, Ueda J. Automatic analysis of ultrasound shear-wave elastography in skeletal muscle without non-contractile tissue contamination. Int J Intell Robot Appl. 2018;2:209-25.
33. Moreau B, Vergari C, Gad H, Sandoz B, Skalli W, Laporte S. Non-invasive assessment of human multifidus muscle stiffness using ultrasound shear wave elastography: a feasibility study. Proc Inst Mech Eng H. 2016;230:809-14.
34. Koppenhaver SL, Scutella D, Sorrell BA, Yahalom J, Fernández-de-Las-Peñas C, Childs JD, et al. Normative parameters and anthropometric variability of lumbar muscle stiffness using ultrasound shear-wave elastography. Clin Biomech (Bristol, Avon). 2019;62:113-20.
35. Albert HB, Briggs AM, Kent P, Byrhagen A, Hansen C, Kjaergaard K. The prevalence of MRI-defined spinal pathoanatomies and their association with modic changes in individuals seeking care for low back pain. Eur Spine J. 2011;20:1355-62.
36. Hodges PW, Danneels L. Changes in structure and function of the back muscles in low back pain: different time points, observations, and mechanisms. J Orthop Sports Phys Ther. 2019;49:464-76.
37. Ma CZ, Ren LJ, Cheng CL, Zheng YP. Mapping of back muscle stiffness along spine during standing and lying in young adults: a pilot study on spinal stiffness quantification with ultrasound imaging. Sensors. 2020;20:7317.
38. Mengiardi B, Schmid MR, Boos N, Pfirrmann CWA, Brunner F, Elfering A, et al. Fat content of lumbar paraspinal muscles in patients with chronic low back pain and in asymptomatic volunteers: quantification with MR spectroscopy. Radiology. 2006;240:786-92.
39. Shapiro L, Harish M, Hargreaves B, Staroswiecki E, Gold G. Advances in musculoskeletal MRI: technical considerations. J Magn Reson Imaging. 2012;36:775-87.