Check for updates

CASO CLÍNICO

Calcified clumped neodymium magnetic spheres as an intravesical foreign body: case report and literature review

Esferas magnéticas de neodimio agrupadas calcificadas como un cuerpo extraño intravesical: reporte de un caso y revisión de la literatura

İbrahim Üntan[1] and Volkan Sabur[2]*

[1]Department of Urology, Ahi Evran University, Training and Research Hospital, Kirsehir; [2]Department of Urology, Erciyes Kartal Hospital, Kayseri. Turkey

Abstract

Foreign bodies in the bladder can occur by self-insertion, and patients often hide the symptoms owing to embarrassment. The foreign bodies act as a nidus for calculus formation when not detected for a long time. Foreign bodies can declare symptoms such as frequency, dysuria, nocturia, hematuria, urethrorrhagia, obstruction, or retention. This case spotlights self-inserted intravesical neodymium magnetic spheres clumped and calcified due to delayed presentation which were removed by open cystotomy after a cystoscopic failure.

Keywords: *Exploratory behavior. Foreign bodies. Magnets. Neodymium. Urinary bladder.*

Resumen

Los cuerpos extraños en la vejiga pueden ocurrir por autoinserción y los pacientes a menudo ocultan los síntomas por vergüenza. Los cuerpos extraños actúan como un nido para la formación de cálculos cuando no se detectan durante mucho tiempo. Los cuerpos extraños pueden manifestar síntomas como polaquiuria, disuria, nicturia, hematuria, uretrorragia, obstrucción o retención. Este caso destaca esferas magnéticas de neodimio intravesicales autoinsertadas, agrupadas y calcificadas debido a una presentación tardía que se extrajeron mediante cistotomía abierta después de una falla cistoscópica.

Palabras clave: *Adolescente. Comportamiento exploratorio. Cuerpos extraños. Imanes. Neodimio. Vejiga urinaria.*

***Correspondence:**
İbrahim Üntan
E-mail: ibrahimuntan@erciyes.edu.tr

Date of reception: 17-05-2022
Date of acceptance: 02-06-2022
DOI: 10.24875/CIRUE.M22000699

Cir Cir (Eng). 2024;92(4):526-530
Contents available at PubMed
www.cirugiaycirujanos.com

2444-0507/© 2022 Academia Mexicana de Cirugía. Published by Permanyer. This is an open access article under the terms of the CC BY-NC-ND license (http://creativecommons.org/licenses/by-nc-nd/4.0/).

Introduction

A great variety of self-inserted foreign bodies in the bladder have been described. The reason is usually eroticism or curiosity. Self-inserted foreign bodies cases in the bladder are infrequent in adolescents. Depending on the nature of the foreign body, the diagnosis and management might be challenging. Diagnosis is always difficult because the insertion is hidden. Our presentation aims to report a case of an unusual self-inserted intravesical foreign body with calcification as a first-reported complication and briefly discuss the diagnostic and therapeutic implications in this challenging situation.

Case presentation

A 15-year-old healthy male adolescent applied to a urologist immediately after seeing blood in his urine. He has also confessed to groin pain, dysuria, and foul-smelling urine for 6 months. Vital signs and physical examination were insignificant other than a mild suprapubic tenderness to palpation. Laboratory blood test results were normal. The urinary sediment showed > 80 white blood cells/μL and > 5 red blood cells/μL. X-ray, ultrasonography (USG), and computed tomography (CT) were performed, respectively (Figs. 1-3) (supplementary material 1). Cystoscopy was planned for the optimal diagnosis and treatment. Under general anesthesia, a cystoscope with a 20 Fr sheath was introduced into the urethra, and a bladder stone was identified in the bladder trigone. After the holmium laser process was started, as the superficial stone layer was removed, a deeply colored core consisting of spheres appeared (Fig. 4) (supplementary material 2).. The superficial stone layer was easily fragmented, but the colorful inner layer was resistant, even though fragmented, the pieces were being reunited. The fragments of the outer stone layer were cleared through the cystoscope, but since the beads and metallic fragments were not split due to the magnetic attraction, withdrawal through the cystoscope or using forceps was impossible. Hence, a small cystotomy was performed through a Pfannenstiel incision, and all the 64 magnetic spheres were removed, some of which were partially fragmented by holmium laser, and the bladder was cleared completely (Fig. 5). The patient's course in the post-operative period was stable. A preliminary psychological evaluation was administered on the 1st post-operative day. The patient volunteered his story about the magnetic spheres; 9 months ago, out of curiosity, he had sent one sphere through the urethra and used the second one to pick the first one up, thus inserting all 64 beads into the urethra. On the 3rd postoperative day, the drain was removed, and the patient was discharged with a urethral catheter. The catheter was removed on the 1-week follow-up after a cystogram was performed which revealed neither leakage nor any residual contrast (supplementary material 3). The patient recovered without complications.

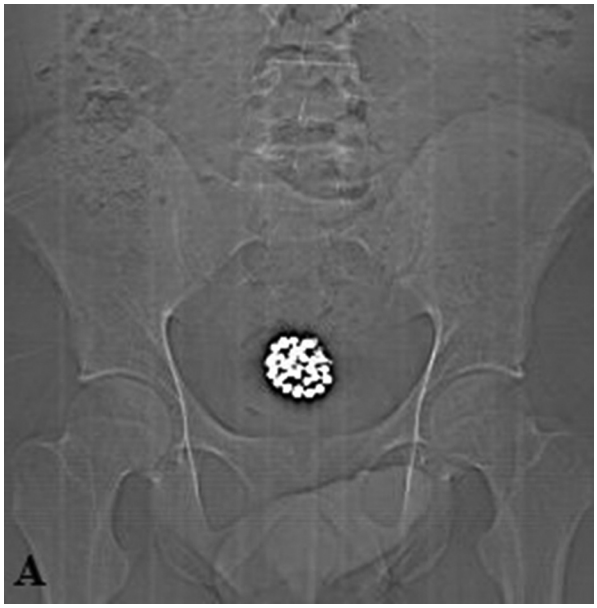

Figure 1. *X-ray of pelvis demonstrating metallic balls in the bladder region.*

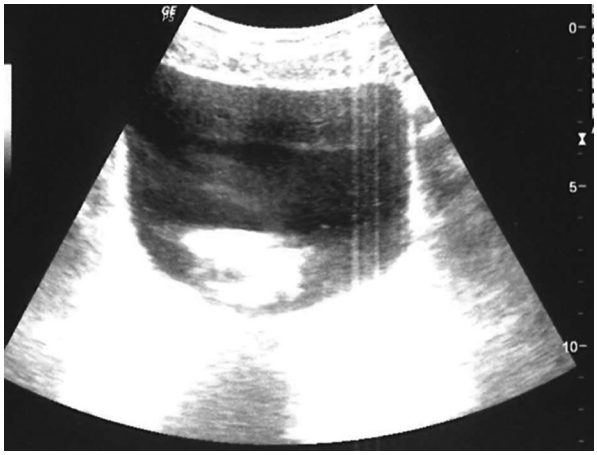

Figure 2. *Ultrasonography reporting a stone of 35 mm × 39 mm and emphasizing a strong acoustic shadow.*

Table 1. Self-inserted magnetic spheres cases in the available literature are listed in the table. Cases are always male, usually without psychiatric disorders, on their first attempt, confessing the self-insertion and used spheres 5-mm in diameter. Exceptional information is given in the symptoms column

Author	Age	Symptoms (additional information, if any)	#	Retrieval method
Gurpriya et al. [3]	19	Dysuria, inability to pass urine	51	Extraperitoneal laparoscopy after a cystoscopic failure
Alyami et al. [7]	19	Dysuria, voiding difficulty (with documented psychiatric illness)		Cystotomy after a cystoscopic failure
Brooks et al. [11]	26	Dysuria, decreased urinary output for three days,	42	Cystoscopy using basket and three-pronged grasper
Ellimoottil et al. [5]	11	Acute onset of gross hematuria and difficulty voiding	24	Cystoscopy using basket and grasper
Graziottin et al. [14]	22	Urethral bleeding and dysuria (with panic disorder)	29	Cystoscopy using forceps
Hedgepeth[15]	23	Urgency, frequency, hematuria	62	Cystotomy after a cystoscopic failure
Levine and Evans[16]	42	Applied with confessing the insertion	18	Cystotomy after a cystoscopic failure
	43	Applied with confessing the insertion	55	Cystotomy after a cystoscopic failure
	30	Urinary retention (has previous insertion history)	50	First-line cystotomy
Song et al. [9]	41	Hematuria, urinary retention, dysuria	82	Cystoscopy using grasper
Pieretti[4]	16	Mild hematuria	25	Cystotomy after a cystoscopic failure
Robey et al. [17]	12	Applied with confessing the insertion	30	Percutaneous cystostomy due to cystoscopy is time-demanding
Zeng et al. [10]	21	Gross hematuria, frequency, acute lower abdominal pain (has previous insertion history) (3-mm diameter spheres)	125	Cystoscopy using a self-invented magnetic sheath
Li et al. [2]	50	Lower abdominal pain dysuria	57	Cystoscopy
Gibson et al. [6]	11	New onset hematuria (with attention hyperactivity disorder)	16	Cystotomy after a cystoscopic failure
	18	Dysuria, gross hematuria (with autism spectrum disorder)	52	Cystotomy after a cystoscopic failure
Lindsay[12]	18	Applied with confessing the insertion	60	Cystoscopy using grasper
Liu et al. [13]	28	Applied with confessing the insertion	159	Nephroscope and its forceps through the cystoscope
Tang and Tsai[8]	17	Gross hematuria, frequency, dysuria (never confessed the insertion)	74	Cystoscopy using grasper
Zhang et al. [1]	11	Lower abdominal pain, urethral bleeding, dysuria	38	Pneumovesicoscopy after a cystoscopic failure

#number of the magnetic spheres.

Discussion

Intravesical foreign bodies are not rare cases[1]. Ingress of foreign bodies into the bladder may be by self-insertion, migration from neighbor organs, traumatic, and iatrogenic[2]. A variety of intravesical foreign bodies has been documented, including thermometers, electrical wires, needles, batteries, and so on[3]. Foreign bodies also vary according to changing eras. Neodymium spheres with high magnetic power, with the smallest diameter of three millimeters, which are marketed as toys, have also recently started to appear as a foreign body in the bladder (Fig. 6)[4]. The cases documented in the available literature regarding self-inserted neodymium magnetic spheres are compiled in table 1. Self-insertion of foreign bodies is rarely seen in the childhood age[5]. Usually, they are initially sighted at the beginning of puberty[6]. The reasons for the insertion of foreign bodies into the genitourinary tract could be sexual gratification, psychiatric, accidental, curiosity, especially among children, or therapeutic[7]. Most patients delay referring to a health professional due to embarrassment causing serious short and/or long-term complications[8]. In this article, calcified magnetic

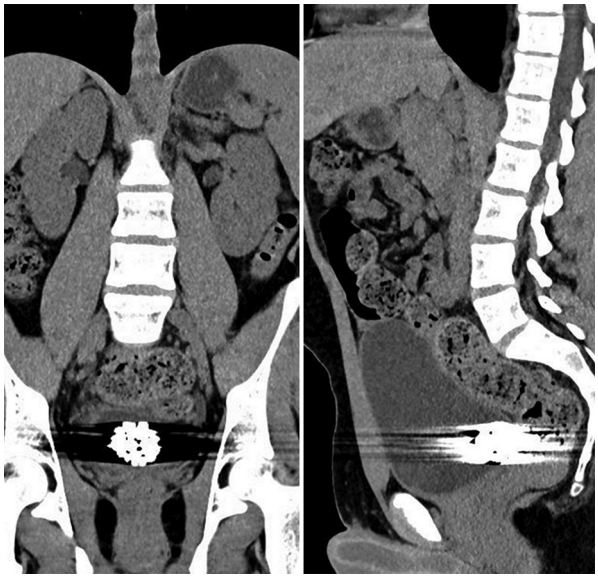

Figure 3. *Coronal and sagittal computed tomography sections revealing a 31 mm diameter globe-shaped hyperdense image in the bladder with a marked metallic artifact.*

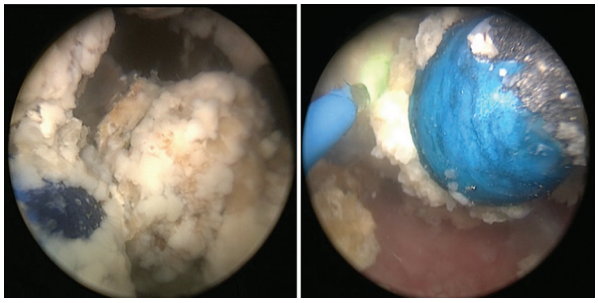

Figure 4. *Cystoscopic view of calcified magnetic ball mass and one of the magnetic balls after the calcific layer was removed peeling.*

Figure 5. *Magnetic spheres removed from the bladder by open approach.*

Figure 6. *Neodymium magnetic speheres.*

spheres were highlighted for the 1st time in the literature, due to delayed presentation. The consequences usually include symptoms such as frequency, dysuria, nocturia, hematuria, urethrorrhagia, obstruction, or retention[9]. Physical examination may reveal suprapubic tenderness and external genital organ swelling. Urinalysis may represent erythrocyturia or leukocyturia. After taking a detailed history, ideal imaging (X-ray-USG-CT) is essential in diagnosis[10]. X-ray is useful for radiopaque foreign bodies only, as the USG is helpful for both radiopaque and radiolucent foreign bodies. In our case, the uniform clustering of magnetic spheres led to the diagnosis of bladder stones with the help of stone formation in the outer layer making them appear blurred in the X-ray. Cystoscopic visualization is a precise method to verify the presence of intravesical foreign bodies[11]. In the majority of cases, cystoscopic removal is presumed optimal, usually working with balloon-wire snares, endoscopic forceps, and stone-retrieving baskets[12]. The studies that subject self-inserted and iatrogenic foreign bodies claim that cystoscopic retrieval is possible in approximately half of the cases[13]. Objects introduced through the urethra have a higher cystoscopic retrieval rate since their sizes are limited by urethral diameter[14]. Suprapubic cystostomy or open surgery may be performed unless cystoscopic intervention is successful in removing foreign bodies[15]. The up-to-date reports suggest prioritizing the open method in magnetic spheres[16]. An

immediate proper treatment option is recommended to reduce complications. One of the most common complications in delayed presented cases is stone formation since all the foreign bodies when left for long behave as a nidus for stone formation. It is suggested that a psychiatric evaluation should be recommended to discover any underlying mental health disorders, thus reducing the risk of recurrence[17].

Conclusion

The physician should keep the presence of foreign bodies in mind in patients presenting with frequency, dysuria, nocturia, and hematuria. The presentation of these cases is usually delayed due to the fear of embarrassment. Imaging techniques are crucial to identify the number, exact size, and nature of the foreign bodies. The best approach for the removal of the foreign bodies depends directly on foreign bodies' location, nature, and size and patients' age, as well as surgical expertise and accessible equipment. However, most foreign bodies can be retrieved utilizing cystoscopic techniques, according to the literature. Open surgical removal is usually reserved for those in whom cystoscopic techniques are unsuitable or have failed.

Acknowledgments

We would like to express our gratitude to Jim I. C. Onur, (CEO of Kayke, New York, NY, U. S. A.) for his valuable input on English utilization in our article.

Funding

The authors declare no funding was received.

Conflicts of interest

All authors declare that there are no conflicts of interest.

Ethical disclosures

Protection of human and animal subjects. The authors declare that no experiments were performed on humans or animals for this study.

Confidentiality of data. The authors declare that they have followed the protocols of their work center on the publication of patient data.

Right to privacy and informed consent. The authors have obtained the written informed consent of the patients or subjects mentioned in the article. The corresponding author is in possession of this document.

Supplementary data

Supplementary data are available at DOI: 10.24875/CIRUE.M22000699. These data are provided by the corresponding author and published online for the benefit of the reader. The contents of supplementary data are the sole responsibility of the authors.

References

1. Zhang K, Zhang Y, Zhang Y, Chao M. Pneumovesicoscopy: an available technique for the retrieval of a rare foreign body in the urinary bladder. Asian J Surg. 2022;45:1180-1.
2. Li YB, Gao YQ, Chen XD, Jiang S. Rare foreign body in bladder: a case report. Medicine (Baltimore). 2018;97:e0519.
3. Gurpriya K, Sarfraz A, Nabi G. Extraperitoneal laparoscopic removal of magnetic foreign bodies from urinary bladder: an option for endoscopic retrieval failure. Interv Med Appl Sci. 2011;3:220-2.
4. Pieretti RV. High-strength neodymium magnetic beads: a rare foreign body in the bladder of an adolescent. Urol Case Rep. 2014;2:145-6.
5. Ellimoottil C, Faasse MA, Lindgren BW. Endoscopic management of transurethrally inserted magnetic beads. Urology. 2013;81:e13-4.
6. Gibson E, Glaser Z, Joseph D, Dangle P. Previously banned magnets as foreign bodies in the lower urinary system: a single-institution case series and review of the literature. Clin Pediatr (Phila). 2019;58:110-3.
7. Alyami F, Himmelman J, Whelan T. A magnetic mass within the bladder. Can J Urol. 2013;20:6962-3.
8. Tang C, Tsai SW. Magnetic beads as intravesical foreign bodies. J Clin Urol. 2021;14:127-9.
9. Song JB, Tanagho YS, Haseebuddin M, Benway BM, Desai AC, Bhayani SB, *et al*.. Endoscopic management of genitourinary foreign bodies. Rev Urol. 2013;15:84-91.
10. Zeng SX, Li HZ, Zhang ZS, Lu X, Yu XW, Yang QS, et al. Removal of numerous vesical magnetic beads with a self-made magnetic sheath. J Sex Med. 2015;12:567-71.
11. Brooks T, Zreick J, Iocca A. Urinary obstruction from sexual practice involving magnetized beads inserted in the male urethra. CMAJ. 2013;185:1597-8.
12. Lindsay JS. The practice of "urethral sounding" complicated by retained magnetic beads within the bladder and urethra: diagnosis and review of management. Am J Case Rep. 2019;20:1841-4.
13. Liu ZH, Zhu XF, Zhou N. Retrieval of 159 magnetic balls from urinary bladder: a case report and literature review. Urol Case Rep. 2019;26:100975.
14. Graziottin TM, Soares DF, Da Ros CT, Sogari PR, Telöken C, Laste PR. Magnetic spheres as foreign body into the bladder. J Sex Med. 2013;10:2590-2.
15. Hedgepeth R. A novel approach to managing intravesical magnetic beads. UroToday Int J. 2013;6:art70.
16. Levine MA, Evans H. Open removal as a first-line treatment of magnetic intravesical foreign bodies. Can Urol Assoc J. 2013;7:E25-8.
17. Robey TE, Kaimakliotis HZ, Hittelman AB, Walshl SA. An unusual destination for magnetic foreign bodies. Pediatr Emerg Care. 2014;30:643-5.