Check for updates

ARTÍCULO DE REVISIÓN

Endoscopic treatment of gastroesophageal reflux disease

Tratamiento endoscópico de la enfermedad por reflujo gastroesofágico

Isaac Raijman

Department of Gastroenterology, Baylor College of Medicine, Department of Gastroenterology, Baylor St. Lukes Medical Center, Houston, Texas, United States of America

Abstract

The endoscopic treatment of gastroesophageal reflux disease (GERD) has evolved significantly in the past 20 years. Current practices include devices specifically designed for GERD. Newer techniques aim to use less extra equipment, to be less costly, and to use accessories readily available in endoscopy units, as well as using standard endoscopes to apply such techniques. It is of utmost importance to properly select the patients for endoscopic therapy, and it should be done in a multidisciplinary approach.

Keywords: *Endoscopic therapy. GERD. Gastroesophageal reflux disease.*

Resumen

El tratamiento endoscópico de la enfermedad por reflujo gastroesofágico (ERGE) ha evolucionado significativamente en los últimos 20 años. Las prácticas actuales incluyen dispositivos diseñados específicamente para la ERGE. Las técnicas más nuevas tienen como objetivo utilizar menos equipos adicionales, ser menos costosos y utilizar accesorios fácilmente disponibles en las unidades de endoscopia, así como utilizar endoscopios estándar para aplicar dichas técnicas. Es de suma importancia seleccionar adecuadamente a los pacientes para la terapia endoscópica, y debe hacerse en un enfoque multidisciplinario.

Palabras clave: *terapia endoscópica. ERGE. Enfermedad por reflujo gastroesofágico.*

Introduction

Gastroesophageal reflux disease (GERD) is a common clinical condition that can evolve into a debilitating chronic illness and be associated with complications, including the development of esophageal cancer. It is a heterogeneous condition and has been globally classified as an erosive or non-erosive disease[1]. It is increasing in prevalence and incidence worldwide (clinically defined as the presence of symptoms and complications, related to the reflux of gastric contents into the esophagus[1-3]. GERD is a common disorder that affects the quality of life and is responsible for a high resource expenditure for both patients and payors. In the US, the annual expenditure on diagnosing and treating the disease exceeds 9 billion dollars[4,5]. The increasing prevalence and incidence of GERD appear to be closely related to aging, obesity, tobacco use, certain medications such as calcium channel blockers, and tricyclic antidepressants[1-5].

GERD can occur in normal individuals without representing disease. Pathologic GERD occurs primarily due to an inappropriate transient relaxation of the lower esophageal sphincter, and this can be further

Correspondence:
Isaac Raijman
E-mail: iraijman@tddctx.com

Date of reception: 21-02-2024
Date of acceptance: 07-03-2024
DOI: 10.24875/CIRUE.M24000669

Cir Cir (Eng). 2024;92(2):269-275
Contents available at PubMed
www.cirugiaycirujanos.com

2444-0507/© 2024 Academia Mexicana de Cirugía. Published by Permanyer. This is an open access article under the terms of the CC BY-NC-ND license (http://creativecommons.org/licenses/by-nc-nd/4.0/).

enhanced by the presence of a hiatal hernia which can be associated with LES incompetence, displacement of the acid pocket closer to the esophageal mucosa as well as shortening of the esophagus[6-8]. Other contributing factors include a balance of protective factors: adequate saliva production, esophageal elimination of luminal contents, integrity of the natural antireflux barrier, acid clearance from the esophageal lumen, esophageal mucosa resistance to acid, and non-esophageal components such as degree of gastric acidity, volume of regurgitant and, in specific instances, duodenal contents[6-8].

The mainstay of treatment of GERD is symptom relief and resolution and prevention of complications. A multimodal approach is needed in all patients. The management is always started with medical therapy, including pharmacologic and non-pharmacologic interventions. Endoscopic and surgical treatments aim to improve or normalize the mechanical component of GERD. Independent of what intervention is carried out; patients require lifestyle changes including dietary habits, avoiding eating late at night or lying recumbent soon after eating, prandial postural modifications, weight loss, and tobacco abstinence. The use of proton pump inhibitors and potassium channel modifiers is the first line. Acid suppression with Proton pump inhibitor (PPI) is quite effective and easy to follow, with very good response and efficacy and limited adverse events[9]. There are patients that appear to develop a less effective response overtime and may respond to either a different PPI or changing to a potassium channel modifier. Best responders include patients with typical symptoms of GERD, whereas those with more visceral or functional components and those with extraesophageal symptoms do not fare so well. There is increased awareness in the public for potential PPI-related long-term side effects that prefer an alternative therapy. There is a subgroup of patients (approximately 40%) that may not have an appropriate response to adequate dosing and duration of therapy with PPI and are classified as refractory GERD[10,11].

In surgical anti-reflux procedures, main objectives include increasing the LES basal pressure, repair of the hiatal hernia, fixation the LES to the hiatus, augmentation the intra-abdominal segment of the esophagus, decrease the amount of gastric reflux into the esophagus, and improve esophageal clearance[12-14]. Usual indications for surgical intervention include patients not responding to appropriate trials of medications, the development of side effects, the concern of long-term use of medications and the unwillingness to do so, contraindications to PPIs, large volume refluxate, or the presence of non-responsive complications such as strictures and Barrett's esophagus. The most frequent surgical procedures performed include laparoscopic 360° fundoplication (Nissen) and partial fundoplication (Toupet), with an expected efficiency in the 90% range as well as a reduction in the use of medications, in the high 80% range[12-14]. Short-term outcomes show that approximately 10% of patients do not respond, and that increases to approximately 30% long-term, and a significant number of patients may remain on medications. Because of that, being more invasive, and the possible side effects including inability to belch, vomit, dysphagia, gas bloat, diarrhea, increased flatus, incisional hernia, and need for revision surgeries, an increasing number of patients opt for endoscopic therapies.

Endoscopic correction of GERD is not new, now spanning over 3 decades of various attempts with mixed results. Some of those therapies were designed as a definitive treatment whereas others were conceptualized as a bridge therapy between medications and definitive surgery. The appropriate selection of patients is of paramount importance for endoscopic approaches. An important determinant is the gastroesophageal flap valve (GEFV). Grading of the GEFV is according to Hill's classification[15]: Grade I: fold of tissue tightly surrounds the endoscope; Grade II: fold is prominent but there is intermittently opening and closing around the scope; Grade III: fold is not obvious and the diaphragmatic hiatus is freely open, with no or minimal sliding hiatal hernia visible; Grade IV: fold disappeared, and the diaphragmatic hiatus increased significantly, showing a well-defined sliding hiatal hernia.

Over the years, there have been endoscopic therapies that have now disappeared include the silicon prosthesis[16], endo-plication[17], and injection of bulking agents[18]. While success was reported, the long-term results were not favorable, and some were associated with increased morbidity and mortality. Endoscopic therapies now have evolved to include different forms of plication, ablation, tissue removal, and ligation. Ablative therapies include radiofrequency (Stretta), and other thermal therapies (ARMS, ARMA). Ligation therapy includes Peroral endoscopic cardial constriction with band (PECC-B). Plication therapies include MUSE, TIF-1, TIF-2, and GERD-X. Tissue removal includes mucosectomy.

The development of endoscopic techniques has gone from requiring relatively inexpensive devices,

easy to use, to requiring expensive add-on devices and technically difficult, to back to less expensive, easy-to-apply techniques that include those used for other purposes in the gastrointestinal tract. While some of these techniques are relatively new, their technical feasibility and familiarity with endoscopists make them very attractive for immediate use. There is also an impetus in combining techniques (ablative and plication) (plication and laparoscopic hiatal hernia repair) considering the various mechanisms of GERD[19] or TIF with laparoscopic HH repair[20]. The current endoscopic methods also offer benefits as a complementary intervention in reducing PPI intake and improving quality of life, especially since the causes of GERD are so variable. This makes anti-reflux endoscopy not only an alternative to PPIs but also a complementary tool that can reduce their consumption help improve quality of life, and improve the GERD-HRQL score[21,22].

Offering endoscopic therapy should be carried out equally to offering surgical intervention. At the present time, when appropriately selected, endoscopic therapies have not shown inferiority to surgery, and offer advantages including fewer complications acutely and fewer symptom side effects in the long-term, shorter procedural time, less cost, and, importantly, do not preclude future surgery if needed.

Endoscopic therapies

Ablative methods

Radiofrequency

Stretta procedure (Restech, Houston, TX, USA) uses radiofrequency energy in the muscles of the LES and in the gastric cardia to decrease gastroesophageal junction (GEJ) compliance, resulting in an improvement of reflux symptoms[22]. The Stretta catheter is advanced perorally over a guidewire and positioned 0.5 cm proximal to the GEJ, at the GEJ, and 0.5 cm below the GEJ. At each level, the balloon basket assembly is inflated, and then four nitinol needle electrodes (22-gauge, 5.5-mm) extend into the muscular layer to deliver a radiofrequency current and induce a thermal reaction. This is followed by a 45° rotation clockwise and ablation is again performed. There have been numerous studies of Stretta compared to PPI and sham controls.

The Stretta® procedure has been evaluated in numerous studies including randomized trials *vs* PPI's, sham control, and other endoscopic modalities[22-26]. Results have been equivocal, some showing short-term improvement but lacking significant improvement long-term. Results of various studies have revealed post-procedural improvement in symptoms and quality of life but no improvement in basal LES pressure and pH studies. While the procedure is safe and well-tolerated, with most of the adverse events being esophageal mucosa erosions and lacerations, mediastinitis, pneumonia, and pleural effusion. Stretta has been around for > 2 decades; yet, its long-term effects are not well established.

ARMS and ARMA

ARMS involves mucosectomy of the cardias which then develops a deep scar that strengthens the gastroesophageal junction: this can be performed using endoscopic submucosal dissection and endoscopic mucosal resection techniques. ARMA utilizes a triangular-tipped knife J connected to an electrocautery generator in a spray coagulation mode (Figs. 1A-C). Mucosal ablation is performed around the cardia after the creation of a submucosal cushion with saline and Indigo Carmine in a butterfly shape, leaving two areas of normal mucosa (approximately the width of the endoscope) to avoid stenosis[27-36]. ARMA can also be used with Argon Plasma Coagulation (Figs. 2A-C) forced mode 100W or spray coagulation 50 W, effect 2. ARMS can be performed in a 180° and 270° fashion, both showing a significant improvement in the GERD-Q and decreased use of medications at 6 and 12 months. The overall safety profile is excellent for both ARMS and ARMA, with side effects perhaps being more common with 270° ARMS, and mostly related to dysphagia from stricture formation. While the initial observation of reduction in GERD symptoms after mucosectomy for Barrett's esophagus was noted, the mechanism of action is not well known but may relate to suppression of backflow of gastric content, enhancement of the GEJ flap valve, increasing the integrated relaxation pressure and LES resting pressure and reduction of GEJ distensibility.

Both ARMS and ARMA, especially the latter, offer technical simplicity, do not require costly add-on devices, and can be performed in a standard endoscopy room. While the procedure is not standardized, most authors do not involve the esophageal mucosa, only the gastric cardia and spare 1 cm of normal mucosa along the greater and lesser curvature.

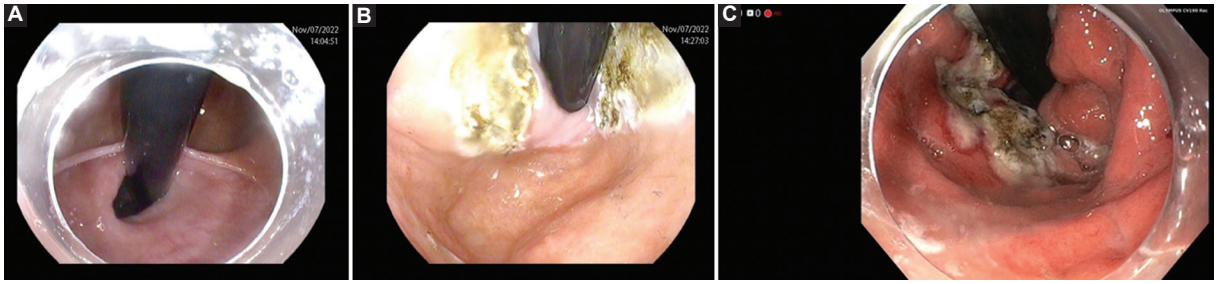

Figure 1. A: *endoscopic retrograde appearance of the cardias showing a hiatal hernia and a cap on the endoscope.* **B:** *the endoscopic image of the area ablated to the side of the cardias.* **C:** *endoscopic view of the ablated area by the cardias.*

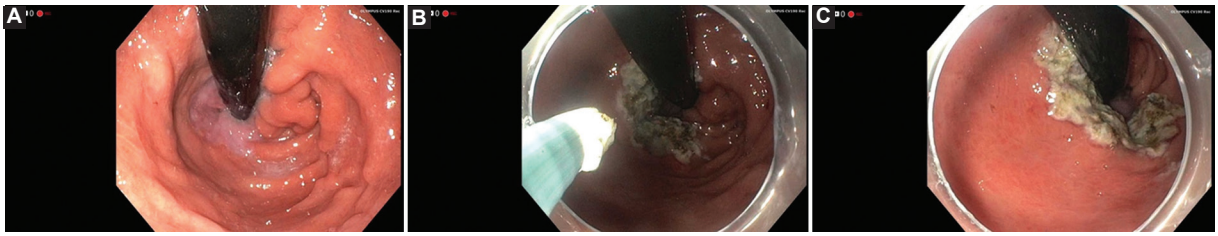

Figure 2. A: *endoscopic retrograde appearance of the cardias showing a hiatal hernia.* **B:** *the endoscopic image of the area ablated to the side of the cardias with Argon plasma coagulator.* **C:** *endoscopic view of the ablated area by the cardias.*

There have been multiple non-randomized studies with varying follow-up from 2 months to 3 years[28-34]. The clinical success varies from 60 to 100% in the short term (< 6 months) and around 75% at 3 years. The overall safety of the procedure has been high. The most common adverse event has been dysphagia (5-10%). Perforation has been the most severe adverse event (ARMS only) occurring in <2% of patients. Chest pain, odynophagia, and epigastric pain have also been reported. All studies have reported statistically significant improvement in the GERD-HRQL scores, median Hill flap grade, and pH median DeMeester score.

This procedure, especially ARMA, is very attractive considering its simplicity, familiarity with the technology, time and cost of procedure, safety, and efficacy. While randomized studies are lacking, it is a very promising technique.

Aplication

Medigus ultrasonic surgical endostapler (MUSE), Medigus, Omer, Israel is a transoral fundoplication using a video-guided surgical stapler[37-39]. It combines visual, ultrasonic, and surgical stapling capabilities into one device, which enables a single endoscopist to perform a transoral anterior fundoplication. This flexible surgical endostapler resembles an endoscope with a rigid section holding a cartridge with five standard 4.8-mm titanium surgical staples. The distal tip contains an anvil for bending the staples, two small 21-gauge screws, and an ultrasonic transducer to measure the distance to the cartridge. MUSE is a three-step procedure that includes: (1) Advancing the device into the stomach through an overtube and retroflex; (2) Retraction of the device to 3 cm proximal to the GEJ for clamping when the tissue thickness measurement reaches 1.4-1.6 mm and actuating the stapler; and (3) The procedure is repeated 5 times to create an anti-reflux barrier. The results of various prospective studies have been compared favorably with Stretta and TIF-2 (see below). Overall patients report symptomatic improvement and reduction of PPI use. Long-term follow-up includes data to 5 years. Significant improvement in GERD-HRQL score and reduction in the number of patients taking PPIs daily, 69-92% and 64%, respectively, have been reported. Limited functional analysis of the impact on pH monitoring has been positive for reduction in acid exposure. The safety profile of the device is robust, with reported complications including gastrointestinal bleeding, perforation, pneumothorax, and empyema, all < 3%. Most studies have included patients with GERD with a hiatal hernia < 3 cm.

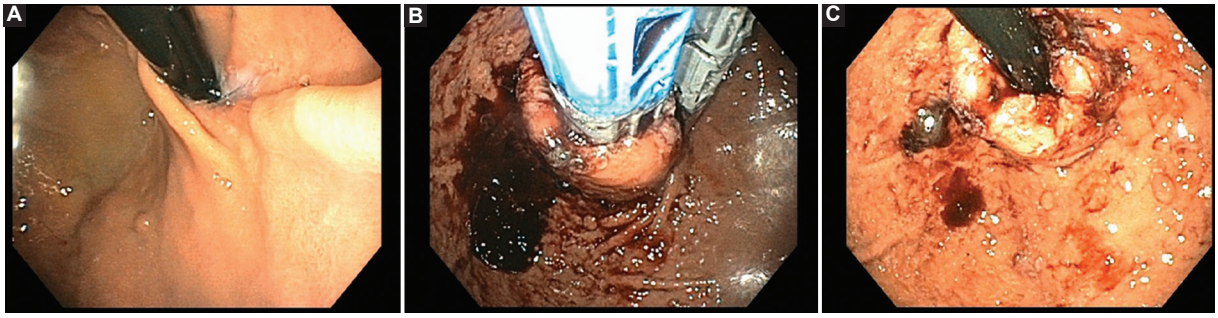

Figure 3. A: *endoscopic retrograde appearance of the cardias showing a hiatal hernia and a cap on the endoscope.* **B:** *endoscopic view showing TIF-2 device plicating.* **C:** *endoscopic view of a completed TIF-2 plication.*

TIF involves the use of EsophyX EndoGastric Solutions, Inc., Redmond, WA, United States. The EsophyX is a device inserted through the mouth and positioned in the esophagus and stomach and creates folds of tissue held together by plications, creating a mechanical antireflux barrier. The device has evolved, along with the technique, in creating circumferential plications rather than longitudinal. The circumferential plication encompasses 200° to 300° in circumference and ~3-cm length wrap over the distal esophagus below the diaphragm to create full-thickness plications. The current version of EsophyX is easier to use and more automated with a result that mimics a Toupet surgical fundoplication (Figs. 3A-C)[40-42].

Best candidates for TIF are patients with a Hill Grade II LES incompetence without a concomitant HH. Patients with a hiatal hernia > 2 cm and a Hill grade 3-4 can be treated with concomitant hernia repair and TIF. Most studies, randomized and non-randomized, have included patients with small to no hiatal hernia, absent severe erosive disease, or Barrett's epithelium. Rates of success range from 50% at 1 year to 92% at 10 years. Overall, improvement in GERD-HRQL score, reduction in heartburn and regurgitation is observed in ~70% of patients, and a reduction in PPI use of approximately 63% at 1 year. Studies randomized to TIF versus sham have included responses up to a year, with a primary endpoint being an equal or > 50% reduction in GERD-HRQL. Data at 5 years have shown improvement in 80-86% of patients. Performing a combined endoscopic plication with TIF and laparoscopic fundoplication may provide a greater insight into the most desired intervention and actional mechanisms[43].

Acid measurement and lowering of acid reflux episodes have been documented at 3 months but not at a year follow-up point. Adverse events are uncommon, occurring in < 3%. TIF has been favorably compared to antireflux surgery in reducing symptoms and decreasing PPI use with a better safety profile and fewer adverse events long-term.

GERDx (G-SURG GmbH, Seeon–Seebruck, Germany) involves performing a full-thickness plication with the GERDx system, which creates a plication with a pretied transmural suture. It uses hydraulic elements for control and requires a slim gastroscope that works as a light source. Symptomatic improvement is achieved in 93.3% of patients and 63% were able to discontinue PPI[44]. However, almost 20% required surgical anti-reflux procedures at 3 months. Improvement in DeMeester score was reduced with ~60.0%) achieving normal levels. Reduction in PPI use was reported with most being on demand or off medication, ~80%. The complication rate is around 10%, including a suture passing through the left hepatic lobe, GE junction hematoma, a Mallory–Weiss tear, and empyema.

Ligation

PECC-B ligation involves ligating GEJ mucosa with a band[45,46]. After a routine esophagogastroduodenoscopy is performed, the endoscope is then loaded with a standard ligating device advanced to the gastric fundus, and retroflexed. The mucosa around the cardia opening of the gastric fundus is suctioned and a ligation is performed. This is repeated up to 4 times, depending on the degree of cardial incompetence. The first band is placed ~ 1 cm above the cardia along the lesser curvature and the second band is ~ 1 cm above the greater curvature. A clip may be placed at the base of the bands to minimize the risk of band slippage. This procedure can be performed in patients with all Hill grades. Statistically significant reduction in the GERD-Q scores at 1, 3, 6, and 12 months was

statistically significantly decreased, with apparent better results in patients with Hill Type III. Randomized controlled trials of patients with refractory GERD have shown significant improvement in GERD-HRQL score and the number of reflux episodes at 1 year. The overall safety profile of the technique is good, with only minor side effects reported, including transient dysphagia and epigastric pain, in 25% and 40%, respectively. Overall, data are limited and lack proper follow-up and randomization. Advantages include simplicity of technique, use of familiar equipment and devices, safe profile, and reported efficacy.

Conclusion

GERD is a complex and chronic condition. Symptoms can be caused by multiple factors and not necessarily only from reflux of gastric contents. The management should be multimodal, always starting with the least invasive and effective treatment, medical. For patients with an inappropriate response or those not wanting to take long-term medications, endoscopic and surgical interventions are warranted. The selection of patients is important to determine the most appropriate therapeutic route. Endoscopic therapies have evolved to include easier techniques, simpler, widely available, effective, and safe, that do not require cumbersome add-on devices. Independent of technique, the clinical success, and reduction of medication intake are similar across all techniques. The appropriate selection will be made after a thorough discussion with the patient.

Funding

The authors declare that they have not received funding.

Conflicts of interest

Advisory board and Speaker Bureau for Boston Scientific, Microtech, Pentax, Olympus, ConMed, Endosound, and Medtronic. Co-owner of EndoRx.

Ethical disclosures

Protection of human and animal subjects. The authors declare that no experiments were performed on humans or animals for this study.

Confidentiality of data. The authors declare that no patient data appear in this article. Furthermore, they have acknowledged and followed the recommendations as per the SAGER guidelines depending on the type and nature of the study.

Right to privacy and informed consent. The authors declare that no patient data appear in this article.

Use of artificial intelligence for generating text. The authors declare that they have not used any type of generative artificial intelligence for the writing of this manuscript nor for the creation of images, graphics, tables, or their corresponding captions.

References

1. Aziz Q, Fass R, Gyawali P, Miwa H, Pandolfino JE, Zerbib F. Functional esophageal disorders. Gastroenterology. 2016;150(6):1368-79.
2. Eusebi LH, Ratnakumaran R, Yuan Y, Solaymani-DOdaran M, Bazzolli F, Ford AC. Global prevalence of, and risk factors for, gastroesophageal reflux symptoms: a meta-analysis. Gut. 2018;67:430-40.
3. Delshad SD, Almario CV, Chey WD, Spiegel BM. Prevalence of gastroesophageal reflux disease and proton pump inhibitor-refractory symptoms. Gastroenterology. 2020;158:1250-61.
4. Tack J, Becher A, Mulligan C, Johnson DA. Systematic review: the burden of disruptive gastro-esophageal reflux disease on health-related quality of life. Aliment Pharmacol Ther. 2012;35:1257-66.
5. De la Coba OC, Arguelles Arias F, de Argila M, de Prados C. Proton-pump inhibitors adverse effects: a review of the evidence and position statement by the Sociedad Espanola de Patologia Digestiva. Rev Esp Enferm Dig. 2016;108:207-24.
6. Chen J, Brady P. Gastroesophageal reflux disease: pathophysiology, diagnosis, and treatment. Gastroenterol Nurs. 2019;42:20-8.
7. Tack J, Pandolfino JE. Pathophysiology of gastroesophageal reflux disease. Gastroenterology. 2018;154:277-88.
8. Clarrett DM, Hachem C. Gastroesophageal reflux disease (GERD). Mo Med. 2018;115:214-8.
9. Sandhu DS, Fass R. Current trends in the management of Gastroesophageal reflux disease. Gut Liver. 2018;12:7-16.
10. Rettura F, Bronzini F, Campigotto M, Lambiase C, Pancetti A, Berti G, et al. Refractory gastroesophageal reflux disease: a management update. Front Med (Lausanne). 2021;8:765061.
11. Katz PO, Dunbar KB, Schnoll-Sussman FH, Greer KB, Yadlapati R, Spechler SJ. ACG clinical guideline for the diagnosis and management of gastroesophageal reflux disease. Am J Gastroenterol. 2022;117:27-56.
12. Frazzoni M, Piccoli M, Conigliaro R, Frazzoni L, Melotti G. Laparoscopic fundoplication for gastroesophageal reflux disease. World J Gastroenterol. 2014;20:14272-9.
13. Watson DI. Laparoscopic treatment of gastro-esophageal reflux disease. Best Pract Res Clin Gastroenterol. 2004;18:19-35.
14. Oelschlager BK, Quiroga E, Parra JD, Cahill M, Polissar N, Pellegrini CA. Long-term outcomes after laparoscopic antireflux surgery. Am J Gastroenterol. 2008;103:280-7; quiz 288.
15. Hill LD, Kozarek RA, Kraemer SJ, Aye RW, Mercer CD, Low DE, et al. The Gastroesophageal flap valve: in vitro and in vivo observations. Gastrointest Endosc. 1996;44:541-7.
16. Kozarek RA, Phelps JE, Sanowski RA, Grobe JL, Fredell CH. An anti-0reflux prosthesis in the treatment of gastroesophageal reflux. Ann Intern Med. 1983;98:310-5.
17. Chen YK, Raijman I, Ben-Menachem T, Starpoli AA, Liu JJ, Pazwash H, et al. Long-term outcomes of endoluminal gastroplication: a U.S. multicenter trial. Gastrointest Endosc. 2005;61:659-67.
18. Cohen LB, Johnson DA, Ganz RA, Aisenberg J, Deviere J, Foley TR, et al. Enteryx implantation for GERD: expanded multicenter trial results and interim post approval follow-up to 24 months. Gastrointest Endosc. 2005;61:650-8.
19. Benias PC, D'Souza L, Lan G, Gluckman C, Inamdar S, Trindade AJ, et al. Initial experience with a novel resection and plication (RAP) method for acid reflux: a pilot study. Endosc Int Open. 2018;6:E443-9.
20. Janu P, Shughoury AB, Venkat K, Hurwich D, Galouzis T, Siatras J, et al. Laparoscopic hiatal hernia repair followed by transoral incisionless fundoplication with EsophyX device (HH + TIF). Efficacy and safety in two community hospitals. Surg Innov. 2019;26:675-86.
21. Richter JE, Kumar A, Lipka S, Miladinovic B, Velanovich V. Efficacy of laparoscopic Nissen fundoplication vs transoral incisionless fundoplication or proton pump inhibitors in patients with gastroesophageal reflux disease: A systematic review and network meta-analysis. Gastroenterology. 2018;154:1298-308.

22. Rodriguez de Santiago E, Albeniz E, Estremera-Arevalo F, Teruel Sanchez-Vegazo C, Lorenzo-Zuniga V. Endoscopic anti-reflux therapy for gastroesophageal reflux disease. World J Gastroenterol. 2021;27:6601-14.
23. Kalapala R, Shah H, Nabi Z, Darisetty S, Talukdar R, Nageshwar Reddy D. Treatment of gastroesophageal reflux disease using radiofrequency ablation (Stretta procedure): an interim analysis of a randomized trial. Indian J Gastroenterol. 2017;36:337-42.
24. Lipka S, Kumar A, Richter JE. No evidence for efficacy of radiofrequency ablation for treatment of gastroesophageal reflux disease: a systematic review and meta-analysis. Clin Gastroenterol Hepatol. 2015;13:1058-67.
25. Zerbib F, Sacher-Huvelin S, Coron E, Coffin B, Melchior C, Ponchon T, et al. Randomized clinical trial: esophageal radiofrequency energy delivery versus sham for PPI-refractory heartburn. Aliment Pharmacol Ther. 2020;52:637-45.
26. Xie P, Yan J, Ye L, Wang C, Li Y, Chen Y, et al. Efficacy of different endoscopic treatments in patients with gastroesophageal reflux disease: a systematic review and network meta-analysis. Surg Endosc. 2021;35:1500-10.
27. Sui X, Gao X, Zhang L. Clinical efficacy of endoscopic antireflux mucosectomy vs. Stretta radiofrequency in the treatment of gastroesophageal reflux disease: a retrospective, single-center cohort study. Ann Transl Med. 2022;10:660.
28. Inoue H, Tanabe M, de Santiago ER. Anti-reflux mucosal ablation (ARMA) as a new treatment for gastroesophageal reflux refractory to proton pump inhibitors: a pilot study. Endosc Int Open. 2020;8:E133-8.
29. Shimamura Y, Inoue H, Tanabe M, Ushikubo K, Yamamoto K, Kimoto Y, et al. Clinical outcomes of anti-reflux mucosal ablation for gastroesophageal reflux disease: an international bi-institutional study. Gastroenterol Hepatol. 2023;39:149-56.
30. Tanabe M, Inoue H, Abad MR. 878 clinical outcomes of endoscopic anti-reflux treatment methods; anti-reflux mucosectomy (ARMS) and anti-reflux mucosal ablation (ARMA). Gastrointest Endosc. 2020;91:AB72.
31. Kalapala R, Jagtap N, Nabi Z. Anti-reflux mucosal ablation (ARMA) for refractory gastroesophageal reflux disease-an interim analysis. Endoscopy. 2021;53:OP210.
32. Hernández Mondragón OV, Zamarripa Mottú RA, García Contreras LF. Clinical feasibility of a new antireflux ablation therapy on gastroesophageal reflux disease (with video). Gastrointest Endosc. 2020;92:1190-201.
33. Patil G, Dalal A, Maydeo A. Feasibility and outcomes of anti-reflux mucosectomy for proton pump inhibitor dependent gastroesophageal reflux disease: first Indian study (with video). Dig Endosc. 2020;32:745-52.
34. Inoue H, Ito H, Ikeda H. Anti-reflux mucosectomy for gastroesophageal reflux disease in the absence of hiatus hernia: a pilot study. Ann Gastroenterol. 2014;27:346-51.
35. Yang X, Tan J, Liu Y, Feng Y, Shi R. Comparison of 180° anti-reflux mucosectomy versus 270° anti-reflux mucosectomy for treatment of refractory gastroesophageal reflux disease: a retrospective study. Surg Endosc. 2022;36:5002-10.
36. Yoo IK, Ko WJ, Kim HS. Anti-reflux mucosectomy using a cap-assisted endoscopic mucosal resection method for refractory gastroesophageal disease: a prospective feasibility study. Surg Endosc. 2020;34:1124-31.
37. Kim HJ, Kwon CI, Kessler WR. Long-term follow-up results of endoscopic treatment of gastroesophageal reflux disease with the MUSE™ endoscopic stapling device. Surg Endosc. 2016;30:3402-8.
38. Zacheri J, Roy-Shapira A, Bonavina L, Bapaye A, Liesslich R, Schoppmann SF, et al. Endoscopic anterior fundoplication with the Medigus Ultrasonic Surgical Endoplaster MUSE endoscopic stapling device. Surg Endosc. 2016;30:3402-8.
39. Kauer WK, Roy-Shapira A, Watson D, Sonnenschein M, Sonnenschein E, Unger J, et al. Preclinical trial of a modified gastroscope that performs a true anterior fundoplication for the endoluminal treatment of gastroesophageal reflux diseasr. Surg Endosc. 2009;23:2728-31.
40. Trad KS, Barnes WE, Prevou ER. The TEMPO trial at 5 years: transoral fundoplication (TIF 2.0) is safe, durable, and cost-effective. Surg Innov. 2018;25:149-57.
41. Testoni S, Hassan C, Mazzoleni G. Long-term outcomes of transoral incisionless fundoplication for gastro-esophageal reflux disease: a systematic review and meta-analysis. Endosc Int Open. 2021;9:E239-46.
42. Chimukangara M, Jalilvand AD, Melvin WS, Perry KA. Long-term reported outcomes of transoral incisionless fundoplication: an 8-year cohort study. Surg Endosc. 2019;33:1304-9.
43. Nguyen NT, Chinn J, Chang K. Collaboration between GI surgery & Gastroenterology improves understanding of the optimal antireflux valve-the omega flap valve. Surg Endosc. 2021;35:3214-20.
44. Weitzendorfer M, Spaun GO, Antoniou SA, Witzel K, Emmanuel K, Koch OO. Clinical feasibility of a new full-thickness endoscopic plication device (GERDx™) for patients with GERD: results of a prospective trial. Surg Endosc. 2018;32:2541-9.
45. Li ZT, Ji F, Han XW. Endoscopic cardial constriction with band ligation in the treatment of refractory gastroesophageal reflux disease: a preliminary feasibility study. Surg Endosc. 2021;35:4035-41.
46. Li Z, Li Y, Wu Y, Li M, Yan Z, Nie S, et al. Endoscopic tightening of the cardia mucosa in gastroesophageal reflux disease: a case series of 120 patients up to 1-year follow-up. J Clin Transl Res. 2022;8:147-51.