Check for updates

ORIGINAL ARTICLE

Protective effects of Passiflora Incarnata on ischemia-reperfusion injury in testicular torsion: an experimental study in a rat model

Efectos protectores de Passiflora incarnata en la lesión por isquemia-reperfusión en la torsión testicular: un estudio experimental en un modelo de rata

Mustafa Azizoğlu[1], Serkan Arslan[1], Ebru Gökalp-Özkorkmaz[2], Fırat Aşır[3], Erol Basuguy[1], Mehmet H. Okur[1], Bahattin Aydoğdu[1], Müsemma A. Karabel[4], Mansur Dağgülli[5], and İbrahim Kaplan[6]*

[1]Department of Pediatric Surgery, Medical School, Dicle University, Diyarbakır; [2]Department of Nursing, Faculty of Health Sciences, Yıldırım Beyazit University, Ankara; [3]Department of Histology and Embryology, Medical School, Dicle University, Diyarbakır; [4]Department of Pediatrics, Medical School, Dicle University, Diyarbakır; [5]Department of Urology, Medical School, Dicle University, Diyarbakır; [6]Department of Biochemistry, Medical School, Dicle University, Diyarbakır. Turkey

Abstract

Objective: *The current study aimed to explore the potential protective effect of Passiflora Incarnata L., (PI) in treating IR injury after testicular torsion in rats.* **Materials and methods:** *This research investigated the impact of PI on IR damage in male Wistar albino rats. Animals were divided to three groups: group 1 (sham), group 2 (IR), and group 3 (IR+PI).* **Results:** *The malondialdehyde (MDA), myeloperoxidase (MPO) and glutathione (GSH) levels did not significantly differ across the groups ($p = 0.830$, $p = 0.153$ and $p=0.140$, respectively). However, Group 3 demonstrated a superior total antioxidant status (TAS) value compared to Group 2 ($p = 0.020$). Concurrently, Group 3 presented a significantly diminished mean total oxidant status (TOS) relative to Group 2 ($p = 0.009$). Furthermore, Group 3 showed a markedly improved Johnsen score relative to Group 2 ($p < 0.01$). IR caused cell degeneration, apoptosis, and fibrosis in testicular tissues. PI treatment, however, mitigated these effects, preserved seminiferous tubule integrity and promoted regular spermatogenesis. Furthermore, it reduced expression of tumor necrosis factor-alpha (TNF-α), Bax, and Annexin V, signifying diminished inflammation and apoptosis, thereby supporting cell survival ($p < 0.01$, $p < 0.01$, $p < 0.01$, respectively).* **Conclusions:** *This study revealed that PI significantly reduces oxidative stress and testicular damage, potentially benefiting therapies for IR injuries.*

Keywords: *Passiflora Incarnata. Ischemia reperfusion. Testicular torsion. Testicular damage. Spermatogenesis.*

Resumen

Objetivo: *Explorar el posible efecto protector de Passiflora incarnata L. (PI) en el tratamiento de la lesión por isquemia-reperfusión (IR) después de una torsión testicular en ratas.* **Método:** *Se estudió el impacto de Passiflora incarnata en el daño por IR en ratas Wistar albinas machos. Los animales se dividieron tres grupos: 1 (simulado), 2 (IR) y 3 (IR+PI).* **Resultados:** *Los niveles de malondialdehyde (MDA), myeloperoxidase (MPO) y glutathione (GSH) no difirieron significativamente entre los grupos ($p = 0.830$, $p = 0.153$ y $p = 0.140$, respectivamente). Sin embargo, el grupo 3 tuvo un valor de estado antioxidante total (TAS) superior en comparación con el grupo 2 ($p = 0.020$). Al mismo tiempo, el grupo 3 presentó un estado oxidante total (TOS) medio significativamente disminuido en comparación con el grupo 2 ($p = 0.009$). El grupo 3 mostró una mejora notable en la puntuación de Johnsen en comparación con el grupo 2 ($p < 0.01$). La IR causó degeneración celular, apoptosis*

***Correspondence:**
Mustafa Azizoğlu
E-mail: mdmazizoglu@gmail.com

Date of reception: 21-08-2023
Date of acceptance: 03-10-2023
DOI: 10.24875/CIRUE.M23000660

Cir Cir (Eng). 2024;92(2):161-169
Contents available at PubMed
www.cirugiaycirujanos.com

2444-0507/© 2023 Academia Mexicana de Cirugía. Published by Permanyer. This is an open access article under the terms of the CC BY-NC-ND license (http://creativecommons.org/licenses/by-nc-nd/4.0/).

y fibrosis en los tejidos testiculares. El tratamiento con PI mitigó estos efectos, preservó la integridad de los túbulos seminíferos y promovió la espermatogénesis regular. Además, redujo la expresión de factor de necrosis tumoral alfa, Bax y anexina V, lo que significa una disminución de la inflamación y de la apoptosis, respaldando así la supervivencia celular (p < 0.01, p < 0.01 y p < 0.01, respectivamente). **Conclusiones:** *Este estudio reveló que PI reduce significativamente el estrés oxidativo y el daño testicular, beneficiando potencialmente las terapias para lesiones por IR.*

Palabras clave: *Passiflora incarnata. Isquemia-reperfusión. Torsión testicular. Daño testicular. Espermatogénesis.*

Introduction

Acute scrotum, a urological emergency, presents as sudden scrotal pain, redness, and swelling. Testicular torsion (TT), which makes up approximately 35% to 42% of acute scrotal conditions, is the culprit behind this urological issue[1]. This condition results from a twisted spermatic cord, interrupting the flow of blood to the testicle. It's imperative to intervene early to prevent tissue damage resulting from ischemia[1,2]. Instead of being employed as a diagnostic method, the preferred approach to treating testicular torsion involves executing manual or surgical detorsion as an emergency procedure. Literature suggests that detorsion, either manual or surgical, carried out within the initial six hours results in a high rate of testicular tissue preservation[2]. The reported rates of orchiectomy vary widely, with most studies indicating a range between 39% to 71%[3]. The principal factors contributing to the damage of testicular parenchymal tissue include elevated reactive oxygen species (ROS) levels, increased calcium levels within mitochondria, and cellular apoptosis. In an effort to limit the negative impacts of ischemia-reperfusion injury, a variety of medical treatments, used in tandem with manual or surgical detorsion, are currently under investigation[4-6].

The passionflower, scientifically known as PI is a perennial plant capable of reaching heights of up to 10 meters, bearing egg-shaped edible fruits. Originally found in South America, Australia, and Southeast Asia, it is now cultivated for pharmaceutical applications. Among the Passiflora genus[7], PI is recognized for its documented therapeutic benefits. Various parts of the plant, including aerial parts, flowers, and fruits, are harnessed for medicinal uses due to their anthelmintic, antispasmodic, and anxiolytic properties. Passionflower is employed as a treatment for a variety of conditions, ranging from burns and diarrhea to painful menstruation, neurotic disorders, and insomnia, among others[6,7]. Soumya et al.'s study first revealed that passionflower extract juice could mitigate myocardial infarction, partially through oxidative stress inhibition[8]. It's also useful in treating morphine dependency and can be beneficial for convulsions or neuralgia[7,9].

The current study aimed to investigate the potential protective effect of PI in treating ischemia-reperfusion injury after testicular torsion in rats. To the best of our knowledge, this is the first study administering PI to rats in a testis torsion-induced model.

Materials and methods

This research investigated the impact of PI on ischemia-reperfusion damage in male Wistar albino rats. A total of 21 rats, each 12 weeks old and weighing an average of 240 g, were used in compliance with the guidelines of the institution and the National Research Council's principles for the Care and Use of Laboratory Animals. The Dicle University Animal Studies Ethical Committee granted ethical clearance for the research (approval number: 2023/08, date:30.03.2023).

The rats were kept under conditions with a temperature between 20-23°C and a light/dark cycle of 12 hours. Their diet consisted of standard pellets and water supplied freely. They were randomly separated into three groups: Group 1 (sham), Group 2 (ischemia-reperfusion), and Group 3 (treatment). In group 1, all surgical procedures except for testicular torsion-detorsion were performed. This was done to establish base values for all parameters. The testicle was extracted via a scrotal incision and then placed back in its usual position within the scrotum. No testicular torsion was applied in this particular group. Group 2 experienced testicular torsion and detorsion without any medication. Group 3 was administered 500 mg/kg/day of PI orally (Pasiflora incarnata tablet form, Megafarma- Istanbul, Turkey) for 5 days prior to performing I/R. The PI was diluted with a 0.9% saline solution just before use. In Groups 2 and 3, ischemia-reperfusion injury was induced in the rat testes using a method that involved pulling out the testis through an inguinoscrotal incision, rotating it 720 degrees clockwise, and then securing it to the

scrotum for two hours using a 5.0 prolene suture. The aim was to establish a controlled testicular torsion model to investigate the impact of ischemia and the subsequent reperfusion. Post-ischemia, the testis was detorsioned and allowed to remain in its regular position for four hours to evaluate reperfusion damage. Finally, orchiectomy was performed to obtain testis tissue for histopathological examination, and blood was drawn via cardiac puncture for biochemical analysis. All surgical procedures were carried out under appropriate anesthesia and sterile conditions. For this, rats were given a mix of two anesthetic drugs, xylazine hydrochloride (Rompun 2%, Bayer, Turkey) and ketamine hydrochloride (Alfamine 10%, Ege Vet, Turkey) at dosages of 10 mg/kg and 50 mg/kg respectively, both administered intraperitoneally. Xylazine hydrochloride served as a sedative and muscle relaxant, whereas ketamine hydrochloride was used for its dissociative anesthetic effects. The use of these agents helped ensure the rats' comfort and pain minimization during the procedures (Fig. 1).

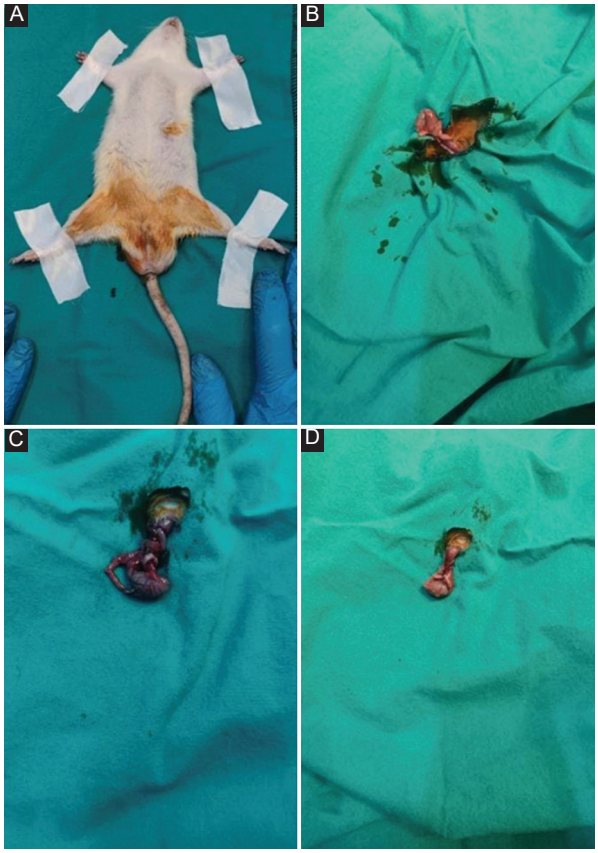

Figure 1. A: *preoperative.* **B:** *before torsion procedure.* **C:** *torsion was performed.* **D:** *detorsion.*

Biochemical evaluation

Following a cardiac puncture, blood samples were swiftly moved to the biochemistry lab on ice. These samples were then centrifuged at 4,000 rotations per minute for 5 minutes, and the serum was isolated. Analyses were done for total antioxidant status (TAS), total antioxidant status (TOS), Malondialdehyde (MDA), Myeloperoxidase (MPO), and Glutathione (GSH). Using an Abbott Architect C16000 auto analyzer, the TAS and TOS levels were gauged via commercial kits supplied by Rel Assay Diagnostics from Gaziantep, Turkey, and through automated colorimetric methods designed by Erel et al[10,11]. The TAS findings are given in micromolar trolox equivalent per liter, while the TOS findings are provided in micromolar hydrogen peroxide equivalent per liter. MDA content was assessed through a spectrophotometric method based on the color change that occurs when thiobarbituric acid reacts with MDA, as previously described[12]. Similarly, MPO activity was also evaluated spectrophotometrically, as mentioned before[6,13]. The method proposed by Paglia et al., was utilized to measure the glutathione peroxidase (GSH-Px) activity, which checks the enzyme's capacity to aid the conversion of reduced glutathione (GSH) into oxidized glutathione (GSSG) in the presence of hydrogen peroxide[4,14].

Immunohistochemical examination

Testicular tissues were excised for histological sampling. Dissected cerebral samples were further analyzed for histological evaluation. Samples were immersed in zinc-formalin and dehydrated through grading alcohol series and incubated in paraffin wax. 5 μm sections were cut from paraffin blocks and stained for hematoxylin eosin dye and immune staining. Testicular sections were dewaxed, hydrated in grading alcohol series and washed in distilled water. 3% hydrogen peroxide (H2O2) was dropped on slides to block endogen peroxidase activity. After washing in PBS, sections were incubated with anti-blood brain barrier (catalog no:836804, Biolegend, California, US). Annexin V (catalog no:0902012, Boster Biology Tech., 1/100) and TNF-α and Bax (catalog no: 15970 and 17069, Biorbyt, 1/100) overnight at + 4°C. Sections were biotinylated and allowed to react with streptavidin peroxidase solution (Thermo Fischer, US) for 15 minutes. After PBS washing, diaminobenzidine (DAB) chromogen was used as a chromogen to observe color change. The

reactions were stopped with PBS solution and sections were counter stained with hematoxylin dye. Slides were mounted and imaged with Zeiss Imager A2 light microscope. All images were processed and quantified using ImageJ software.Staining intensity of protein expression was measured by Image J software (version 1.53, http://imagej.nih.gov/ij). Measurement was calculated by method of Crowe et al.[15] Spermatogenesis were histologically evaluated for each sample with ten fields count by method of Johnsen et al.[16] A Johnsen score of 10 indicates maximum spermatogenesis activity, whereas a score of 1 indicates complete absence of germ cells. Histological scoring was performed by two blind experts (Table 1).

Table 1. Johnsen scoring for spermatogenesis

Johnsen Biopsy parameters	Score
Regular, dense spermatogenesis and tubule structure	10
Dense spermatozoa in the lumen but irregularity in the spermatogenic line	9
The small amount of spermatozoa present in the lumen	8
No spermatozoa in the lumen but spermatids are present	7
The low number of spermatids	6
No spermatozoa and spermatids but dense spermatocytes	5
Low amount of spermatocytes	4
Only Spermatogonia available	3
There are no germ cells	2
No germ cells or Sertoli cells	1

Statistical analysis

The statistical analysis was carried out with IBM SPSS 25.0 software (IBM, Armonk, New York, US). The data distribution was determined by applying the Shapiro-Wilk and Kolmogorov-Smirnov tests. If the data conformed to a normal distribution, it was recorded as the mean and standard deviation, and the ANOVA test was used. If not, data was presented as the median (IQR). For comparisons involving more than two groups, the non-parametric Kruskal-Wallis test was employed, and due to the small sample size in the groups, the post-hoc Dunn test was used. Statistical significance was recognized for values less than 0.05.

Results

The MDA levels were similar across all groups, with means of 1.36±0.55, 1.26±0.15, and 1.25±0.18 for groups 1, 2, and 3, respectively ($p = 0.830$). Similarly, MPO and GSH levels did not significantly differ across the three groups ($p = 0.153$ and $p = 0.140$, respectively). However, TAS levels were significantly different between groups 2 and 3 ($p = 0.031$) and groups 1 and 3 ($p = 0.049$) with an overall p-value of 0.020. TOS levels significantly varied between groups 2 and 3 ($p = 0.026$), and groups 1 and 2 ($p = 0.012$) with an overall p-value of 0.009. The tissue assessments revealed significant disparities in the Johnson score, a metric for testicular damage evaluation. Group 1 and Group 2 showed a clear difference, as did Group 2 and Group 3, with the overall p-value being less than 0.01. The same significant differences were observed for TNF-α, Bax, and Annexin V immunostaining percentages ($p < 0.01$ for each), reflecting the inflammation and apoptosis brought about by ischemia-reperfusion and the protective effects of the treatment (Table 2).

The hematoxylin and eosin staining of the testicular tissues is displayed in figure 2. In the sham group sections, a normal testicular tissue structure was observed. The seminiferous tubule membranes and spermatogenic line were seen naturally. Leydig cells were localized in the interstitial area. In the IR group, it was observed that spermatogenic cells were undergoing degeneration and apoptosis, the seminiferous tubule membranes were thickened, and fibrosis was developing in the interstitial area. Pycnosis was seen in the nuclei of Leydig cells. In the group where ischemia-reperfusion and PI were applied (group 3), improvement in the histopathology resulting from the IR damage was observed. It was seen that the integrity of the seminiferous tubule was preserved, the cells in the spermatogenesis line were regular, and the blood vessels and Leydig cells in the interstitial area looked almost normal histologically after the IR damage.

The immunoreactivity of TNF-α in the testicular tissues is demonstrated in figure 3. In the sham group, TNF-α expression was generally negative in the seminiferous tubules, spermatogenic cells, and interstitial area. In the IR group, TNF-α expression was intensely observed in the spermatogenic cells, interstitial area, and the membrane of the seminiferous tubule. After Passiflora treatment, a decrease in the TNF-α immune reaction was observed. It could be stated that due to Passiflora's anti-inflammatory effect.

Table 2. Biochemical and immunohistopathological parameters of all groups

	Group 1	Group 2	Group 3	p-value	Meaningful comparisons (intergroup)
Blood					
MDA	1.36 ± 0.55	1.26 ± 0.15	1.25 ± 0.18	0.830	
MPO	12.01 ± 2.83	11.83 ± 0.76	14.61 ± 3.69	0.153	2 and 3 (p = 0.031);
GSH	183.44 ± 66.94	166.45 ± 43.82	243.56 ± 89.15	0.140	1 and 3 (p = 0.049)
TAS	0.65 ± 0.08	0.62 ± 0.12	0.93 ± 0.29	0.020	2 and 3 (p = 0.026);
TOS	14.20 ± 8.49	136.58 ± 104.19	32.85 ± 43.33	0.009	1 and 2 (p = 0.012)
Tissue					
Johnson score	9 (9-10)	3 (1.25-3)	6 (5.25-7)	< 0.01	1 and 2; 2 and 3
TNF-α immunostaining*	17.52%	41.20%	21.87%	< 0.01	1 and 2; 2 and 3
Bax immunostaining*	12.73%	39.22%	23.20%	< 0.01	1 and 2; 2 and 3
Annexin V immunostaining*	13.88%	42.50%	30.03%	< 0.01	1 and 2; 2 and 3

*Percentage.
MDA: malondialdehyde; MPO: myeloperoxidase; GSH: glutathione; TAS: Total Antioxidant Status; TOS: Total Oxidant Status; TNF-α: tumor necrosis factor-alpha.

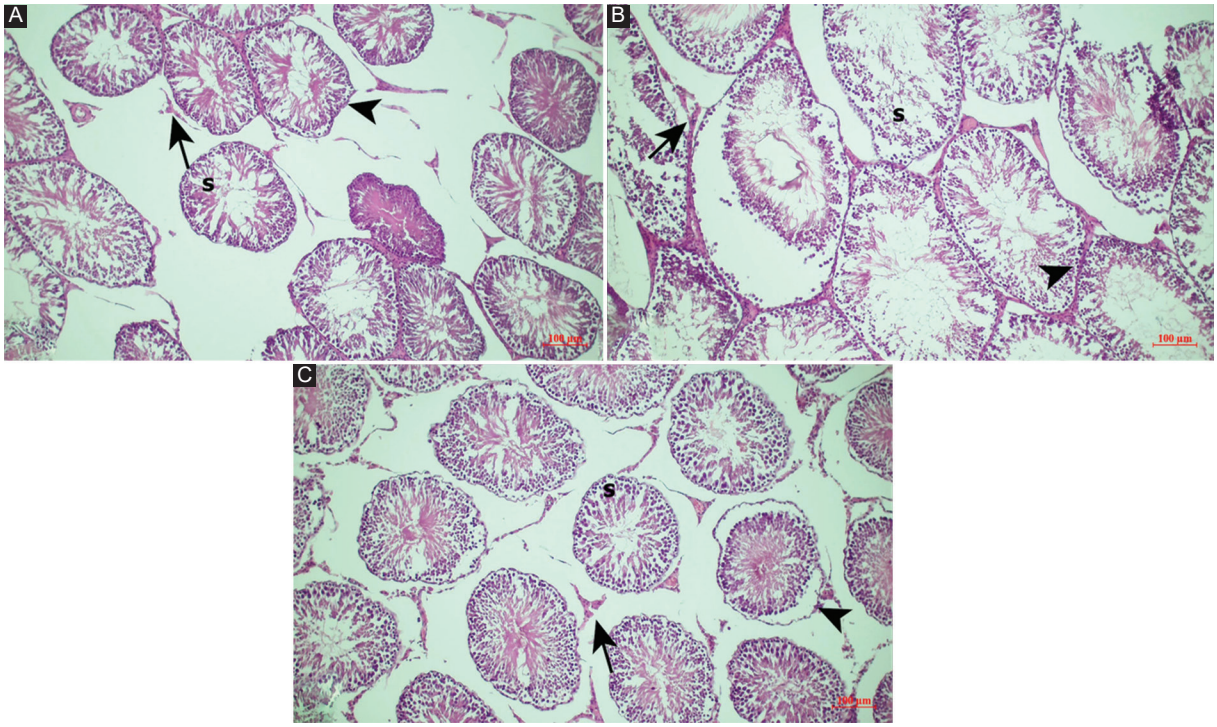

Figure 2. Hematoxyline eosin staining. **A:** *sham group.* **B:** *IR group.* **C:** *IR+PI group. S: spermatogenic cell line; Arrow: leydig cells; arrowhead: seminiferous tubule basement membrane. Scale bar: 100 μm; magnification: 10x.*

The immunoreactivity of Bax in the testicular tissues is illustrated in figure 4. In the sham group, the negative Bax expression was observed in the epithelium of seminiferous tubules, spermatogenic cells, and in the interstitial area. IR damage activated the apoptotic pathway and increased Bax expression. The Bax immune reaction was intensely observed in spermatogenic cells, the interstitial area, and the membrane of the seminiferous tubule. Due to Passiflora's antiapoptotic effect, proapoptotic Bax expression decreased and cell survival was supported. The Bax immune reactivity showed a decrease in the seminiferous tubules, spermatogenic cells, and Leydig cells.

The immunoreactivity of Annexin V in testicular tissues is presented in figure 5. In the sham group, Annexin V immune reactivity was mostly observed to be negative. Negative Annexin V reactions were detected in the epithelium of seminiferous tubules, spermatogenic cell lines, and

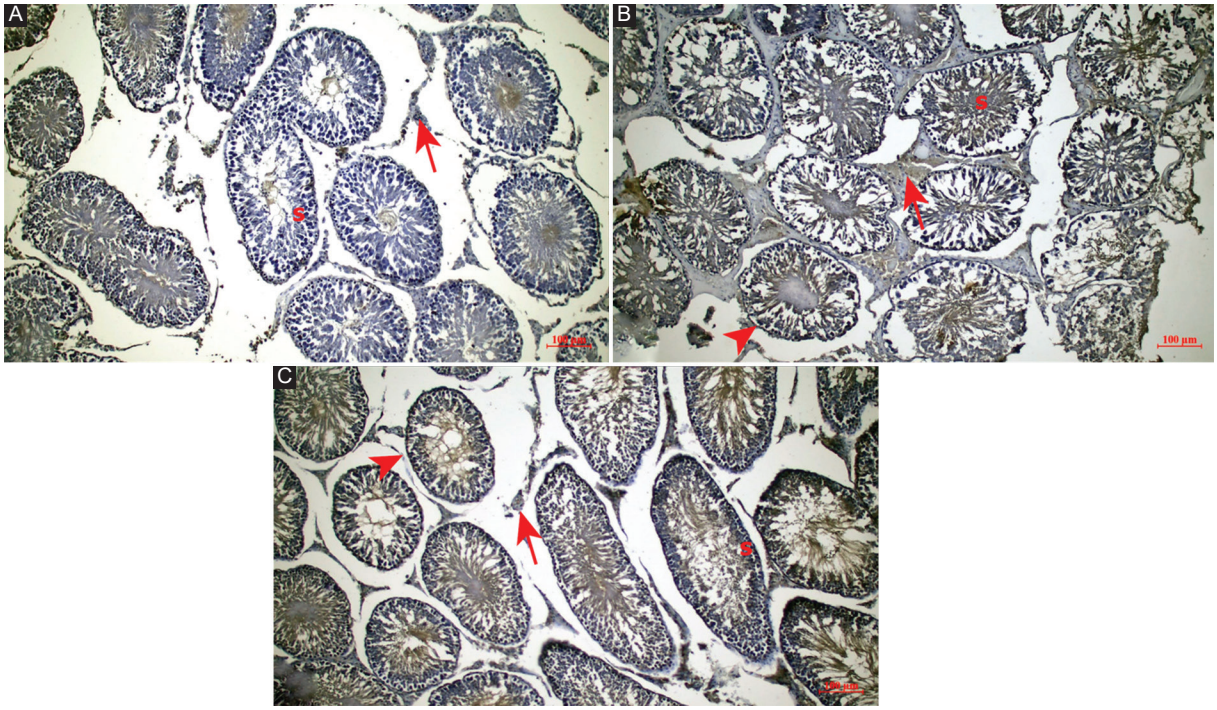

Figure 3. *TNF-α immunostaining.* **A:** *sham group.* **B:** *IR group.* **C:** *IR+PI group. S: spermatogenic cell line; Arrow: leydig cells; arrowhead: seminiferous tubule basement membrane. Scale bar: 100 µm; magnification: 10x.*

Leydig cells. In the IR group, due to the activation of the apoptotic pathway resulting from IR, Annexin V expression was observed intensely in spermatogenic cells, in the interstitial area, and the membrane of the seminiferous tubule. Due to the antiapoptotic effect of Passiflora, there was a significant decrease in the immune reaction of Annexin V, which is used as a marker of apoptotic cells. Annexin V expression showed a decrease in the seminiferous tubules, spermatogenic cells, and Leydig cells.

Discussion

Testicular torsion is a urological emergency that can cause infertility, damage to germ cells, and testicular atrophy. Urologists must take prompt action to treat the urgent situation of testicular torsion. One in 4000 guys between the ages of one and 25 experience this disorder annually[17]. Since severe testicular ischemia damage can happen after four to eight hours, prompt diagnosis and treatment are essential to preserve both testicular function and fertility. When surgical exploration is performed within six hours of the onset of symptoms, the testicles can be saved with a reported success rate of 90% to 100%[18]. When symptoms last for more than 12 hours, the rates drop to 50%, and when they last for 24 hours or longer, they often drop below 10%[19]. The literature has a wide range of orchiectomy rates, with the majority of series showing a range of 39% to 71%[17-19]. The main treatment for testicular torsion is surgical surgery, which involves reversing the torsion and restoring blood flow to the testis[1,4]. Given that the length of the torsion is strongly related to the chance of losing a testicle, prompt surgical intervention is absolutely necessary. In an effort to reduce IR damage related to TT, several strategies have been used such as cordycepin, roflumilast and ibuprofen, arbutin, thymoquinone, and syringic acid[4-6,20-22]. However this is the first study To the best of our knowledge, this is the first study administering PI to rats in a testis torsion-induced model.

The study of Okur et al.[5] found that cordycepin significantly reduced TNF-α and MDA levels and increased TAS while decreasing TOS in the testicular tissue of rats subjected to I/R, compared to the I/R group without cordycepin treatment, indicating its potential protective effect against I/R-induced testicular damage. Özgür et al.[6] study highlighted that both ibuprofen and roflumilast offer protective effects as antioxidant treatments in testicular ischemia-reperfusion injury, with roflumilast demonstrating superior benefits. Gökçe et al.[22] study found that in the testicular IR group, TOS, OSI, and MDA levels were higher than in the control group, while Thymoquinone (TQ) treatment effectively reduced MDA,

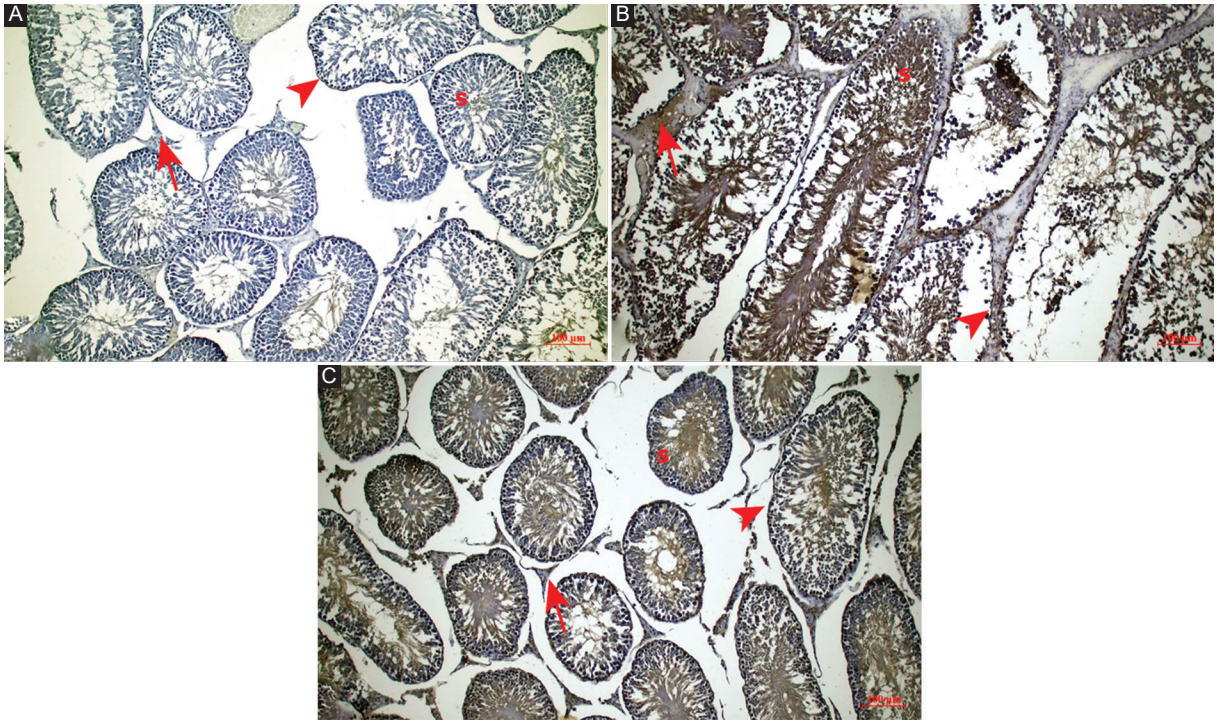

Figure 4. *Bax immunostaining.* **A:** *sham group.* **B:** *IR group.* **C:** *IR+PI group. S: spermatogenic cell line; Arrow: leydig cells; arrowhead: seminiferous tubule basement membrane. Scale bar: 100 μm; magnification: 10x.*

TOS, and OSI values, but had no impact on TAC and MPO activity. The research conducted by Sarikaya and his colleagues[4], revealed that syringic acid could mitigate the tissue damage brought about by ischemia-reperfusion. They noted an elevation in serum levels of antioxidants like SOD and GSH-Px, along with a reduction in MDA, which signifies lipid peroxidation. Moreover, rats treated with syringic acid exhibited improved seminiferous tubule morphology, spermatogenesis processes, and scores on both the Johnsen and Cosentino scoring systems, suggesting enhanced germ cell maturation. The results of their experimental study suggest the potential of syringic acid as an effective alternative therapeutic method to mitigate ischemia-reperfusion damage post-detorsion procedures in rats suffering from testicular torsion.

On the other hand, PI is highly regarded for its proven therapeutic advantages. Due to the plant's anthelmintic, antispasmodic, and anxiolytic characteristics, various components, including the aerial parts, flowers, and fruits, are used medicinally[23]. PI has shown potential in reducing stress, enhancing motivation, improving memory, managing insomnia, and alleviating anxiety and depressive states[23]. Pre-treatment with PI juice (2 ml/kg) for 28 days followed by isoproterenol treatment demonstrated protective effects against ISO-induced myocardial infarction in rats[8]. Another study concluded that Passiflora species, via their extracts and flavonoids such as quercetin, apigenin, and vitexin, have the potential to serve as a robust source of anti-inflammatory and antioxidant treatments[24]. These could be instrumental in preventing and controlling a wide range of diseases marked by complex inflammatory processes.

The findings from our research indicate that no significant differences in MDA, MPO, and GSH levels across the three groups. However, the Total Antioxidant Status (TAS) and Total Oxidant Status (TOS) levels varied significantly between the groups, particularly between groups 2 and 3 and groups 1 and 2, indicating variations in oxidative stress. The Johnson score, a metric for testicular damage, also showed significant differences between the groups, reflecting inflammation, apoptosis, and the impact of treatment with PI. The protective effects of treatment with PI were further confirmed by immunostaining results for TNF-α, Bax, and Annexin V. The histopathology analysis showed normal tissue structure in the control group, degeneration, and fibrosis in the ischemia-reperfusion group, and an improvement in tissue structure in the group treated with PI. Similarly, immunoreactivity for TNF-α, Bax, and Annexin V in testicular tissues further confirmed the protective effect of PI, demonstrating a reduction in inflammation and apoptosis after the administration of PI.

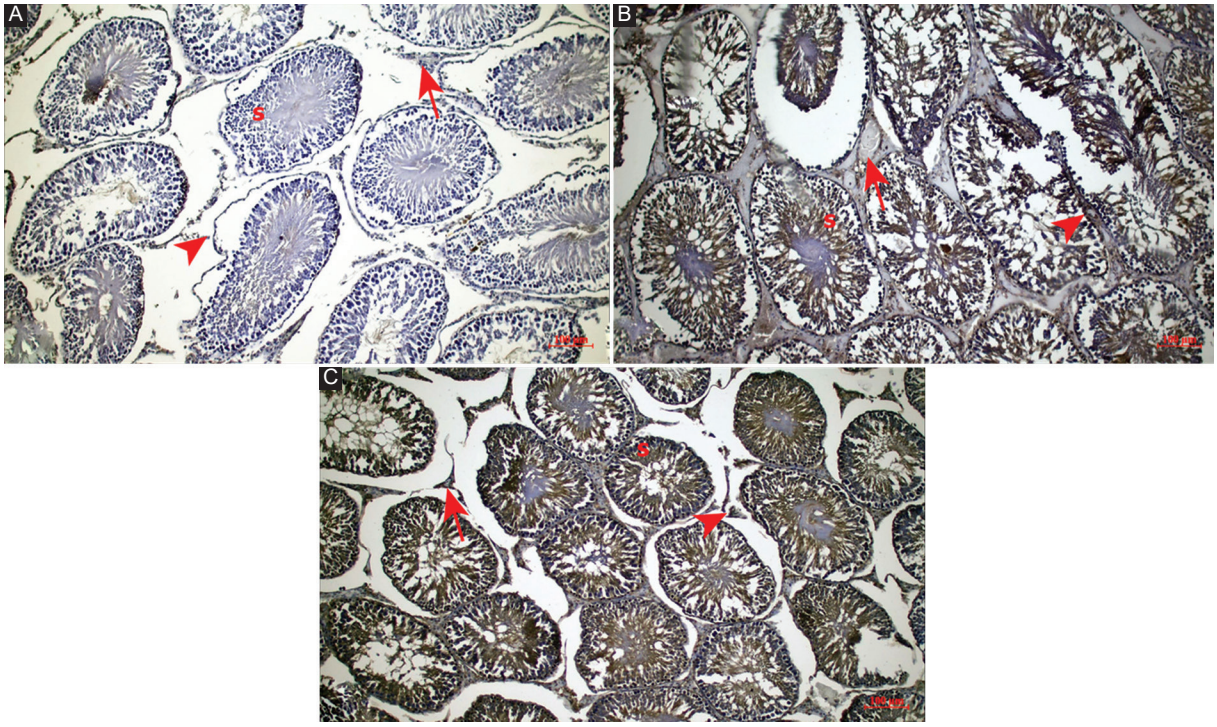

Figure 5. *Annexin V immunostaining.* **A:** *sham group.* **B:** *IR group.* **C:** *IR+PI group. S: spermatogenic cell line; Arrow: leydig cells; arrowhead: seminiferous tubule basement membrane. Scale bar: 100 μm; magnification: 10x.*

As evidenced by past research, various molecules have been employed to mitigate ischemic and reperfusion damage in testes. Additionally, PI has been proven to possess anti-inflammatory, antioxidant, analgesic, anthelmintic, antispasmodic, anxiolytic properties, and the ability to inhibit oxidative stress. Notably, this study represents the first exploration of PI impact on testicular ischemia-reperfusion. Overall, the results of this study showed the protective effect of on testicular torsion.

Conclusions

This study demonstrated that PI significantly mitigates oxidative stress and histopathological damage in testicular torsion. It reduced inflammation and apoptosis, confirming its potential as a therapeutic strategy against ischemia-reperfusion injury. To clarify the precise mechanism of the protective effects of PI, further studies are needed, and in progress.

Funding

The authors would like to thank DUBAP (Dicle University Scientific Research Projects) management for their financial support. DUBAP Project no: TIP.21.024.

Conflicts of interest

The authors declare no conflicts of interest.

Ethical disclosures

Protection of human and animal subjects. The authors declare that the procedures followed were in accordance with the regulations of the relevant clinical research ethics committee and with those of the Code of Ethics of the World Medical Association (Declaration of Helsinki).

Confidentiality of data. The authors declare that they have followed the protocols of their work center on the publication of patient data.

Right to privacy and informed consent. The authors declare that no patient data appear in this article.

Use of artificial intelligence for generating text. The authors declare that they have not used any type of generative artificial intelligence for the writing of this manuscript, nor for the creation of images, graphics, tables, or their corresponding captions.

References

1. Arslan S, Azizoğlu A, Kamci TO, Basuguy E, Aydogdu B, Okur MH, et al. The value of hematological inflammatory parameters in the differential diagnosis of testicular torsion and epididymo-orchitis in children. Exp Biomed Res. 2023;6(3):212-217.

2. Kuas N, Ergun E, Göllü G, Çakmak M, Ates U. Türkiye'de ele gelmeyen testis hastalarına güncel yaklaşım farklılıkları.Turkish J Ped Surg. 2022;36:26-33. doi: 10.29228/JTAPS.58049
3. Shunmugam M, Goldman RD. Testicular torsion in children. Can Fam Physician. 2021;67(9):669-671.
4. Sarikaya K, Kölükçü E, Unsal V, Özdemir S. Protective Effects of Syringic Acid on Ischemia-Reperfusion Injury in Testicular Torsion: An Experimental Study in a Rat Model. Cureus. 2023;15(7):e42390.
5. Aydogdu B, Basuguy E, Arslan S, Azizoğlu M, Ibiloglu İ, Kaplan İ, Aydogdu G, et al. The effect of low-dose Cordyceps on ischemia-reperfusion injury of the kidney in rats. Cir Cir. 2022;90(S2):69-74. English. doi: 10.24875/CIRU.22000303. PMID: 36480757.
6. Özgür BC, Surer H, Yücetürk CN, Karakan T, Özer E, Ogus E. The protective effect of roflumilast and ibuprofen on testicular ischemia reperfusion injury: An experimental study. Ulus Travma Acil Cerrahi Derg. 2022;28(6):730-735.
7. Patel S. Passiflora Incarnata Linn: A phytopharmacological review. Int. J. Green Pharm. 2009;3:277–280.
8. Soumya RS, Raj KB, Abraham A. Passiflora edulis (var. Flavicarpa) Juice Supplementation Mitigates Isoproterenol-induced Myocardial Infarction in Rats. Plant Foods Hum Nutr. 2021;76(2):189-195.
9. European Medicines Agency. Assessment Report on Passiflora Incarnata L. herba. Volume 22 European Medicines Agency; Amsterdam, The Netherlands: 2014.
10. Erel O. A novel automated method to measure total antioxidant response against potent free radical reactions. Clin Biochem. 2004;37:112–119.
11. Erel O. A new automated colorimetric method for measuring total oxidant status. Clin Biochem. 2005;38(12):1103– 1111.
12. Esterbauer H, Cheeseman KH. Determination of aldehydic lipid peroxidation products: Malonaldehyde and 4- hidroxynonenal. Meth Enzymol. 1990;186:407–421.
13. Bradley PP, Priebat DA, Christensen RD, Rothstein G. Measurement of cutaneous inflammation: estimation of neutrophil content with an enzyme marker. J Invest Dermatol. 1982;78(3):206-209.
14. Paglia DE, Valentine WN. Studies on the quantitative and qualitative characterization of erythrocyte glutathione peroxidase. J Lab Clin Med. 1967;70(1):158-69.
15. Crowe AR, Yue W. Semi-quantitative Determination of Protein Expression using Immunohistochemistry Staining and Analysis: An Integrated Protocol. Bio Protoc. 2019;9(24):e3465.
16. Johnsen SG. Testicular biopsy score count--a method for registration of spermatogenesis in human testes: normal values and results in 335 hypogonadal males. Hormones. 1970;1(1):2-25.
17. Lacy A, Smith A, Koyfman A, Long B. High risk and low prevalence diseases: Testicular torsion. Am J Emerg Med. 2023;66:98-104.
18. Mäkelä E, Lahdes-Vasama T, Rajakorpi H, Wikström S. A 19-year review of paediatric patients with acute scrotum. Scand J Surg. 2007;96(1):62-66.
19. Yecies T, Bandari J, Schneck F, Cannon G. Direction of Rotation in Testicular Torsion and Identification of Predictors of Testicular Salvage. Urology. 2018;114:163-166.
20. Demir EA, Demir S, Kazaz IO, Kucuk H, Alemdar NT, Buyuk A, et al. Arbutin abrogates testicular ischemia/reperfusion injury in rats through repression of inflammation and ER stress. Tissue Cell. 2023; 82:102056.
21. Khezri MR, Ghasemnejad-Berenji H, Ghasemnejad-Berenji M. Protective effects of empagliflozin on testicular injury induced by torsion/detorsion in adult male rats. J Pediatr Urol. 2023:S1477-5131(23)00244-9.
22. Gökçe A, Oktar S, Koc A, Gonenci R, Yalcinkaya F, Yonden Z, et al. Protective effect of thymoquinone in experimental testicular torsion. Urol Int. 2010;85(4):461-5.
23. Kim M, Lim HS, Lee HH, Kim TH. Role Identification of Passiflora Incarnata Linnaeus: A Mini Review. J Menopausal Med. 2017;23(3): 156-159.
24. Janda K, Wojtkowska K, Jakubczyk K, Antoniewicz J, Skonieczna-Żydecka K. Passiflora incarnata in Neuropsychiatric Disorders-A Systematic Review. Nutrients. 2020;12(12):3894.