Check for updates

ORIGINAL ARTICLE

The effect of antiangiogenic agent aflibercept on surgically induced endometriosis in a rat model

El efecto del agente antiangiogénico aflibercept sobre la endometriosis inducida quirúrgicamente en un modelo de rata

Caglayan Ates[1], Berna Dilbaz[2], Seval Yılmaz Ergani[1], and Fuad Atabay[3]*

[1]Department of Obstetrics and Gynecology, University of Health Sciences, Etlik Zubeyde Hanim Training and Research Hospital; [2]Department of Reproductive Endocrinology and Infertility, University of Health Sciences, Etlik Zubeyde Hanim Training and Research Hospital; [3]Department of Pathology, University of Health Sciences, Gulhane Training and Research Hospital. Ankara, Turkey

Abstract

Objective: *The aim of the study is to show for the first time how aflibercept affects endometriosis lesions.* **Material and methods:** *Surgically induced endometriosis in Wistar albino female rats. Rats with endometriosis were randomly divided into three groups: control (Co), aflibercept (Af), and leuprolide acetate (Le). Then, Af, aflibercept, and Le received leuprolide acetate. The control group was not treated. The weights and changes in intra-abdominal adhesions of the rats before and after treatment were recorded according to the Blauer adhesion score. Blood extracted for sacrifice was analyzed. Endometriotic lesions were evaluated for size, volume, histology, and immunohistochemistry (vascular endothelial growth factor [VEGF] and CD31). Significance level was accepted as $p < 0.05$.* **Results:** *Aflibercept significantly reduced endometrial implant volume ($p = 0.002$). The explant epithelial histological score showed a significant difference between aflibercept and leuprolide acetate ($p = 0.006$) and between aflibercept and control groups ($p = 0.002$). Aflibercept decreased VEGF-H and CD31 expression ($p = 0.001$) more than leuprolide acetate. Aflibercept improved adhesions ($p = 0.006$).* **Conclusion:** *Aflibercept is more successful than leuprolide acetate in the treatment of endometriosis.*

Keywords: *Aflibercept. Leuprolide acetate. Angiogenesis. Endometriosis. Vascular endothelial growth factor.*

Resumen

Objetivo: *Mostrar por primera vez cómo afecta aflibercept a las lesiones de endometriosis.* **Material y métodos:** *Endometriosis inducida quirúrgicamente en ratas hembras albinas Wistar. Las ratas con endometriosis se dividieron aleatoriamente en tres grupos: control (Co), aflibercept (Af) y acetato de leuprolida (Le). Luego, Af, aflibercept y Le recibieron acetato de leuprolida. El grupo de control no fue tratado. Los pesos y cambios en las adherencias intraabdominales de las ratas antes y después del tratamiento se registraron de acuerdo con la puntuación de adherencia de Blauer. La sangre extraída para el sacrificio fue analizada. Las lesiones endometriósicas se evaluaron en tamaño, volumen, histología e inmunohistoquímica (factor de crecimiento endotelial vascular [VEGF] y CD31). El nivel de significación se aceptó como $p < 0.05$.* **Resultados:** *Aflibercept redujo significativamente el volumen del implante endometrial ($p = 0.002$). La puntuación histológica epitelial (EHS) del explante mostró una diferencia significativa entre aflibercept y acetato de leuprolida ($p = 0.006$) y entre los grupos de aflibercept y control ($p = 0.002$). Aflibercept disminuyó la expresión de VEGF-H y CD31 ($p = 0.001$) más que el acetato de leuprolida. Aflibercept mejoró las adherencias ($p = 0.006$).* **Conclusión:** *Aflibercept tiene más éxito que el acetato de leuprolide en el tratamiento de la endometriosis.*

Palabras clave: *Aflibercept. Acetato de leuprolida. Angiogénesis. Endometriosis. Factor de crecimiento del endotelio vascular.*

***Correspondence**
Caglayan Ates
E-mail: caglayanctf@hotmail.com

Date of reception: 15-02-2023
Date of acceptance: 13-05-2023
DOI: 10.24875/CIRUE.M23000605

Cir Cir (Eng). 2024;92(1):10-19
Contents available at PubMed
www.cirugiaycirujanos.com

2444-0507/© 2023 Academia Mexicana de Cirugía. Published by Permanyer. This is an open access article under the terms of the CC BY-NC-ND license (http://creativecommons.org/licenses/by-nc-nd/4.0/).

Introduction

Endometriosis is defined as the presence of a tissue similar to the endometrium at sites outside the uterine cavity[1]. It is difficult to determine the actual prevalence of endometriosis as it might be aymptomatic in some of the affected women and a biopsy is required for a definitive diagnosis. However, the prevalence among women of reproductive age is estimated to be 10%[2]. Endometriosis frequently presents itself with symptoms such as chronic pelvic pain, infertility, dysmenorrhea, dyspareunia, dysuria, dysgeusia, and fatigue and therefore might have a negative effect on physical, mental, sexual, or social life and productivity. Although the pathophysiology of endometriosis has not yet been fully understood, it is known to be closely related to inflammation and angiogenesis[3,4].

Angiogenesis is necessary for supplying nutrients required for implantation and invasion of endometriotic implants. Vascularization of lesions is mainly regulated by vascular endothelial growth factor (VEGF)[5]. Aflibercept is a recombinant fusion protein containing the second Ig domain and the third Ig domain of the VEGF receptors (VEGFR1 and VEGFR2, respectively), fused to the Fc portion of human immunoglobulin G1 (IgG1)[6-8]. It also binds to VEGF-A, VEGF-B, placental growth factor (PlGF)-1, and PlGF-2. Consequently, aflibercept acts as a trap for VEGFR by preventing the ligands from binding to their respective receptors, and it binds to both ends of VEGF very tightly[6,9]. This binding inhibits the biological action of VEGF and prevents the abnormal development of blood vessels. Aflibercept is also referred to in the literature as “VEGF trap”[7].

Aflibercept monotherapy is used in conjunction with chemotherapy as it significantly inhibits tumor growth and improves survival in various orthotropic animal models. It has been experimentally shown that aflibercept prevents and slows down the formation of choroidal neovascularization[10].

In this pioneering study, we aimed to evaluate the effect of aflibercept, a recombinant fusion protein that has an antiangiogenic effect by inhibiting VEGF on endometriotic foci, and compared the effect of aflibercept with leuprolide acetate, a GnRH agonist currently used in the routine treatment and the no-treatment group.

Materials and methods

The effects of the antiangiogenic agent aflibercept and a gonadotropin analog, leuprolide acetate, on ectopic endometrial lesions were compared to the control group in a rat model.

Ethical approval

This experiment was conducted in accordance with the standards of the Local Ethics Committee Directory of Turkish Ministry of Health, Health Sciences University Gülhane animal experiments. The experimental animals were obtained from Gülhane Experimental Animals Production and Research Unit. As recommended by the Gülhane Animal Studies Ethics Committee (03.03.21/ETİK-2021/07-21/09), a preliminary study was first conducted on two female rats for testing the experimental endometriosis model and the experiment was started after the success of the proposed model was confirmed and an approval from the *Gülhane Animal Studies Ethics Committee* was obtained (25.03.21/ETİK-2021/08-21/10).

Animals

A total of 30 female Wistar albino rats were included in the study. The 8-week-old rats, weighing 250-300 g, were kept in temperature-controlled cages throughout the study with standard rat chow and adequate water. During the day, each rat was kept in special standard cages at 21-24°C and 50% humidity. The automatic 12-h light-dark cycle was maintained. Rats were kept in the same cage for 20 days to ensure estrus.

Surgical procedures

Anesthesia was administered by intraperitoneal administration of 90 mg/kg ketamine hydrochloride (Ketalar; Eczacıbaşı Warner-Lambert pharmaceutical industry, Levent/İstanbul) and 10 mg/kg xylazine hydrochloride (Rompun-Bayer, Şişli/İstanbul) for the operations. In immobilized rats, the surgical area was shaved in the dorsal position and cleaned with povidone-iodine solution for antisepsis.

1ST OPERATION

A rat endometriosis model was developed by the surgical endometriosis induction method defined by Vernon and Wilson[11]. A 3-cm median skin incision was made while protecting the integrity of the intra-abdominal organs, and then, the uterine horns were exposed.

The right uterine horn was excised after ligating both the uterotubal junction and the cervix. The endometrial tissue inside the excised horn section was excised to a 5 × 5 mm piece and then implanted with 4-0 Vicryl sutures into the relatively vascular area on the ipsilateral inner lateral wall of the abdomen, with the endometrium facing the peritoneal surface. After the bleeding was controlled, 1 ml of saline was applied to the abdominal cavity, and the median incision was closed by continuous suturing using 3-0 Vicryl and prolene sutures according to the anatomic plan. Subsequently, all rats were transferred to the post-operative unit in separate cages. Paracetamol (Parol oral suspension; Atabay İlaç, Kadıköy/Istanbul) at a dosage of 100 mg/kg was given to the rats in 500 ml of water for pain control during the post-operative period. Routine daily feeding of the animals was continued during the following 3 weeks.

2ND OPERATION

Twenty-one days after the initial surgery, rats underwent exploratory laparotomy to evaluate endometriotic lesions. One rat died during this operation during anesthesia was given and was excluded from the study. In the remaining 29 rats, the development of endometriotic implants at the transplanted areas was confirmed. Then, the rats were randomly divided into three groups: aflibercept group (Af) n = 12, leuprolide acetate group (Le) n = 12, and the control group (Co) n = 5. The local ethics committee (25.03.21/ETIK-2021/08-21/10) recommended recruitment of a reduced number of rats to the control group. The rats were numbered according to the intra-group tail staining method. The volumes (0.52 × width [mm] × length [mm] × height [mm]) of all tissues transplanted in the abdominal wall 3 weeks before and changed into endometriotic structure were then measured (Fig. 1A). During the examination, intra-abdominal adhesions were scored according to the Blauer scoring system (0-4): 0 = no adhesion, 1 = weak adhesion, 2 = dense adhesion confined to a single area, 3 = dense adhesion over a large area, and 4 = strong adhesions including internal organs[12] (Fig. 1B and C). Surgery was completed with closure of the abdominal cavity with 3-0 Vicryl and prolene. Body weights of all rats were measured and 25 mg/kg aflibercept (Eylea®; Regeneron, NY, USA) was administered intraperitoneally (i.p.) in the Af group, and 1 mg/kg leuprolide acetate (Lucrin Depot; Abbott, Cedex, Istanbul) was administered subcutaneously (s.c.), Turkey, in the Le group. The doses were based on the studies from the literature[13,14]. The co-group received no treatment. The rats received the same post-operative pain control treatment and they were routinely followed up for 21 days until the third operation.

3RD OPERATION

A third laparotomy was performed 21 days after the exploratory laparotomy. During this operation, the diameters of endometriotic lesions were measured as done during the previous operation. The adhesions were scored again according to the "Blauer scoring system" for comparison with the pre-treatment scores[11]. The body weights of all rats were measured again. Subsequently, all rats were sacrificed by exsanguination. Blood samples collected were sent to the laboratory in tubes containing ethylenediaminetetraacetic acid (EDTA) for analysis. Finally, all endometriotic lesions were excised and sent to the pathology laboratory in containers containing 10% formaldehyde solution.

Histopathological evaluation

The excised endometriotic tissues were stored in containers containing 10% formaldehyde, numbered, and sent to the pathology laboratory of Gülhane Training and Research Hospital, where they were examined by the same pathologist (F.A.) who was blinded to the study groups. Sections of 5 μm (microns) were taken by the microtome (Leica-M225-Thermo HM3555-Thermo scientific). Sections stained with hematoxylin and eosin (H&E) were examined under a microscope (Nikon® ECLIPSE 80i, Japan) at ×100, ×200 and ×400 magnifications (Supplementary Figure 1). The persistence of endometrial cells within the endometrial implants was assessed by semiquantitative explant epithelial histological scoring (EHS) (score 0-3): 3 = a well-preserved epithelial layer, 2 = a moderately preserved epithelium with leukocyte infiltration, 1 = a poorly preserved epithelium (containing only occasional epithelial cells), and 0 = no epithelium[15]. The software "NIS-Elements D Ver 5.02.03 for 64-bit edition" was used for photographing from the microscope.

Immunohistochemical evaluation

Immunohistochemical staining was performed automatically using the Ventana BenchMark XT System (Ventana Medical Systems, Roche, Basel, Switzerland). Ultraview universal 3,3′-diaminobenzidine (DAB) detection kit (Ventana®)

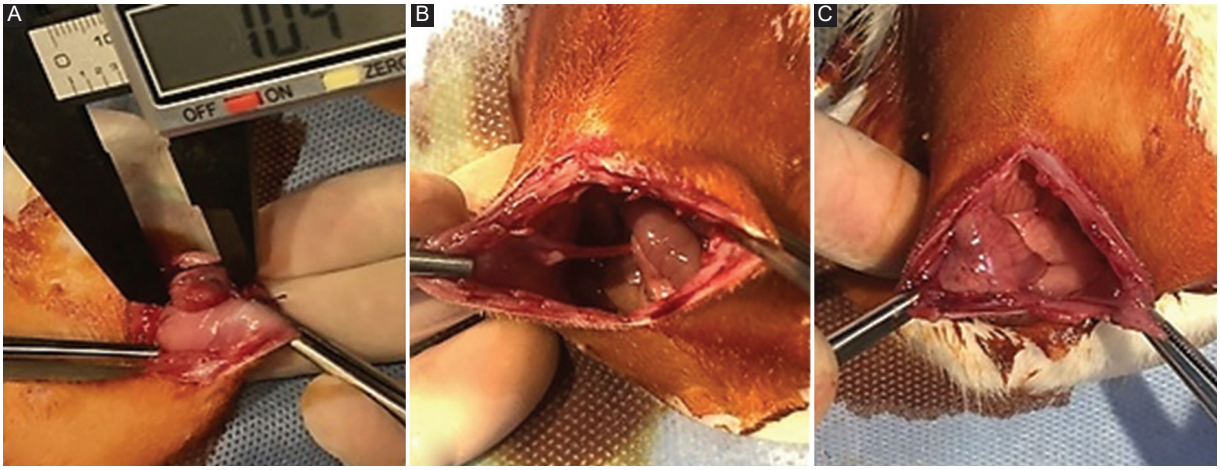

Figure 1. *Several images captured throughout the experiment.* **A:** *appearance compatible with endometriosis on exploration.* **B:** *example of Blauer adhesion score 1.* **C:** *example of Blauer adhesion score 4.*

was used for automatic immunohistochemistry device. The primary antibodies against VEGF (Flt-1/VEGFR1, 0.1 ml concentrate 1:501:200 antibody, GenomeME, Richmond BC, Canada) and CD31 (JC70, 0.1 ml concentrate 1:251:100 antibody, Santa Kruz) were used. The slides were evaluated under the microscope, with histological scoring (H-score) for VEGF as previously described in the literature[16-18]: H-score = $\sum$Pi i = 0 (negatively stained cells) to i = 3 (highly stained cells), P = 1, 2, 3, 4, 5 values < 15%, 15-50%, 50-85%, > 85%, and 100% positively stained cells, respectively. For the CD31 antibody, the number of CD31-positive stained microvessels (endothelial cells/endothelial cell clusters) was calculated per 1 mm^2 area[5].

Blood parameters

Intracardiac blood samples collected during the sacrifice phase by exsanguination were transferred to EDTA tubes. Unfortunately, clotting abnormalities occurred in 4 tubes (1 tube from the Af group, 2 tubes from the Le group, and 1 tube from the Co group) and these tubes were excluded from the study. The remaining 25 blood samples were sent to laboratory for analysis. An automatic analyzer was used to determine the hemoglobin level (HGB) (gr/dL), total white blood cell count (WBC) (× 10^3 μL), and platelet count (PLT) (× 10^\mm^3), which are among the laboratory complete blood count parameters (Mindray BC-6000).

Statistical analysis

The sample size of the study was calculated by G-power analysis, and the number of rats required for the study was set at 30. Normality assumptions of the continuous variables were tested using the Shapiro–Wilk test. The mean ± standard deviation of the normally distributed variables and the median values (25th-75th percentiles) of the non-normally distributed variables are indicated. The Wilcoxon signed-rank test was used to compare the parameters of the rats before and after treatment. One-way analysis of variance (one-way ANOVA) was used to compare the normally distributed parameters between groups. In case of a significant difference, the *post hoc* Tukey or Games-Howell test was used according to the result of Levene's test for homogeneity of variance. The Kruskal–Wallis test was used to compare the parameters that were not normally distributed between groups. In the case of a significant difference, the Mann–Whitney test with Bonferroni correction was used to determine from which groups the difference originated. IBM SPSS 25 program was used in all analyses, and $p < 0.05$ was accepted as the significance level.

Results

Weight of the rats and volume of the endometriotic tissue measured at the time of the 2nd and 3rd operations (pre and post-treatment) were compared in the Af, Le, and the control groups. The post-treatment weight of both the Co group and the Af group was significantly lower than that of the Le group ($p < 0.001$) (Table 1). The weight of the rats increased significantly in all groups; 14.89% in the Co group, 8.3% in the Af group, and 27.7% in the Le group (Table 1). However,

Table 1. Comparison of groups in terms of weight, endometriotic lesion width, length, height, volume, and Blauer adhesion score

Variables	Group Co (n = 5)	Group Af (n = 12)	Group Le (n = 12)	p value	Difference among groups
Weight (gr)					
Before treatment	235.00 (215.00-242.50)	242.50 (235.00-253.75)	235.00 (235.00-247.50)	0.282†	-
Post-treatment	270.00 (245.00-277.50) c	262.50 (255.00-273.75) a	300.00 (290.00-305.00) b	**< 0.001**†	**a < b; c < b**
p value	**0.042***	**0.002***	**0.002***		
Endometriotic lesion width (mm)					
Before treatment	6.00 (4.00-8.00)	9.00 (5.40-9.10)	5.55 (3.80-6.68)	0.153†	-
Post-treatment	8.60 (6.15-10.05)	5.60 (2.95-7.15)	5.00 (3.58-5.52)	0.067†	-
p value	**0.043***	**0.002***	**0.036***		
Endometriotic lesion length (mm)					
Before treatment	4.00 (2.15-5.05) c	7.40 (5.55-8.00) a	4.45 (2.82-5.23) b	**0.004**†	**b < a; c < a**
Post-treatment	4.50 (3.05-6.55)	4.65 (4.00-6.30)	3.45 (2.58-4.40)	0.175†	-
p value	**0.042***	**0.012***	**0.006***		
Endometriotic lesion height (mm)					
Before treatment	1.50 (1.25-2.45) c	3.65 (2.90-4.57) a	2.05 (1.45-2.88) b	**0.002**†	**b < a; c < a**
Post-treatment	2.50 (1.65-5.10)	1.85 (1.55-2.08)	1.50 (1.00-2.50)	0.230†	-
p value	**0.043***	**0.002***	**0.016***		
Endometriotic lesion volume (mm^3)					
Before treatment	18.00 (10.00-35.50) c	134.50 (59.75-170.25) a	21.00 (15.25-46.75) b	**0.013**†	**b < a**
Post-treatment	78.00 (24.50-107.50)	27.50 (10.75-43.00)	12.50 (7.00-27.25)	0.106†	-
p value	**0.043***	**0.002***	0.084*		
Blauer adhesion score					
Before treatment	2.00 (1.00-2.00)	2.00 (2.00-3.00)	2.00 (2.00-3.00)	0.145†	-
Post-treatment	2.00 (1.50-3.50)	1.00 (1.00-2.00)	2.00 (1.00-4.00)	0.091†	-
p value	0.102*	**0.006***	1.000*		

*Wilcoxon signed-rank test.
†Kruskal–Wallis test.
gr: grams; mm: millimeters; mm^3: cubic millimeters.
Blauer adhesion score; (0-4): 0 = no adhesion; 1 = weak adhesion; 2 = dense adhesion limited to a single area; 3 = dense adhesion over a large area; 4 = dense adhesion involving internal organs.
Parameters are expressed as mean±standard deviation or median (25th-75th percentile) taking into account normality assumptions. Values in bold are statistically significant.

the increase in weight was statistically significant in the Af and Le groups. The endometriotic foci volume of the Co group was found to be increased by 333.3% during the 3rd operation. However, the volume of the endometriotic foci was found to be decreased by 40.4% in the Le group and 79.5% in the Af group. Although endometriotic foci volume regressed in both Af and Le groups, the reduction in the Af group was statistically significantly higher (p = 0.002) (Table 1).

Intraabdominal Blauer adhesion scores of the three groups recorded during the 2nd and 3rd operations were compared. No change in the Blauer adhesion score was observed in the Le and Co groups, while there was a statistically significant decrease in Blauer score after treatment with Af (p = 0.006) (Table 1).

Histology of the excised endometriotic tissue obtained during the 3rd operation and the immunohistochemical assessment of VEGF and CD31 expression in excised tissues were compared in the control group with the two intervention groups (Table 2). Explant epithelial histological scoring (EHS) difference among groups was significant (p = 0.002) (Table 2). When the persistence of endometrial cells within the endometrial implants was assessed by semiquantitative explant EHS, none of the specimens in the intervention and control groups had a score of 0. In the control group, 40% had a score of 2 and 60% had a score of 3. In the Le group, the distribution of the scores 1, 2, and 3 was 25.0%, 16.7%, and 58.3%, respectively. In the Af group, none of the specimens had a score of 3, 75% received a score of 1 while the remaining 25% had a score of 2 (Table 3). According to Chi-square analysis, when three groups were compared, the p value was 0.07 (Table 3). When the median EHS scores were compared, there was a significant

Table 2. Comparison of groups in terms of explant epithelial histological score, VEGF H score, and CD31 expression

Variables	Group Co (n = 5)	Group Af (n = 12)	Group Le (n = 12)	p value	Difference among groups
EHS	3.00 (2.00-3.00) c	1.00 (1.00-1.75) a	3.00 (1.25-3.00) b	**0.002***	a < b **(p = 0.006)**† a < c **(p = 0.002)**†
CD31	154.00 (105.50-286.50) c	75.50 (62.25-85.00) a	144.00 (112.75-198.25) b	**< 0.001***	a < b **(p < 0.001)**† a < c **(p = 0.001)**†
VEGF	6.00 (6.00-6.00) c	2.00 (2.00-3.00) a	4.00 (2.00-6.00) b	**0.002***	a < c **(p = 0.001)**†

*Kruskal–Wallis test.
†Mann–Whitney test with Bonferroni correction.
EHS: Explant epithelial histological scoring "semi-quantitative" (0-3); 0: no epithelium, 1: poorly preserved (only occasionally) epithelium, 2: moderately preserved epithelium with leukocyte infiltrates, 3: well-preserved epithelial layer; CD31: microvessel density; The number of CD31 positive-stained microvessels (endothelial cell/endothelial cell clump) per 1 mm^2 area; VEGF: H score = $\sum Pi$; i = 0 (stained negatively) to 3 (stained heavily), P = 1, 2, 3, 4, 5 values < 15%, 15-50%, 50-85%, > 85%, and 100%, respectively, positively stained cells. Parameters are expressed as mean±standard deviation or median (25th-75th percentile) taking into account the assumptions of normality.
a: median value for the Af group (25th-75th percentile), b: median value for the Le group (25th-75th percentile), c: median value for the control group (25th-75th percentile).

Table 3. Distribution of explant epithelial histological scores in Study Groups

Groups	Score 0	Score 1	Score 2	Score 3	p value
Number of EHS					**0.007***
Group Af	-	9 (75.0%)	3 (25.0%)	-	
Group Le	-	3 (25.0%)	2 (16.7%)	7 (58.3%)	
Group Co	-	-	2 (40.0%)	3 (60.0%)	

*Chi-square analysis.
Group Le < group Af at score 1 (p < 0.001); group Le < group Co at score 2 (p < 0.001).
EHS: explant epithelial histological scoring "semi-quantitative" (0-3); 0: no epithelium, 1: poorly preserved (only occasionally) epithelium, 2: moderately preserved epithelium with leukocyte infiltrates, 3: well-preserved epithelial layer.
Number of EHS: it refers to the number of rats in the score groups according to the EHS. Values in bold are statistically significant.

difference between the groups, and Af group had the lowest median score when compared to Le and Co groups. (p = 0.002). The Bonferroni-corrected Mann–Whitney test showed a significant difference between the Af group and the Le group (p = 0.006) and between the Af group and the Co group (p = 0.002) (Table 2).

When glandular, stromal, and epithelial cells were stained for calculation of microvessel density for the VEGF-H immunohistochemical score and CD31 antibody evaluation, Co group was found to have a stronger staining in comparison to the Af and Le groups. In the Af group, staining for both VEGF and CD31 antibodies was much weaker than that observed in the Co and Le groups (Fig. 2). Counting CD31 and VEGF-H scores revealed a significant difference between the groups (p < 0.001 and p = 0.002, respectively) (Table 2 and Fig. 3). In the Bonferroni-corrected Mann–Whitney test, both CD31 and VEGF H scores were significantly lower in the Af group than the Co group (p = 0.001) and the Le group (p < 0.001) (Table 2).

Out of the 29 blood samples obtained during the 3rd operation, four samples could not be processed due to the hemolysis. Analysis from the remaining samples (Co group: [n = 4], Af group: n = 11, Le group: n = 10) demonstrated no significant difference between the three groups in terms of WBC counts and hemoglobin levels. The platelet counts in Af, Le, and Co groups (median [25th-75th percentile]) were 999.50 (R: 886.75-1002.25) × 10^3 μL, 978.00 (R: 936.00-993.75) × 10^3 μL, and 870.00 (R: 805.00-890.50) × 10^3 μL, respectively. The Kruskal–Wallis test revealed a significant difference in the platelet counts among the groups (p = 0.032) (Table 4).

Discussion

Although more than a decade passed since the universally accepted definition of endometriosis, there is not a consensus about the pathogenesis and a set protocol for the diagnosis and treatment of this disease[19]. Endometriosis has a negative impact on education, employment, and social relations of the women of reproductive age due to its effect on physical, sexual, and reproductive health and thus is called as a "social disease"[20,21]. The researchers working in this field have proposed different theories for the explanation of various forms of endometriosis.

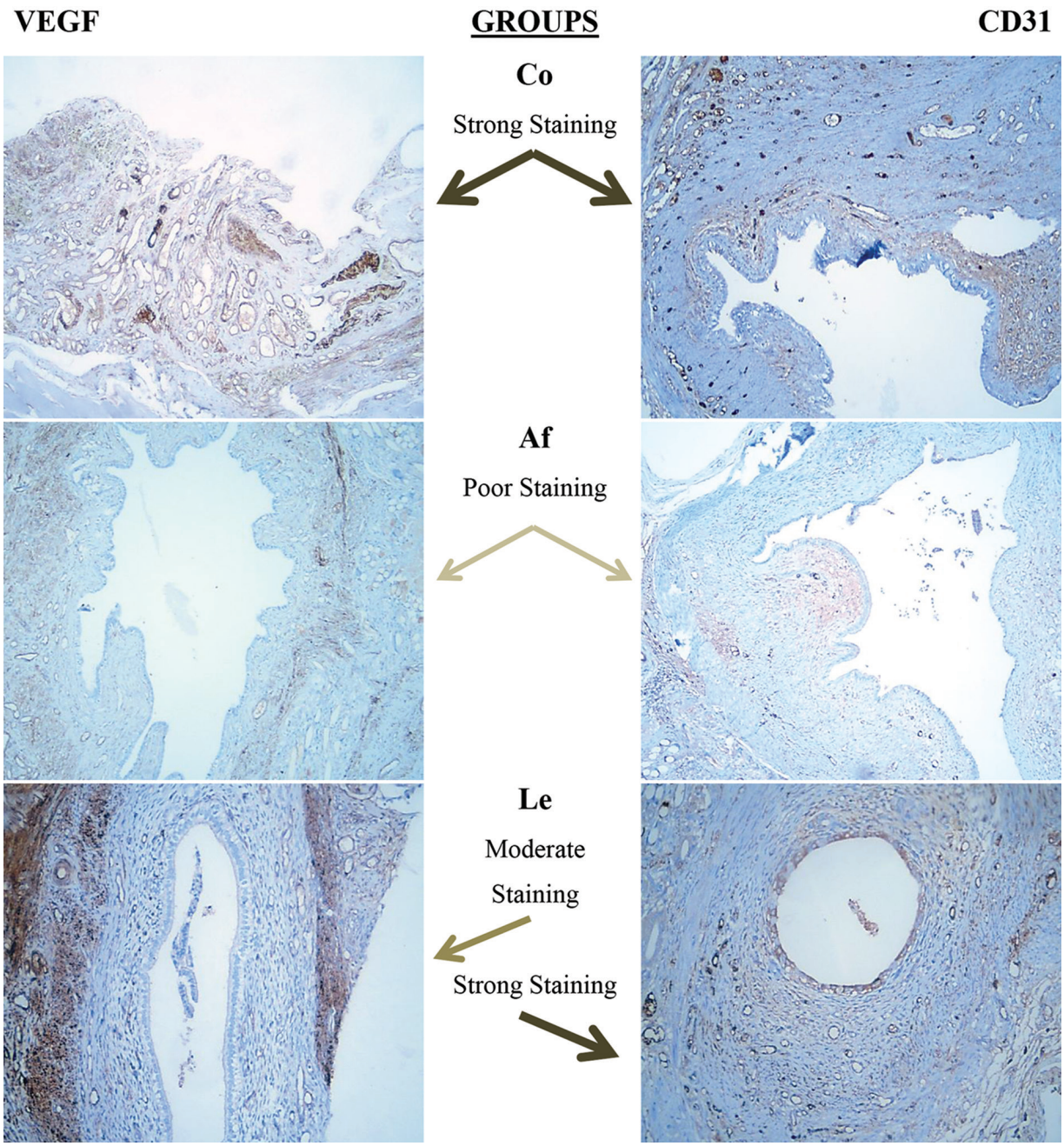

Figure 2. *Immunohistochemical examination of endometriotic lesions. Image for Group Co CD31 is at ×100 magnification. All other images are at ×200 magnification. VEGF: vascular endotelial growth factor.*

Besides lymphangiogenesis and neurogenesis, angiogenesis plays an important role in the pathophysiology of endometriosis[22]. The nutrients and oxygen required for the development of endometriotic lesions are provided by angiogenesis and thus neovascularization[23]. The presented study is a pioneering study that aims to investigate aflibercept, an antiangiogenic agent in the treatment of endometriosis in a surgically induced rat model. In the present study, aflibercept was more efficient in the regression of endometriotic lesions and treating adhesions than the control group and the leuprolide acetate group.

Changes in implant volume have been reported mostly as a marker for treatment efficacy of induced endometriotic foci in animal studies[24,25]. Bakacak et al. reported a significant reduction in the endometrial implant volume after treatment with the antiangiogenic agent thalidomide ($p = 0.001$)[26]. Aflibercept group had

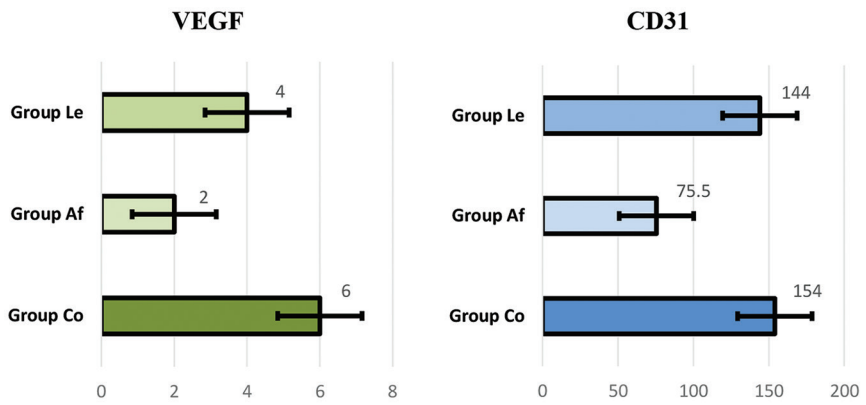

Figure 3. *Results of CD31 and vascular endothelial growth factor H score by groups. CD31: microvessel density: number of CD31-positive stained microvessels (endothelial cell/endothelial cell clump) per 1 mm²; VEGF: H score = ∑Pi; i = 0 (stained negatively) to 3 (stained heavily), p = 1, 2, 3, 4, 5 values < 15%, 15-50%, 50-85%, > 85%, and 100, respectively, % positively stained cells.*

Table 4. Comparison of intra-group and inter-group blood parameters

Parameters	Group Co (n = 4)	Group Af (n = 11)	Group Le (n = 10)	p value	Difference among groups
WBC (× 10^3 µL)	5196.00±930.61	6870.00±1552.26	7870.00±2531.40	0.061*	-
HGB (gr/dL)	13.38±0.36	13.94±0.27	14.06±0.79	0.097*	-
PLT (× 10^\mm^3)	870.00 (805.00-890.50) c	999.50 (886.75-1002.25) a	978.00 (936.00-993.75) b	**0.032**†	**c < b** **c < a**

*One-way ANOVA analysis.
†Kruskal–Wallis test.
WBC: white blood cell count; HGB: amount of hemoglobin; PLT: platelet count.
Parameters are expressed as mean±standard deviation or median (25th-75th percentile) taking into account normality assumptions. Values in bold are statistically significant.

a significant reduction in the volume of the endometriotic implants (p = 0.002) (Table 1). The significant increase in the total body weight of the rats in all groups after treatment could be speculated as the rats being in their growth period during the experimental study. However, the weight gain in the group receiving leuprolide acetate was more significant than the other groups (Table 1).

Ozer et al. analyzed and compared the effect of two antiangiogenic agents – bevacizumab and sorafenib on the volume of the endometriotic foci[5] and the changes in VEGF and CD31.The reported results of this study were similar to our results. In contrast, Ozer et al. observed that sorafenib cleared some endometriotic lesions entirely. For aflibercept, we did not meet such a circumstance in our research. They compared two anti-angiogenic drugs while in the present study, the efficacy of aflibercept; an antiangiogenic drug was compared with a GnRH agonist leuprolide acetate in the treatment of endometriosis. Because, in addition to its hypoestrogenic impact, leuprolide acetate has a demonstrated anti-VEGF activity[27]. In our study, with leuprolide acetate, VEGF expression decreased when compared with the control group but this decrease was not significant. In our study, aflibercept statistically significantly reduced VEGF expression. This indicates that aflibercept has a stronger antiangiogenic effect than leuprolide acetate.

Adhesion formation was decreased with two anti-VEGF agents bevacizumab[28] and sunitinib[29] in two animal studies presented by Moraloglu and Pala. According to the Blauer scoring system, we also found that aflibercept reduced adhesion after treatment. Consistent with the literature our study demonstrated that anti-VEGF agents have a reducing effect on adhesions.

Siracusa et al observed to have a significant reduction in both markers of angiogenesis – VEGF and CD34 expression on the endometriotic surfaces with another anti-VEGF agent, rapamycin[30]. In the present study, besides VEGF expression levels, another endothelial marker, CD31 was also evaluated in the endometriosis rat model and the findings with aflibercept were similar to those obtained with rapamycin.

Zhang et al studied rosiglitazone, an antiangiogenic PPARγ (peroxisome proliferator-activated receptor γ) agonist that acts by inhibiting macrophage activation in endometriotic lesions in a surgically induced rat model[4]. The expression of VEGF and caspase-3 immunohistochemically in endometriotic tissue was evaluated, and expression of VEGF and caspase-3 was significantly reduced by rosiglitazone ($p < 0.05$, $p < 0.05$)[4]. Zhang et al. compared rosiglitazone with the control (no treatment) and saline groups without comparing it with any other agent currently being used in the treatment of endometriosis. In the present study, the efficacy of aflibercept was compared with leuprolide acetate in a rat model, to demonstrate its potential in comparison to an agent that has been currently being used.

Yıldız et al. studied imatinib, a tyrosine kinase receptor inhibitor, and obtained a significant improvement ($p < 0.05$) compared with the control group using VEGF-H score system[31]. However, in our study, aflibercept reduced VEGF expression more prominently, therefore it can be speculated that the antiangiogenic effect of aflibercept might be stronger that of imatinib ($p = 0.01$).

In the study performed by Ozdemir et al on ranibizumab which has an antiangiogenic effect, the percentage of specimens with an epithelial histological score of 0 was 33.3%. In our study, there were no specimens in any of the groups with a score of 0; however, the rates of the other scores were similar. Ozdemir et al reported score 1 in 66.7% of the ranibizumab-treated group[32]. In our study, 75% of the aflibercept group received a score of 1. This suggests that aflibercept does not completely eradicate endometriotic lesions but can destroy the protective epithelium of the lesion similar to ranibizumab.

It is well known that antiangiogenic agents may cause thromboembolic complications[30]. In the present study, the blood samples taken at the final phase of the study were analyzed and complete blood count results showed that the platelet count was higher in the aflibercept group than in the other groups. This result was significant when compared with the control group but not significant compared with the leuprolide acetate group. These findings suggest that aflibercept may cause thrombocytosis.

Studies with experimental animals cannot be directly applied to humans. Therefore, acceptance of aflibercept as a treatment option for endometriosis depends on more comprehensive animal studies and clinical studies. Any results we obtained should be carefully evaluated because the number of rats was restricted due to the regulations of the local ethics committee for animal studies and the parameters studied to determine the side effect profile were limited.

Conclusion

It is necessary to suppress the process of angiogenesis to achieve effective results in the treatment of endometriosis. The anti-angiogenic agent aflibercept was used for the first time in the present study for the treatment of endometriosis. Aflibercept proved more successful than the control group and leuprolide acetate in both regression of endometriotic lesions and treatment of adhesions.

Funding

The University of Health Sciences Scientific Research Projects Unit funded this study as part of a medical specialty thesis (project number: 2021/122). Author B.D. has received research support from The University of Health Sciences Scientific Research Projects Unit.

Conflicts of interest

The authors declare that they have no conflicts of interest.

Ethical disclosures

Protection of human and animal subjects. The authors declare that the procedures followed were in accordance with the regulations of the relevant clinical research ethics committee and with those of the Code of Ethics of the World Medical Association (Declaration of Helsinki).

Confidentiality of data. The authors declare that no patient data appear in this article.

Right to privacy and informed consent. The authors declare that no patient data appear in this article.

Supplementary data

Supplementary data are available at DOI: 10.24875/CIRUE.M23000605. These data are provided by the corresponding author and published online for the benefit of the reader. The contents of supplementary data are the sole responsibility of the authors.

References

1. Samartzis EP, Labidi-Galy SI, Moschetta M, Uccello M, Kalaitzopoulos DR, Perez-Fidalgo JA, et al. Endometriosis-associated ovarian carcinomas: insights into pathogenesis, diagnostics, and therapeutic targets-a narrative review. Ann Transl Med. 2020;8:1712.
2. Zondervan KT, Becker CM, Missmer SA. Endometriosis. N Engl J Med. 2020;382:1244-56.

3. Alborzi S, Azimirad A, Azimirad M. Experimental endometriosis: review of the literature through a century and the Iranian experience. Arch Iran Med. 2018;21:536-43.
4. Zhang S, Zhuang L, Liu Q, Yu X, Min Q, Chen M, et al. Rosiglitazone affects the progression of surgicallyinduced endometriosis in a rat model. Mol Med Rep. 2021;23:35.
5. Ozer H, Boztosun A, Açmaz G, Atilgan R, Akkar OB, Kosar MI. The efficacy of bevacizumab, sorafenib, and retinoic acid on rat endometriosis model. Reprod Sci. 2013;20:26-32.
6. Ciombor KK, Berlin J, Chan E. Aflibercept. Clin Cancer Res. 2013;19:1920-5.
7. Sarwar S, Clearfield E, Soliman MK, Sadiq MA, Baldwin AJ, Hanout M, et al. Aflibercept for neovascular age-related macular degeneration. Cochrane Database Syst Rev. 2016;2:CD011346.
8. Avery RL, Castellarin AA, Steinle NC, Dhoot DS, Pieramici DJ, See R, et al. Systemic pharmacokinetics and pharmacodynamics of intravitreal aflibercept, bevacızumab, and ranibizumab. Retina. 2017;37: 1847-58.
9. Azanza Perea JR, Sádaba B. Aflibercept. An approach to pharmacology. Arch Soc Esp Oftalmol. 2015;90 Suppl 1:6-10.
10. Stewart W. Aflibercept (VEGF-TRAP): the next anti-VEGF drug. Inflamm Allergy Drug Targets. 2011;10:497-508.
11. Vernon MW, Wilson EA. Studies on the surgical induction of endometriosis in the rat. Fertil Steril. 1985;44:684-94.
12. De Iaco PA, Stefanetti M, Pressato D, Piana S, Doná M, Pavesio A, et al. A novel hyaluronan-based gel in laparoscopic adhesion prevention: preclinical evaluation in an animal model. Fertil Steril. 1998;69:318-23.
13. Kiykac Altinbas S, Tapisiz OL, Cavkaytar S, Simsek G, Oguztuzun S, Goktolga U. Is montelukast effective in regression of endometrial implants in an experimentally induced endometriosis model in rats? Eur J Obstet Gynecol Reprod Biol. 2015;184:7-12.
14. Forsgård RA, Marrachelli VG, Lindén J, Frias R, Collado MC, Korpela R, et al. Two-week aflibercept or erlotinib administration does not ınduce changes in intestinal morphology in male sprague-dawley rats but aflibercept affects serum and urine metabolic profiles. Transl Oncol. 2019;12:1122-30.
15. Keenan JA, Williams-Boyce PK, Massey PJ, Chen TT, Caudle MR, Bukovsky A. Regression of endometrial explants in a rat model of endometriosis treated with the immune modulators loxoribine and levamisole. Fertil Steril. 1999;72:135-41.
16. Donnez J, Smoes P, Gillerot S, Casanas-Roux F, Nisolle M. Vascular endothelial growth factor (VEGF) in endometriosis. Hum Reprod. 1998;13:1686-90.
17. Hagedorn A, Germann PG, Junker-Walker U, Tomovic A, Seewald W, Polkinghorne A, et al. Immunohistochemical study about the Flt-1/VEGFR1 expression in the gastrointestinal tract of mouse, rat, dog, swine and monkey. Exp Toxicol Pathol. 2005;57:149-59.
18. Miettinen M, Lindenmayer AE, Chaubal A. Endothelial cell markers CD31, CD34, and BNH9 antibody to H-and Y-antigens--evaluation of their specificity and sensitivity in the diagnosis of vascular tumors and comparison with von Willebrand factor. Mod Pathol. 1994;7:82-90.
19. Burns KA, Pearson AM, Slack JL, Por ED, Scribner AN, Eti NA, et al. Endometriosis in the mouse: challenges and progress toward a 'Best Fit' murine model. Front Physiol. 2021;12:806574.
20. La Rosa VL, De Franciscis P, Barra F, Schiattarella A, Török P, Shah M, et al. Quality of life in women with endometriosis: a narrative overview. Minerva Med. 2020;111:68-78.
21. Simoens S, Dunselman G, Dirksen C, Hummelshoj L, Bokor A, Brandes I, et al. The burden of endometriosis: costs and quality of life of women with endometriosis and treated in referral centres. Hum Reprod. 2012;27:1292-9.
22. Hey-Cunningham AJ, Peters KM, Zevallos HB, Berbic M, Markham R, Fraser IS. Angiogenesis, lymphangiogenesis and neurogenesis in endometriosis. Front Biosci (Elite Ed). 2013;5:1033-56.
23. Hung SW, Zhang R, Tan Z, Chung JP, Zhang T, Wang CC. Pharmaceuticals targeting signaling pathways of endometriosis as potential new medical treatment: a review. Med Res Rev. 2021;41:2489-564.
24. Soysal D, Kızıldağ S, Saatlı B, Posacı C, Soysal S, Koyuncuoğlu M, et al. A novel angiogenesis inhibitor bevacizumab induces apoptosis in the rat endometriosis model. Balkan J Med Genet. 2014;17:73-80.
25. Karslıoglu T, Karasu AF, Yildiz P. The effects of micronized progesterone and cabergoline on a rat autotransplantation endometriosis model: A placebo controlled randomized trial. J Invest Surg. 2021;34:897-901.
26. Bakacak M, Ercan Ö, Köstü B, Bostancı MS, İnanç F, Yaylalı A, et al. The effects of thalidomide in a rat model of surgically-induced endometriosis. Turk J Obstet Gynecol. 2015;12:125-31.
27. Meresman GF, Bilotas MA, Lombardi E, Tesone M, Sueldo C, Barañao RI. Effect of GnRH analogues on apoptosis and release of interleukin-1beta and vascular endothelial growth factor in endometrial cell cultures from patients with endometriosis. Hum Reprod. 2003;18:1767-71.
28. Moraloglu O, Işik H, Kiliç S, Sahin U, Caydere M, Ustün H, et al. Effect of bevacizumab on post-operative adhesion formation in a rat uterine horn adhesion model and the correlation with vascular endothelial growth factor and Ki-67 immunopositivity. Fertil Steril. 2011;95:2638-41.
29. Pala HG, Erbas O, Pala EE, Artunc Ulkumen B, Akman L, Akman T, et al. The effects of sunitinib on endometriosis. J Obstet Gynaecol. 2015;35:183-7.
30. Siracusa R, D'Amico R, Impellizzeri D, Cordaro M, Peritore AF, Gugliandolo E, et al. Autophagy and mitophagy promotion in a rat model of endometriosis. Int J Mol Sci. 2021;22:5074.
31. Yildiz C, Kacan T, Akkar OB, Karakus S, Seker M, Kacan SB, et al. Effect of imatinib on growth of experimental endometriosis in rats. Eur J Obstet Gynecol Reprod Biol. 2016;197:159-63.
32. Ozdemir EU, Adali E, Taskin MI, Yavasoglu A, Aktug H, Oltulu F, et al. Effects of ranibizumab and zoledronic acid on endometriosis in a rat model. Arch Gynecol Obstet. 2022;305:267-74.