Check for updates

ORIGINAL ARTICLE

The clinical effect of minimally invasive stereotactic puncture intracranial hematoma removal in the treatment of patients with cerebral hemorrhage: a meta-analysis

Efecto clínico de la extracción de haematoma intracraneal con punción mínimamente invasiva estereotáctica en el tratamiento de pacientes con hemorragia cerebral: un metanálisis

*Chao Gu, JunJie Lv, and DongHai Yuan**

Department of Neurosurgery, Zhuji People's Hospital of Zhejiang Province, Zhuji, China

Abstract

Objective: *The objective of the study was to systemically evaluate the clinical efficacy of minimally invasive stereotactic puncture for intracranial hematoma evacuation in patients with cerebral hemorrhage.* **Materials and Methods:** *Relevant studies in PubMed, Web of Science, MEDLINE, China National Knowledge Infrastructure, Wanfang, and VIP databases were searched. A meta-analysis was performed following the inclusion and exclusion criteria screening, data extraction, and literature quality evaluation.* **Results:** *Fifteen studies involving 1312 patients were included with 673 participants in the experimental group and 639 in the control group. The results of the meta-analysis showed that, compared with traditional craniotomy or treatment, minimally invasive stereotactic puncture intracranial hematoma removal had a higher clinical total effective rate in patients with cerebral hemorrhage, an outcome that could significantly shorten the hospitalization time of patients with cerebral hemorrhage. The level of post-operative activities of daily living was significantly higher, the incidence of postoperative complications was lower, and the mortality rate was lower. However, there was no significant difference in the degree of post-operative neurological deficit.* **Conclusion:** *Compared with traditional craniotomy or conservative treatment, minimally invasive stereotactic puncture intracranial hematoma removal has a higher clinical efficacy in the treatment of patients with cerebral hemorrhage, which can improve the post-operative daily life and abilities of patients.*

Keywords: *Guided stereotactic. Intracranial hematoma. Cerebral hemorrhage.*

Resumen

Objetivo: *Evaluación sistemática de la eficacia clínica de la punción estereotáctica mínimamente invasiva para la evacuación de hematomas intracraneales en pacientes con hemorragia cerebral.* **Material y métodos:** *Se realizaron búsquedas en estudios relevantes en PubMed, Web of Science, MEDLINE, Infraestructura Nacional de Conocimiento de China, base de datos Wanfang y base de datos VIP. El metanálisis se realizó después de la selección de criterios de inclusión y exclusión, la extracción de datos y la evaluación de la calidad de la literatura.* **Resultados:** *Se incluyeron 15 estudios en los que participaron 1.312 sujetos, 673 en el grupo experimental y 639 en el grupo control. En comparación con la Craneotomía tradicional o el tratamiento, el aclaramiento estereotáctico mínimamente invasivo de hematomas intracraneales tiene una alta eficiencia clínica total en pacientes con hemorragia intracerebral y puede acortar significativamente el tiempo de hospitalización*

***Correspondence:**
DongHai Yuan
E-mail: yuandhmm123@163.com

Date of reception: 06-09-2022
Date of acceptance: 01-02-2023
DOI: 10.24875/CIRUE.M23000768

Cir Cir (Eng). 2023;91(6):744-754
Contents available at PubMed
www.cirugiaycirujanos.com

2444-0507/© 2023 Academia Mexicana de Cirugía. Published by Permanyer. This is an open access article under the terms of the CC BY-NC-ND license (http://creativecommons.org/licenses/by-nc-nd/4.0/).

de los pacientes con hemorragia intracerebral. El nivel de actividad de la vida diaria postoperatoria (ADL) aumentó significativamente, la incidencia de complicaciones postoperatorias disminuyó y la mortalidad disminuyó. Sin embargo, no hubo diferencia significativa en el grado de déficit neurológico postoperatorio. **Conclusión:** *En comparación con la Craneotomía tradicional o el tratamiento conservador, la Craneotomía estereotáctica mínimamente invasiva tiene un mayor efecto clínico en el tratamiento de la hemorragia cerebral y puede mejorar la capacidad de la vida diaria de los pacientes después de la operación.*

Palabras clave: *Orientación estereotáctica. Hematoma intracraneal. Hemorragia cerebral.*

Introduction

Cerebral hemorrhage is one of the most common neurological diseases. With the growing ageing population in China, the incidence of cerebral hemorrhage has increased yearly[1]. The incidence of intracerebral hemorrhage is 12-15/100,000 person/year. In Western countries, intracerebral hemorrhage accounts for approximately 15% of all strokes and 10-30% of all hospitalized stroke patients. The proportion of intracerebral hemorrhage is higher in China, accounting for 18.8-47.6% of stroke incidences[2]. It is characterized by critical onset, rapid development, and high mortality. Hypertension, hyperlipidemia and smoking are common risk factors for cerebral haemorrhage[3]. Patients with cerebral hemorrhage often suffer from disability, aphasia and other complications, which not only decrease their safety but also impose a significant burden on their families and society[4]. At present, minimally invasive surgery, craniotomy, conservative treatment, and drug therapy are mainly used to treat the disease in clinical practice, but different treatment methods have different levels of clinical efficacy. For example, the risk of a brain tissue injury during a craniotomy is significant, as is the risk of serious brain edema, and the mortality rate is also high[5]. Surgical treatment mainly includes craniotomy drilling hematoma aspiration, stereotactic hematoma evacuation and endoscopic and computed tomography (CT) intracerebral hematoma evacuation[6]. Minimally invasive stereotactic puncture evacuation of an intracranial hematoma is a new surgical method that combines stereotactic surgery with the minimally invasive evacuation of an intracranial hematoma. It establishes a brain coordinate system according to the principle of stereotactic geometric coordinates and installs a directional instrument on the patient's skull to achieve accurate localization of target lesions[7]. This method has to date been widely used in clinical practice. In this paper, evidence-based medicine was used to strictly evaluate and analyze existing literature reports, and the clinical efficacy, postoperative neurological deficits, activities of daily living (ADL), the incidence of complications and mortality of minimally invasive stereotactic puncture evacuation of intracranial hematoma and traditional craniotomy in the treatment of patients with cerebral hemorrhage were evaluated.

Materials and methods

Search strategy

Following the Preferred Reporting Items for Systematic Reviews and Meta-Analyses guidebook, a systematic literature search of the PubMed, MEDLINE, Web of Science, China National Knowledge Infrastructure, Wanfang and China Science and Technology Journal databases was performed from January 2010 to December 2021. A search strategy combining subject headings and free words was used. The search terms included *cerebral hemorrhage*, *cerebellar hemorrhage*, *intracerebral hemorrhage*, *ICH*, *stereotactic minimally invasive*, *minimal surgical procedures*, *frameless stereotactic*, *intracranial puncture*, *burr hole drainage*, *keyhole,* and *craniotomy surgery*. To avoid literature omission, we searched manually, reading the relevant systematic reviews to obtain related target literature on stereotactic hematoma evacuation and craniotomy hematoma evacuation in the treatment of patients with cerebral hemorrhage.

Inclusion and exclusion criteria

The study's inclusion criteria were as follows: (1) Chinese and English studies published in peer-reviewed journals; (2) randomized controlled trial or observational studies; (3) study participants aged ≥ 18 years; (4) patients with a cerebral hemorrhage or those diagnosed with a cerebral hemorrhage using a brain CT scan met the diagnostic criteria of the Chinese Guidelines for the Diagnosis and Treatment of Cerebral Haemorrhage (2019)[8]; (5) the location of bruises were

in the basal ganglia, suprauli, frontal lobe and occipital lobe, using minimally invasive stereotactic puncture; and (6) the case data in the literature were complete, and the main outcome measures included the overall clinical response rate, length of hospital stay, postoperative neurological deficit evaluation, postoperative ADL and the incidence of complications and mortality.

The study's exclusion criteria were as follows: (1) patients who had other causes of bleeding, including bleeding due to vascular abnormalities, for example, tumor bleeding, vascular malformations, aneurysms or vascular amyloidosis; (2) conference articles, systematic reviews and other types of literature; (3) articles with insufficient outcome information to extract data; and (4) articles that had been repeatedly published or were not available in full.

Study selection and data extraction

Two researchers independently screened the literature, performing preliminary screening using titles and abstracts and then reading the full text according to the inclusion and exclusion criteria for the secondary screening. When inconsistent opinions were encountered, the opinions of a third researcher were solicited and discussed to reach a unified agreement. After the literature screening, data extraction was performed independently by two researchers, and the extracted contents included the name of the first author, nationality and year of publication, the type of study, total sample size, hematoma evacuation time or hematoma elimination rate, operation time, length of hospital stay, postoperative neurological deficit evaluation, post-operative ADL, and any incidence of complications.

Quality evaluation

Two researchers independently performed the quality evaluation of the included literature. In case of disagreement, the opinion of a third researcher was solicited and discussed to reach a unified agreement. Randomized controlled trials were evaluated according to the Cochrane Handbook for Systematic Reviews 5.1.0[9]. This included the generation of random sequences, allocation concealment, the blinding of study participants and implementers, the blinding of outcome assessors, completeness of the outcome data and selective reporting of the study results and other sources of bias; each was evaluated as "low," "unclear" or "high" risk.

Statistical analysis

The Revman 5.3 software was used for statistical analysis. The effect size of measurement data was expressed as an odds ratio (OR), and the enumeration data were expressed as the standardized mean difference (SMD). Both indicators were used to estimate the interval range of the effect size with a 95% confidence interval (CI). If the original literature only provided median and range data; these were transformed into mean and standard deviation using a formula and included in the analysis. A heterogeneity evaluation was used to determine the size of heterogeneity using the I^2 test; if $I^2 < 50\%$ or $p > 0.1$, the included literature was considered homogeneous, and the Mantel-Haenszel was used for analysis assuming a fixed effect model. If $I^2 > 50\%$ or $p \leq 0.1$, the included studies were considered heterogeneous, and the DerSimonian-Laird random effect model was used for analysis. If the heterogeneity was large, sensitivity analysis or subgroup analysis was used to explore the source of heterogeneity. The test level of the meta-analysis was set as alpha = 0.05.

Results

Literature search results

A total of 384 relevant literature papers were retrieved for the current study. After the systematic search and screening of Chinese and English databases, 15 literature studies that met the criteria were finally included[10-24]. A flowchart of the literature retrieval and screening processes is shown in figure 1.

Basic characteristics of included studies and literature quality evaluation

Five studies were published from 2005 to 2015, and 10 were published from 2016 to 2021. Fifteen studies were from China, and they were all were randomized controlled studies. The total sample size of the 15 studies was 1312, with 673 in the experiment group and 639 in the control group. There were three high-quality, nine medium-quality and three low-quality articles. All of the randomized controlled trials stated that the principle of "randomization" had been followed, with one article not specifying a randomization scheme[10] and two articles not elaborating on neurological deficit scoring criteria[8,12]. These were evaluated

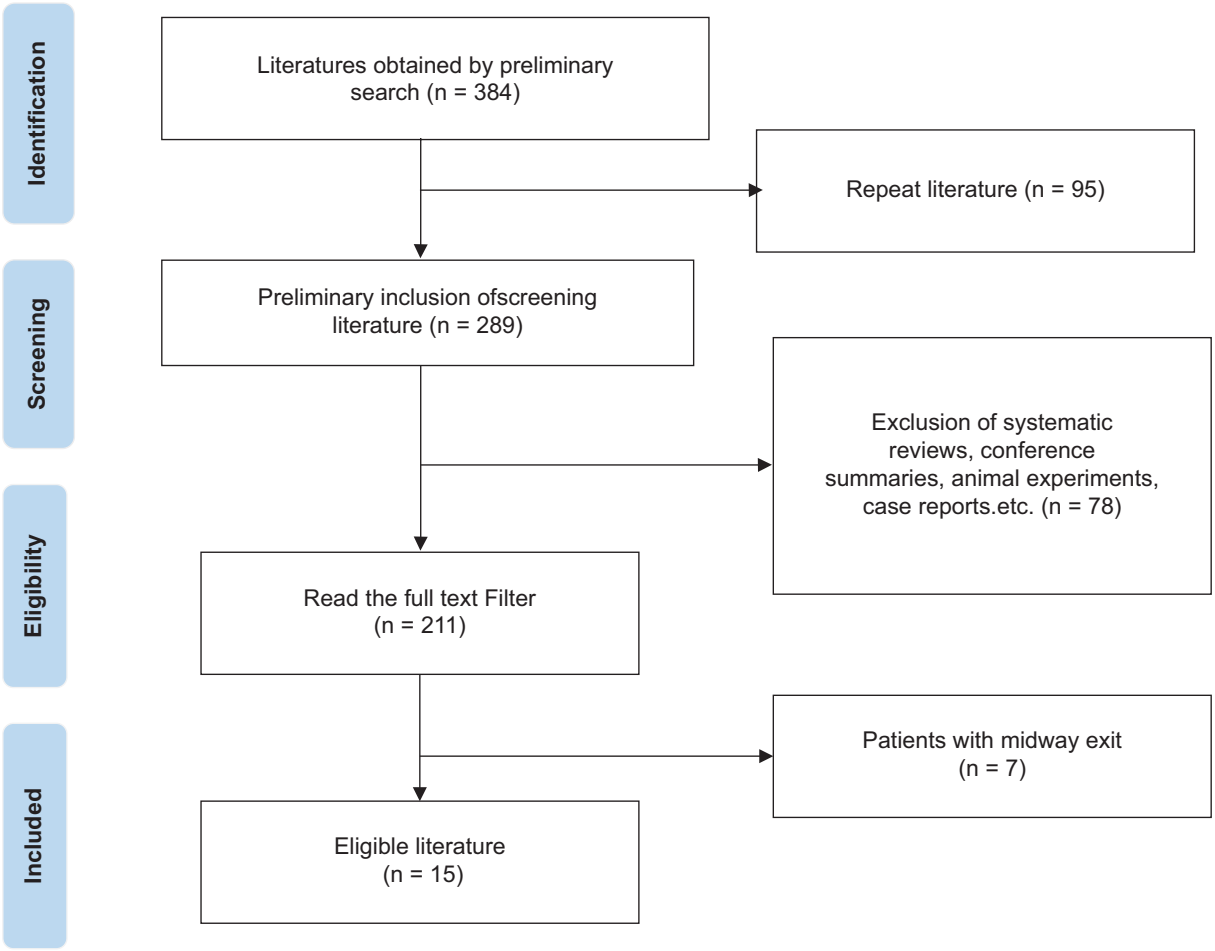

Figure 1. *Literature screening and flow chart.*

as low-quality articles. The basic characteristics and quality evaluation of the included articles are shown in table 1.

Meta-analysis results of the primary outcome measures

The clinical efficacy of minimally invasive stereotactic puncture evacuation of intracranial hematoma in the treatment of patients with cerebral hemorrhage

A total of eight literature papers compared the clinical efficacy of minimally invasive stereotactic puncture evacuation of intracranial hematoma (experiment group) with traditional craniotomy or treatment methods in the treatment of patients with cerebral hemorrhage (control group). The heterogeneity evaluation indicated homogeneity across studies ($I^2 = 0\%$, $p = 0.55$); therefore, the fixed effects model was used to calculate the pooled statistics. The meta-analysis showed that minimally invasive stereotactic puncture evacuation of intracranial hematoma had a higher overall clinical response rate in patients with cerebral hemorrhage compared with traditional craniotomy or treatment, with a pooled effect size of OR = 4.84 (95% CI: 3.30, 7.10, $p < 0.00001$) as shown in figure 2.

The effect of minimally invasive stereotactic puncture evacuation of intracranial hematoma on neurological deficits in patients with cerebral hemorrhage

Twelve articles compared the effect of minimally invasive stereotactic puncture evacuation of intracranial hematoma (experiment group) with traditional craniotomy or treatment methods (control group)

Table 1. Basic characteristics of included studies and literature quality evaluation table

Included articles	Publication Year	Published country	Study type	Sample Size		Surgical method		Outcome Measures	Literature quality evaluation grade
				Experimental group	Control group	Experimental group	Control group		
Huang Xiantuan	2019	China	Randomized controlled trial	40	40	Stereotactic minimally invasive puncture intracranial hematoma removal	Drug therapy	①②	Middle
Ma Xiankun et al.	2012	China	Randomized controlled trial	28	27	Frameless stereotactic hematoma evacuation	Craniotomy	③⑥	Middle
Gao Jianguo, et al.	2005	China	Randomized controlled trial	82	60	Stereotactic minimally invasive puncture intracranial hematoma removal	Craniotomy	①⑤⑥	Low
Song Anjun et al.	2016	China	Randomized controlled trial	30	30	Stereotactic minimally invasive puncture intracranial hematoma removal	Drug therapy		Middle
Wang Hong et al.	2020	China	Randomized controlled trial	36	36	Stereotactic minimally invasive puncture intracranial hematoma removal	Craniotomy	⑤②	Low
Yang Lichao et al.	2017	China	Randomized controlled trial	16	16	Stereotactic minimally invasive puncture intracranial hematoma removal	Craniotomy	②③④	Middle
Li Liang et al.	2020	China	Randomized controlled trial	40	40	Stereotactic minimally invasive puncture intracranial hematoma removal	Craniotomy	④⑤②	Middle
Zheng Jianghuan et al.	2013	China	Randomized controlled trial	60	60	Stereotactic minimally invasive puncture intracranial hematoma removal	Expectant treatment	②⑤	Low
Fu Qiang et al.	2021	China	Randomized controlled trial	30	30	Stereotactic minimally invasive puncture intracranial hematoma removal (Improved-soft channel)	Craniotomy	①②④⑤	Middle
Wang Junfeng et al.	2019	China	Randomized controlled trial	82	82	Stereotactic minimally invasive puncture intracranial hematoma removal (Improved-soft channel)	Expectant treatment	①⑤	Middle
Huang Lihua	2015	China	Randomized controlled trial	25	25	Stereotactic minimally invasive puncture intracranial hematoma removal (Improved-soft channel)	Craniotomy	⑤⑥③	Middle

(Continues)

Table 1. Basic characteristics of included studies and literature quality evaluation table *(continued)*

Included articles	Publication Year	Published country	Study type	Sample Size		Surgical method		Outcome Measures	Literature quality evaluation grade
				Experimental group	Control group	Experimental group	Control group		
Lin Xiaoqiang et al.	2018	China	Randomized controlled trial	33	31	Stereotactic minimally invasive puncture intracranial hematoma removal	Expectant treatment	①②④	High
Ma Xiaoqiang et al.	2021	China	Randomized controlled trial	32	30	Stereotactic minimally invasive puncture intracranial hematoma removal	Craniotomy	③	Middle
Zhou et al.	2011	China	Randomized controlled trial	64	58	Stereotactic minimally invasive puncture intracranial hematoma removal	Craniotomy	②④⑥	High
Jing et al.	2021	China	Randomized controlled trial	75	74	Stereotactic minimally invasive puncture intracranial hematoma removal	Craniotomy	②③④⑥	High

① Hospital stay (d) ② Postoperative neurological deficit score ③ Postoperative activities of daily living score ④ Incidence rate of complications (%) ⑤ Effective rate ⑥ Mortality rate

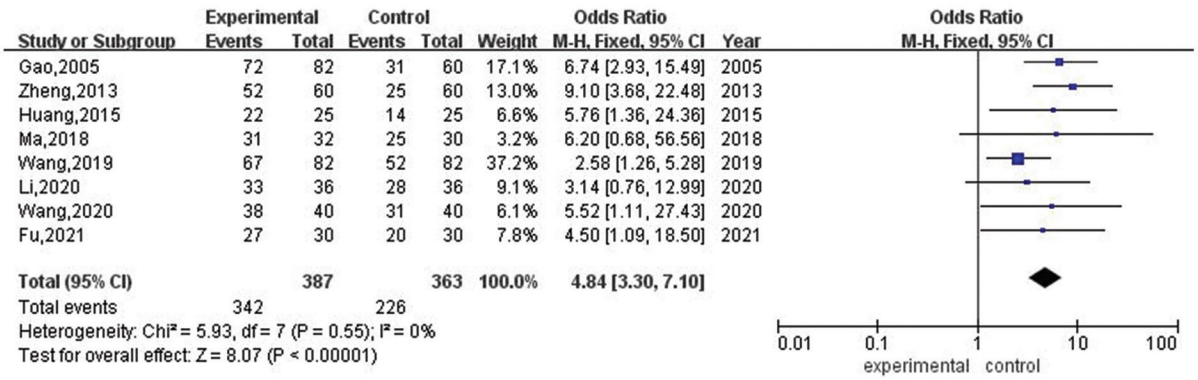

Figure 2. *Clinical efficacy.*

concerning the degree of neurological deficits in patients with cerebral hemorrhage. The heterogeneity evaluation indicated a high degree of heterogeneity among studies ($I^2 = 98\%$, $p < 0.00001$); accordingly, the random effects model was used to calculate the pooled statistics. The meta-analysis showed that patients with cerebral hemorrhage who had been treated with minimally invasive stereotactic puncture intracranial hematoma evacuation had a lower degree of post-operative neurological deficits compared with a craniotomy or treatment modalities used in the control group (SMD = –0.32, 95% CI: –1.33, 0.70), but the difference between the experiment and control groups was not statistically significant ($p = 0.054$) as shown in figure 3.

The sensitivity analysis showed that, after removing three studies that scored neurological deficits using the Glasgow Outcome Scale[13,19,21], heterogeneity among the included studies was reduced by 1%, but the difference between the experiment and control groups remained statistically insignificant (SMD = –0.99, 95% CI: –2.03, 0.06, $p = 0.06$).

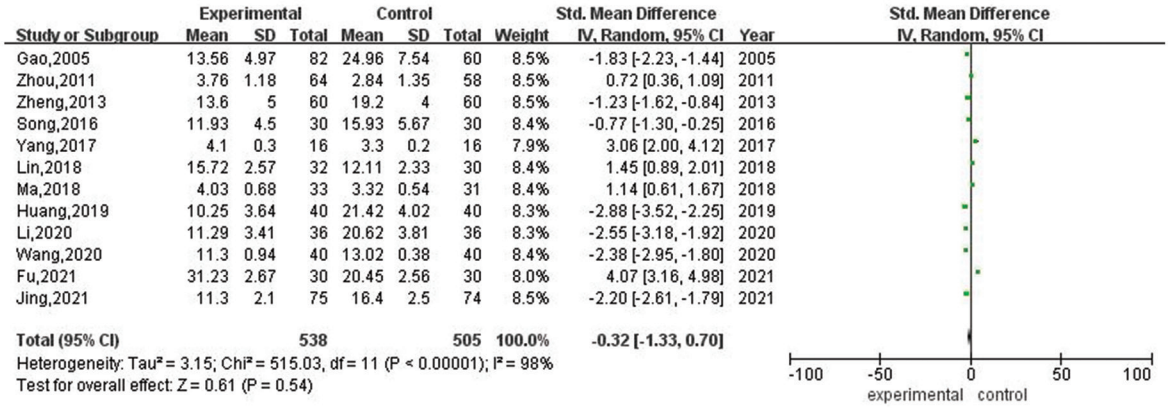

Figure 3. *Neurological deficits.*

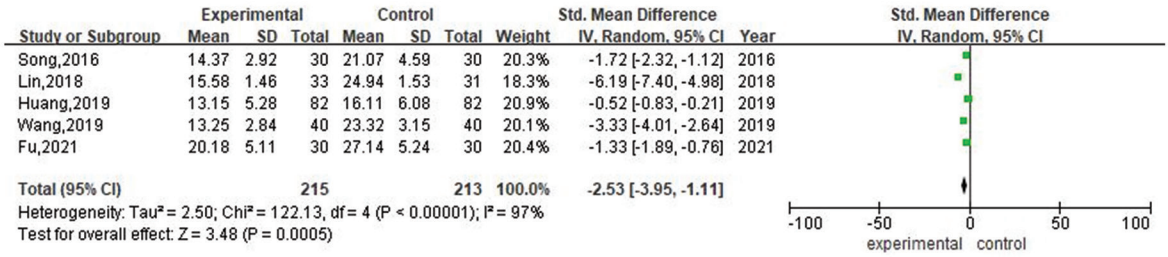

Figure 4. *Hospitalization Time.*

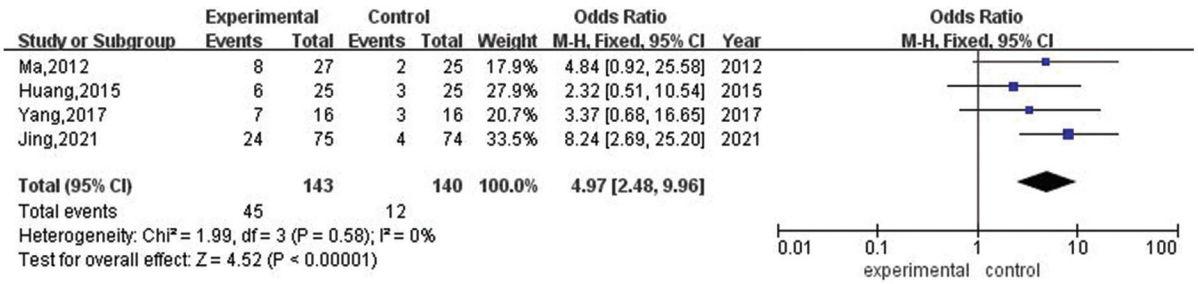

Figure 5. *Daily living ability.*

The effect of minimally invasive stereotactic puncture evacuation of intracranial hematoma on hospital stays in patients with cerebral hemorrhage

Five articles compared the effect of minimally invasive stereotactic puncture evacuation of intracranial hematoma (experiment group) with traditional craniotomy or treatment methods (control group) concerning the length of hospital stay among patients with cerebral hemorrhage. The heterogeneity evaluation showed a high degree of heterogeneity among studies ($I^2 = 97\%$, $p < 0.00001$); therefore, the random effects model was used to calculate the pooled statistics. The meta-analysis showed that minimally invasive stereotactic puncture evacuation of intracranial hematoma could significantly shorten the length of hospital stay for patients with cerebral hemorrhage, compared with craniotomy or treatment modalities used in the control group (SMD = –2.53, 95% CI: –3.95, –1.11, p = 0.0005) as shown in figure 4. After excluding one study[19], the sensitivity analysis showed that heterogeneity among the

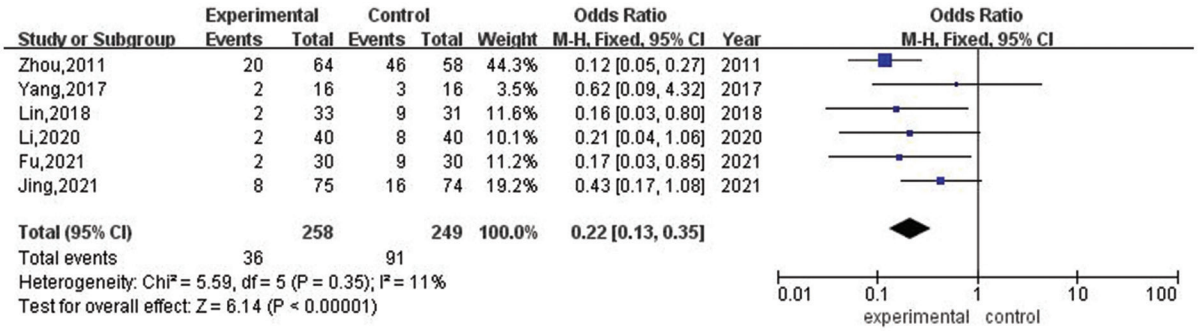

Figure 6. *Complications.*

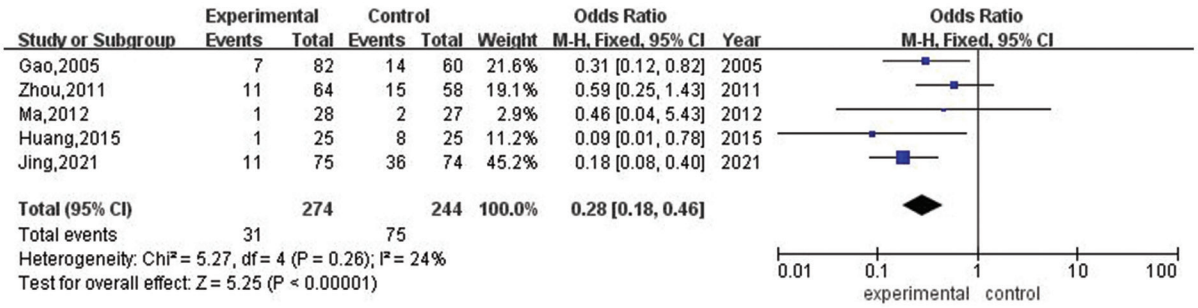

Figure 7. *Mortality.*

included studies had been reduced by 2%, and minimally invasive stereotactic puncture evacuation of intracranial hematoma could still significantly shorten the length of intensive care unit (ICU) stay for patients with cerebral hemorrhage (SMD = –1.70, 95% CI: –2.83, –0.56, p = 0.003).

The effect of minimally invasive stereotactic puncture evacuation of intracranial hematoma on the ADL in patients with cerebral hemorrhage

Five articles compared the effect of minimally invasive stereotactic puncture evacuation of intracranial hematoma (experiment group) with traditional craniotomy or treatment methods (control group) on the ADL of patients with cerebral hemorrhage. The heterogeneity evaluation showed good homogeneity among studies (I^2 = 0%, p = 0.58); accordingly, the fixed effects model was used to calculate the combined statistics. Patients in the experiment group had significantly higher levels of post-operative ADL compared with patients in the control group (OR = 4.97, 95% CI: 2.48, 9.96, p < 0.0001) as shown in figure 5.

The effect of minimally invasive stereotactic puncture evacuation of intracranial hematoma on complications for patients with cerebral hemorrhage

Six articles compared the effect of minimally invasive stereotactic puncture evacuation of intracranial hematoma (experiment group) with traditional craniotomy or treatment methods (control group) on complications for patients with cerebral hemorrhage. Because the heterogeneity evaluation showed low heterogeneity across studies (I^2 = 11%, p = 0.35), the fixed effects model was used to calculate the pooled statistics. Compared with patients in the control group, patients treated with minimally invasive stereotactic puncture evacuation of intracranial hematoma had a lower incidence rate of postoperative complications (OR = 0.22, 95% CI: 0.13, 0.35), and the difference was statistically significant (p < 0.00001) as shown in figure 6.

The effect of minimally invasive stereotactic puncture evacuation of intracranial hematoma on mortality among patients with cerebral haemorrhage

Five articles compared the effect of minimally invasive stereotactic puncture evacuation of intracranial hematoma (experiment group) with traditional craniotomy or treatment methods (control group) on the mortality of patients with cerebral hemorrhage. Because the heterogeneity evaluation showed low heterogeneity across studies ($I^2 = 24\%$, $p = 0.26$), the fixed effects model was used to calculate the pooled statistics. Compared with patients in the control group, patients treated with minimally invasive stereotactic puncture evacuation of intracranial hematoma had a lower mortality rate (OR = 0.28, 95% CI: 0.18, 0.46), and the difference was statistically significant ($p < 0.00001$) as shown in figure 7.

Discussion

In this research, 15 studies evaluating the clinical efficacy of minimally invasive stereotactic puncture evacuation of intracranial hematoma in the treatment of patients with cerebral hemorrhage were included by systematically searching Chinese and English databases. The results of this study are summarized below.

Minimally invasive stereotactic puncture evacuation of intracranial hematoma has a higher clinical efficacy

The results of this study showed that minimally invasive stereotactic puncture evacuation of intracranial hematoma in patients with cerebral hemorrhage had a higher overall clinical response rate compared with traditional craniotomy or treatment (OR = 4.84 [95% CI: 3.30, 7.10, $p < 0.00001$]). A traditional craniotomy is invasive, the treatment takes too long to ensure the required therapeutic effect and damage can occur to the patient's brain tissue[25]. The CT-guided stereotactic minimally invasive technique has been widely used in clinical practice in recent years. Minimally invasive intracranial hematoma evacuation mainly uses biochemical and enzymatic techniques to liquefy the patient's hematoma, as well as liquid jet positive pressure to comminute the hematoma, followed by impact, washing and drainage of the hematoma. This allows for completely removing the intracranial hematoma in a short time. Therefore, minimally invasive stereotactic puncture evacuation of intracranial hematoma has also been widely used[26,27]. The procedure has the following advantages: CT-guided directional operation avoids blind actions, can more accurately determine the location of the hematoma and can locate the patient's bleeding and determine the surrounding tissue damage, thereby improving the success rate, accuracy, and safety of the puncture[28]. In addition, endoscopic assistance can make the surgical field clearer, allowing for the accurate and comprehensive detection and handling of intraluminal hematoma bleeding to facilitate its removal quickly and thoroughly[29]. Furthermore, the operation of the technique is simple and can be completed with only local anesthesia, causing less impact on the brain tissue; the drainage tube placement time is also short[30].

Minimally invasive stereotactic puncture evacuation of intracranial hematoma has little effect on postoperative activities of daily life in patients with cerebral hemorrhage

The results of this study showed that the level of postoperative ADL was significantly higher in the experiment group compared with the control group (OR = 4.97, 95% CI: 2.48, 9.96, $p < 0.0001$). Activities of daily life are intuitive and effective indicators for evaluating prognosis. The meta-analysis showed that patients with cerebral hemorrhage, who had been treated with minimally invasive stereotactic puncture evacuation of intracranial hematoma, had a higher proportion of complete recovery of ADL within 3 months after surgery, compared with patients who had been treated with traditional treatments or craniotomy, with better postoperative ADL and an overall better prognosis. The possible reasons were analyzed as follows: Minimally invasive stereotactic puncture evacuation of intracranial hematoma minimized the surgical trauma of patients, for example, less damage to brain tissue and intracranial surrounding tissue than other surgical methods[31]. This surgical method was not strictly limited by age, condition or anesthesia, and could effectively drain the hematoma and shorten the surgical duration[32].

Minimally invasive stereotactic puncture evacuation of intracranial hematoma in patients with cerebral hemorrhage has a lower incidence of complications and mortality

The results of this study showed that patients treated with minimally invasive stereotactic puncture

evacuation of intracranial hematoma had a lower incidence of postoperative complications (OR = 0.22, 95% CI: 0.13, 0.35, p < 0.00001) and a lower mortality rate (OR = 0.28, 95% CI: 0.18, 0.46, p < 0.00001) compared with patients in the control group. Studies have shown that iatrogenic injury is more serious when performing a conventional craniotomy, and the incidence of long-term complications, such as postoperative mortality and secondary epilepsy, is relatively high[33]. This has the limitations of a long surgical procedure, possible severe trauma, and a high risk of anesthesia; accordingly, its prognosis and clinical efficacy are unsatisfactory[34]. Severe pulmonary infections, such as respiratory failure caused by severe pneumonia, epilepsy, and stress ulcers in the thalamus and brainstem are common postoperative complications among patients with cerebral haemorrhage[35]. Minimally invasive stereotactic puncture evacuation of intracranial hematoma can effectively reduce iatrogenic blood loss in patients with cerebral hemorrhage, quickly puncture the hematoma, aspirate the fluid part of cerebral hemorrhage and reduce intracranial pressure in a very short time. The residual semisolid hematoma is dissolved by a fibrinolytic solvent, the effect of early hematoma evacuation is achieved and the effect on brain tissue is reduced[36]. Accordingly, the risk factors of related complications are also effectively suppressed, thereby reducing the incidence of postoperative complications. In addition, the surgical process and time required to perform minimally invasive stereotactic puncture evacuation of intracranial hematoma are controllable. A routine post-operative CT scan re-examination can monitor the dynamic changes of residual hematoma volume to determine the dosage and frequency of urokinase injection and achieve the purpose of a maximum evacuation of hematoma fluid mass, significantly reducing the mortality of patients and improving their prognosis level[37]. Moreover, a stereotactic puncture is less cost prohibitive than traditional medical conservative treatment due to shorter stays in the ICU and a greater clinical effect[38].

Conclusion

In summary, the meta-analysis results of this study showed that minimally invasive stereotactic puncture intracranial hematoma evacuation had higher clinical efficacy in the treatment of patients with cerebral hemorrhage, compared with traditional craniotomy or conservative treatment, which could improve the post-operative ADL and reduce the incidence of post-operative complications and mortality. However, the method's effect on neurological deficits remains unclear, which may be because the scoring criteria used in each study have not yet been unified. The degree of neurological deficit is primarily evaluated using scales and lacks strong objectivity. Furthermore, the current authors did not collect information about the size of the hematomas that each study included. Conventionally, it has been established that patients who are eligible for the evacuation of these collections by the stereotactic method are those that present smaller bruises, but some studies did not provide this information. Therefore, it is still necessary to carry out a large sample, multicenter study in the future, using standardized, unified and scientific methods to evaluate the postoperative indicators among patients with cerebral hemorrhage, thereby further verifying the comprehensive efficacy of minimally invasive stereotactic puncture intracranial hematoma evacuation in the treatment of patients with cerebral hemorrhage.

Funding

The authors declare that they have not received funding for this study.

Conflicts of interest

The authors declare that they have no conflicts of interest.

Ethical disclosures

Protection of human and animal subjects. The authors declare that no experiments were performed on humans or animals for this study.

Confidentiality of data. The authors declare that no patient data appear in this article.

Right to privacy and informed consent. The authors declare that no patient data appear in this article.

References

1. Peng WS, Zhu CY, Liao SX, Fu HY. Clinical study of minimally invasive stereotactic puncture drainage and craniotomy hematoma removal for basal nucleus cerebral hemorrhage. Pract Clin J Integr Tradit Chin Western Med. 2020;20:103-4.
2. Wu S, Wu B, Liu M, Chen Z, Wang W, Anderson CS, et al. Stroke in China: advances and challenges in epidemiology, prevention, and management. Lancet Neurol. 2019;18:394-405.

3. Van Asch CJ, Luitse MJ, Rinkel GJ, Van der Tweel I, Algra A, Klijn CJ. Incidence, case fatality, and functional outcome of intracerebral haemorrhage over time, according to age, sex, and ethnic origin: a systematic review and meta-analysis. Lancet Neurol. 2010;9:167-76.
4. Lanfranconi S, Franco G, Borellini L, Denaro F, Basilico P, Parati E, et al. Genetics of cerebral hemorrhage and microbleeds. Panminerva Med. 2013, 55:11-28.
5. Changlin H, Yongtao L, Zhichao L. Standardized Treatment Guidelines for Minimally Invasive Elimination of Intracranial Hematoma. China: China Union Medical University Press; 2003-03-00,P278.
6. Sun SJ. Current situation and development of treatment of hypertensive cerebral hemorrhage. Continue Med Educ. 2006;20:26-7.
7. Miller DW, Barnett GH, Kormos DW, Steiner CP. Stereotactically guided thrombolysis of deep cerebral hemorrhage: preliminary results. Cleve Clin J Med. 1993;60:321-4.
8. Neurology Branch of Chinese Medical Association; Cerebrovascular Disease Group of Neurology Branch of Chinese Medical Association. Chinese guidelines for diagnosis and treatment of cerebral haemorrhage (2019). Pract Chinese J Neurol. 2019;52:994-1005.
9. Higgins JP, Green S. Cochrane Handbook for Systematic Reviews of Interventions, Version 5.0.2. United Kingdom: The Cochrane Collaboration; 2008.
10. Huang X. Observation observe the clinical effect of minimally invasive stereotactic puncture for removal of intracranial hematoma in patients with cerebral hemorrhage. Home Med. 2019;12:7-8.
11. Ma X, Li J, Tian Z, Yin F, Ma Z. Effect of frameless stereotactic hematoma removal and posterior fossa craniotomy in treatment of elderly cerebellar hemorrhage. Chin J Gerontol. 2014;10:2696-8.
12. Gao J, Dong Y, Ren P, Yang J, Liu HB. Clinical practice in curing of cerebral hemorrhage with stereotactic minimally invasive techenique. Ningxia Med J. 2005;27:833-5.
13. Song A, Wu G, Ren S, Wang L, Mao Y, Xiong J. Effect of minimally invasive stereotactic puncture intracranial hematoma removal on patients with cerebral hemorrhage. J Guizhou Med Univ. 2016;41:858-61.
14. Wang H. Effect analysis of stereotactic minimally invasive intracranial hematoma removal in treatment of cerebral hemorrhage. Electron J Clin Med Lit. 2020;7:8.
15. Tsien C, Souhami L, Sadikot A, Olivier A, del Carpio-O'Donovan R, Corns R, et al. Stereotactic radiosurgery in the management of angiographically occult vascular malformations. Int J Radiat Oncol. Biol Phys. 2001;50(1):133-8. doi: 10.1016/s0360-3016(00)01568-6.PMID: 11316556.
16. Li L. The curative effect and application value of minimally invasive stereotactic puncture intracranial hematoma removal in the treatment of cerebral hemorrhage. Kang Yi. 2020;11:221.
17. Zheng J, Lijie N. Observation on the curative effect of stereotactic minimally invasive intracranial hematoma removal in the treatment of cerebral hemorrhage. Seek Med Ask Med. 2013;11:85-6.
18. Fu Q, Zhang Y, Jianzhong L. Curative effect and analysis of modified-stereotactic soft channel minimally invasive intracranial hematoma removal and surgical large bone flap craniotomy on patients with hypertensive cerebral hemorrhage. Guizhou Med J. 2021;45:1542-3.
19. Wang J, Yang W. Curative effect of modified-stereotactic soft channel minimally invasive intracranial hematoma removal in treatment of hypertensive cerebral hemorrhage. Anhui Med J. 2019;40:892-4.
20. Huang L. Observation of the therapeutic effect stereotacti orientation-modified soft channel minimally invasive surgical treatment for hypertensive cerebral hemorrhage. Mod Diagn Treat 2015;26:4337-9.
21. Lin X, Liu Z, Niu J, Zeng S, Shi D, Gong H. A comparative study of stereotactic assisted minimally invasive hematoma evacuation and conservative treatment in the treatment of moderate and small hematomas in the basal ganglia of the brain. Chin J Neuromed. 2021;20:827-30.
22. Ma X, Zhang J, Zhang X, Xu M. Clinical effect of stereotactic intracranial minimally invasive hematoma removal in treatment of hypertensive cerebral hemorrhage. Pract J Card Cereb Pneumal Vasc Dis. 2018;26:133-5.
23. Zhou H, Zhang Y, Liu L, Huang Y, Tang Y, Su J, et al. Minimally invasive stereotactic puncture and thrombolysis therapy improves long-term outcome after acute intracerebral hemorrhage. J Neurol. 2011;258:661-9.
24. Shi J, Zou X, Jiang K, Tan L, Wang L, Ren S, et al. Intracerebral hemorrhage with tentorial herniation: conventional open surgery or emergency stereotactic craniopuncture aspiration surgery? Transl Neurosci. 2021;12:198-209.
25. Zhang L, Wang L, Ren S, Mao Y, Li Y, Wu G. Effect of cephalohematoma morphological feartures on outcome in ICH patients after stereotactic minimally invasive surgery. Chin J Geriatr Heart Brain Vessel Disl. 2019;21:834-8.
26. Yang Z, Hong B, Jia Z, Chen J, Ge J, Han J, et al. Treatment of supratentorial spontaneous intracerebral hemorrhage using image-guided minimally invasive surgery: initial experiences of a flat detector CT-based puncture planning and navigation system in the angiographic suite. AJNR Am J Neuroradiol. 2014;35:2170-5.
27. Chen X, Chen W, Ma A, Wu X, Zheng J, Yu X, et al. Frameless stereotactic aspiration and subsequent fibrinolytic therapy for the treatment of spontaneous intracerebral haemorrhage. Br J Neurosurg. 2011;25:369-75.
28. Labib MA, Shah M, Kassam AB, Young R, Zucker L, Maioriello A, et al. The safety and feasibility of image-guided brainpath-mediated transsulcul hematoma evacuation: a multicenter study. Neurosurgery. 2017;80: 515-24.
29. Liang KS, Ding J, Yin CB, Peng LJ, Liu ZC, Guo X, et al. Clinical study on minimally invasive liquefaction and drainage of intracerebral hematoma in the treatment of hypertensive putamen hemorrhage. Technol Health Care. 2017;25:1061-71.
30. Fu C, Wang N, Chen B, Wang P, Chen H, Liu W, et al. Surgical management of moderate basal ganglia intracerebral hemorrhage: comparison of safety and efficacy of endoscopic surgery, minimally invasive puncture and drainage, and craniotomy. World Neurosurg. 2019;122:e995-1001.
31. Nath SK, Sandhu AP, Jensen L, Kim D, Bharne A, Nobiensky PD, et al. Frameless image-guided stereotactic body radiation therapy for lung tumors with 4-dimensional computed tomography or 4-dimensional positron emission tomography/computed tomography. Clin Lung Cancer. 2011;12:180-6.
32. Linjie C. Effect comparison of stereotactic soft channel intracranial hematoma evacuation and hard channel minimally invasive intracranial hematoma evacuation in treating hypertensive cerebral hemorrhage. Henan Med Res. 2020;29:4091-3.
33. Xu K, Hai J. The clinical study of stereotactic microsurgery. Cell Biochem Biophys. 2014;69:259-63.
34. Jang JH, Cho WS, Hong N, Pang CH, Lee SH, Kang HS, et al. Surgical strategy for patients with supratentorial spontaneous intracerebral hemorrhage: minimally invasive surgery and conventional surgery. J Cerebrovasc Endovasc Neurosurg. 2020;22:156-64.
35. Gross BA, Jankowitz BT, Friedlander RM. Cerebral intraparenchymal hemorrhage: a review. JAMA. 2019;321:1295-303.
36. Barrett RJ, Hussain R, Coplin WM, Berry S, Keyl PM, Hanley DF, et al. Frameless stereotactic aspiration and thrombolysis of spontaneous intracerebral hemorrhage. Neurocrit Care. 2005;3:237-45.
37. Miller CM, Vespa PM, McArthur DL. Frameless stereotactic aspiration and thrombolysis of deep intracerebral hemorrhage is associated with reduced levels of extracellular cerebral glutamate and unchanged lactate pyruvate ratios. Neurocrit Care. 2007;6:22-9.
38. Jia J, Qu X, Tian Q. Clinical study of minimally invasive removal of intracranial hematoma through soft channel in the treatment of intracerebral hemorrhage. Stroke Neuropathy. 2011;18:376-8.