Check for updates

CLINICAL CASE

Eosinophilic enteritis presenting as intestinal obstruction: case report and review of the literature

Enteritis Eosinofílica presentada como oclusión intestinal: reporte de caso y revisión de literatura

Beatriz de Rienzo-Madero[1], Daniel Kajomovitz-Bialostozky[1], Ángel Martinez-Munive[1], Mario Pelaez-Luna[2], Ana Rivera-García-Granados[1], and Fernando Quijano-Orvañanos[1]*

[1]Department of Surgery; [2]Department of Gastroenterology and Endoscopy. Centro Médico ABC, Mexico City, Mexico

Abstract

Eosinophilic enteritis (EE) is characterized by intense eosinophilic infiltrate of the gastrointestinal tract. Clinical manifestations depend on the affected segment and intestinal layer. First-line treatment is systemic corticosteroids; surgery is reserved for complications. 84-year-old male patient with a history of right hemicolectomy and two episodes of intestinal obstruction presented to the ED with abdominal pain, distension, nausea, and vomiting. CBC showed leukocytosis and no eosinophilia. Contrast-enhanced CT revealed stenosis with thickening of the distal intestinal wall and partial intestinal obstruction. Colonoscopy found aphthous ulcers. Histopathology reported EE. The patient received budesonide and metronidazole, with resolution within 24 h.

Keywords: *Eosinophilic enteritis. Eosinophilic gastroenteritis. Intestinal obstruction.*

Resumen

La enteritis eosinofílica (EE) se caracteriza por infiltrado eosinofilico del tracto GI. Las manifestaciones clínicas dependen de la capa intestinal afectada. Se recomiendan esteroides sistémicos como primera línea de tratamiento, reservando la cirugía para complicaciones. Masculino de 84 años con antecedente de hemicolectomía derecha y dos episodios de oclusión intestinal acude al servicio de urgencias con dolor abdominal, distensión, náusea y vómito. Laboratorio reportó leucocitosis, sin eosinofilia. Tomografía con contraste evidenció estenosis, con engrosamiento de la pared del intestino delgado e imagen compatible con oclusión intestinal. La colonoscopía demostró ulceras en íleon terminal la cual reporto EE. Se inició tratamiento con budesonide y metronidazol, con adecuada respuesta y resolución a las 24 h.

Palabras clave: *Enteritis eosinofílica. Gastroenteritis eosinofílica. Oclusión intestinal.*

***Correspondence:**
Ana Rivera-García-Granados
E-mail: arivera.gg@gmail.com

Date of reception: 19-09-2021
Date of acceptance: 15-10-2021
DOI: 10.24875/CIRUE.M21000734

Cir Cir (Eng). 2023;91(5):690-693
Contents available at PubMed
www.cirugiaycirujanos.com

2444-0507/© 2021 Academia Mexicana de Cirugía. Published by Permanyer. This is an open access article under the terms of the CC BY-NC-ND license (http://creativecommons.org/licenses/by-nc-nd/4.0/).

Introduction

Eosinophilic enteritis (EE) consists of an eosinophilic infiltration of segments of the gastrointestinal (GI) tract. Clinical manifestations depend on the affected segment and intestinal layer: (1) Mucosal (44%), diarrhea, pain, malabsorption; (2) Muscular (12%), strictures, pain, nausea, vomiting, obstruction; (3) sub-serosal (49%), eosinophilic-rich ascites, bloating, pain. There is an association with eosinophilia and atopic disorders. Diagnosis consists of compatible symptoms and exclusion of secondary causes. There are no clear recommendations for treatment; the first line being systemic corticosteroids or budesonide. Surgery is reserved for complications.

Case presentation

An 84-year-old, otherwise healthy male with a remote history of appendectomy, intestinal resection, and right hemicolectomy for an unknown cause, as well as radical prostatectomy and two episodes of intestinal obstruction; presented to the emergency room with a 2-day history of diffuse abdominal pain and distension accompanied by nausea and vomiting. On physical examination, the patient had normal vital signs, abdominal distention, and generalized abdominal pain at palpation, with no rebound tenderness. The laboratory studies showed leukocytosis of 15 and no eosinophilia; total eosinophils of 0.1. He underwent an oral contrast-enhanced CT scan which revealed dilation of the small intestine, areas of stenosis in the distal small intestine with thickening of the intestinal wall, and passage of oral contrast to the colon, compatible with a partial intestinal obstruction (Fig. 1).

Conservative management was initiated, consisting of parenteral rehydration and a nasogastric tube. A colonoscopy that was performed found aphthous ulcers in the stenotic area in the distal ileum (Fig. 2).

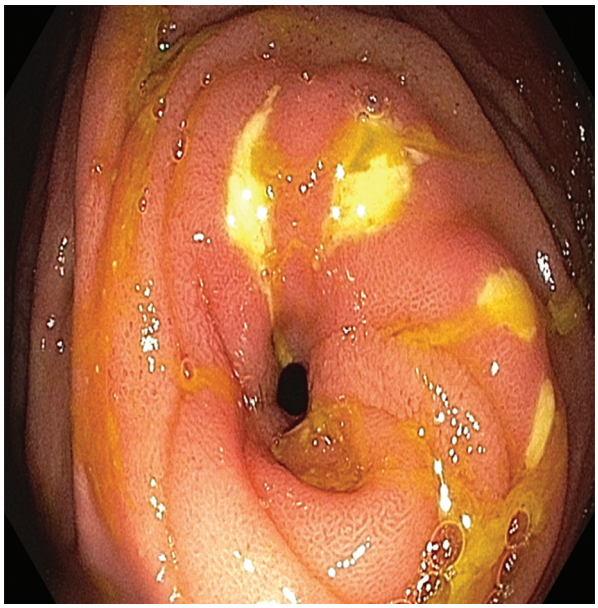

Figure 2. *Colonoscopy. Aphthous ulcers in terminal ileum.*

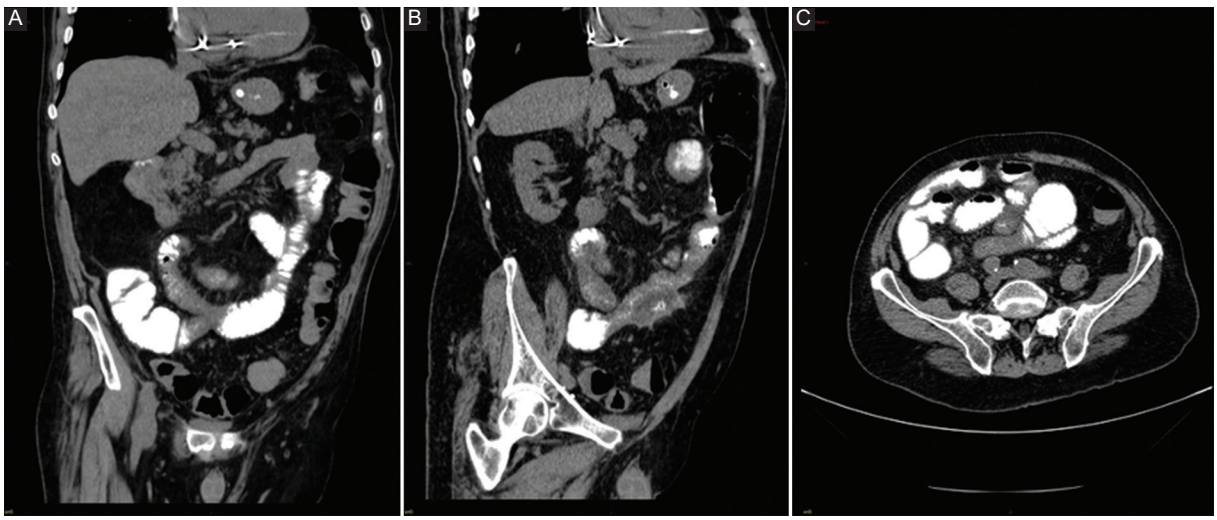

Figure 1. *Oral contrast-enhanced abdominal CT scan. Areas of stenosis and thickening of the distal intestinal wall, dilation of the small intestine proximal to this area, and passage of oral contrast to the colon, compatible with a partial intestinal obstruction:* **A:** *coronal view,* **B:** *oblique,* **C:** *axial.*

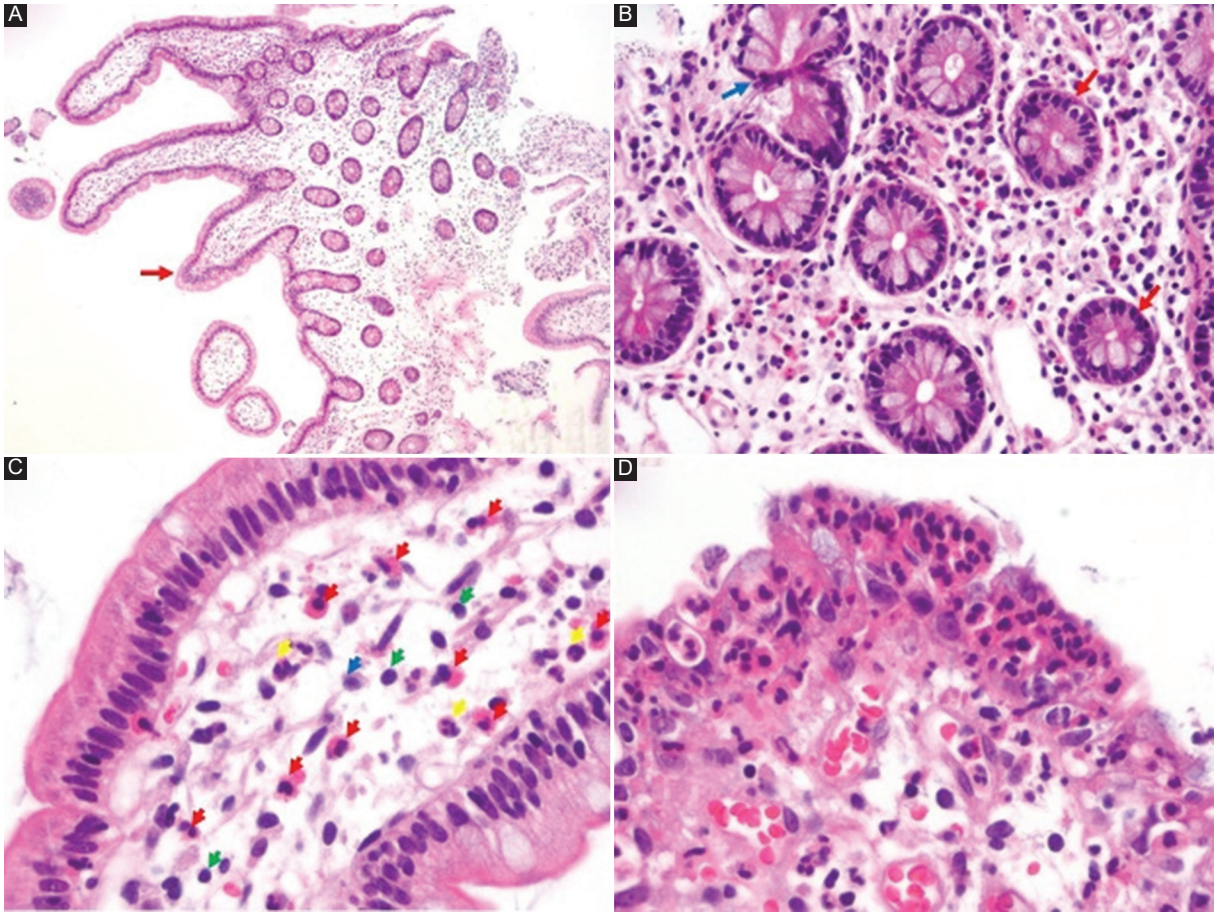

Figure 3. *Distal ileum biopsy.* **A:** *panoramic microphotography of ileum mucosa with villous flattening (red arrow), edema in the lamina propia, and moderate inflammatory infiltrate (H and E ×4).* **B:** *mixed inflammatory infiltrate with abundant eosinophils, reactive changes, and loss in architecture in Lieberkühn crypts (blue arrow), reduces mucous production (red arrows), and light cellular atypia (H and E ×20).* **C:** *inflammatory infiltrate composed predominantly by eosinophils (red arrows), polymorphonuclear neutrophils (yellow arrows), lymphocytes (green arrows), and plasmatic cells (blue arrows) (H and E ×40).* **D:** *abundant eosinophils (57 per HPF) in the lamina propia and superficial mucosa (H and E ×40).*

A film array and stool and direct parasite studies were negative. The patient was started on budesonide 9 mg/d and metronidazole, and 24 h after admission, his partial intestinal obstruction resolved. The final histopathology of the biopsies reported non-granulomatous chronic, ulcerous ileitis, with 57 eosinophils per HPF (with a normal range at this anatomic site of 20 eosinophils per HPF), compatible with a diagnosis of EE (Fig. 3). He is currently treated with budesonide with an adequate response and has begun dose tapering without recurrence.

Discussion

EE is a rare idiopathic GI disease characterized by an intense eosinophilic infiltrate of any segment of the intestinal wall[1]. EE has a prevalence of 5/100,000 people[1-4]. It is more common in children under 5 years; however, in adults, it affects females (57%), Caucasian (77%), and between the third and fifth decade (83%)[1-5]. Other risk factors include higher socioeconomic status and excess weight[4,5]. It may present with a wide array of symptoms, including abdominal pain, diarrhea, nausea, vomiting, bloating, intestinal obstruction, or ascites[1] depending on the affected intestinal wall layer.

The clinical manifestations depend on the affected segment of the GI tract and the intestinal layer involved[1,3,4,6]. The mucosal form, present in 44% of patients, is characterized by vomiting, diarrhea, abdominal pain, failure to thrive, and malabsorption[3,6]. The muscular form, present in 12% of patients, may present with intestinal strictures, abdominal pain, nausea, vomiting, and intestinal obstruction[3,6]. The sub-serosal form, present in 49% of patients, is characterized by eosinophilic-rich ascites, bloating, and abdominal pain[3,6]. An

association between EE and eosinophilia (> 70%) and atopic disorders (rhinitis, eczema, asthma, food and drug allergy, dermatitis) has been described[3-5] with 64% of patients having a family history of atopic diseases[7].

EE primarily affects the stomach and duodenum in up to 40-80% of patients[1–3]. The diagnosis is established by GI symptoms associated with eosinophilic infiltration and degranulation in at least one intestinal segment, and exclusion of secondary causes of intestinal eosinophilia (parasitosis, intestinal infections, associated drugs, IBD, celiac disease, autoimmune disease, and vasculitis, neoplasia, food hypersensitivity)[2-4]. It is important to note that eosinophils usually reside in the lamina propia of the intestinal mucosa[4,8], except for the esophagus. Their count increases from the duodenum to the cecum and then decreases from proximal to distal in the colon[8]. Therefore, the cut-off to define an intense pathological eosinophilic infiltration must take into account the localization within the GI tract[4,8]. Other histological characteristics of EE include eosinophils in the epithelial or muscular layers, degranulation of eosinophils, villous atrophy, crypt hyperplasia/abscesses, and epithelial degenerative and regenerative changes[1,4].

Although the gold standard for diagnosis is histological confirmation, EE can be suspected at endoscopy and CT imaging. Endoscopic findings may appear normal, with slight erythema, white specks, focal erosions, ulcers, fold thickening, polyps, nodules, and friability[4]. The colonoscopy may show mucosal edema, erythema, elevated white lesions, pale granular mucosa, and aphthous ulceration[4]. On CT scan, there may be evidence of fold thickening, polyps, ulcers, reduced distensibility, strictures, fold thickening, ascites, omental thickening, and lymphadenopathy depending on the intestinal layer involved[4].

There are no clear recommendations for treatment[1]. Approximately 40% of patients will present with spontaneous remission[1]. There is insufficient evidence to recommend dietary restrictions in the routine management of patients with EE[1]. The first line of treatment is corticosteroids[1,4]. Systemic corticosteroids may be used, with a remission rate of 50-90%[1]. Treatment is started at 0.5-1 mg/kg/day for a few weeks and a tapering period of 6-8 weeks[4,5]. Budesonide which has low systemic absorption, may also be used at an initial dose of 9 mg/day and slowly tapered for maintenance therapy[1,4]. Other treatment alternatives depend on the disease's response and severity and include leukotriene inhibitors, mast cell stabilizers, antihistamines H1, azathioprine, mesalazine, and biological agents[1,4]. Surgery is reserved for intestinal complications, such as strictures or perforation, and consists of a segmental resection with or without primary anastomosis[4]. As in this patient, even in the setting of an acute abdomen, symptoms may respond to conservative treatment with immunosuppression[4].

Funding

The authors received no specific funding for this work.

Conflicts of interest

The authors declare that they have no conflicts of interest.

Ethical disclosures

Protection of human and animal subjects. The authors declare that no experiments were performed on humans or animals for this study.

Confidentiality of data. The authors declare that they have followed the protocols of their work center on the publication of patient data.

Right to privacy and informed consent. The authors have obtained the written informed consent of the patients or subjects mentioned in the article. The corresponding author is in possession of this document.

References

1. De Chambrun GP, Dufour G, Tassy B, Rivière B, Bouta N, Bismuth M, et al. Diagnosis, natural history and treatment of eosinophilic enteritis: a review. Curr Gastroenterol Rep. 2018;20:37.
2. Talley NJ, Shorter RG, Phillips SF, Zinsmeister AR. Eosinophilic gastroenteritis: a clinicopathological study of patients with disease of the mucosa, muscle layer, and subserosal tissues. Gut. 1990;31:54-8.
3. Mansoor E, Saleh MA, Cooper GS. Prevalence of eosinophilic gastroenteritis and colitis in a population-based study, from 2012 to 2017. Clin Gastroenterol Hepatol. 2017;15:1733-41.
4. Walker MM, Potter M, Talley NJ. Eosinophilic gastroenteritis and other eosinophilic gut diseases distal to the oesophagus. Lancet Gastroenterol Hepatol. 2018;3:271-80.
5. Rached AA, El Hajj W. Eosinophilic gastroenteritis: approach to diagnosis and management. World J Gastrointest Pharmacol Ther. 2016;7:513-23.
6. Klein NC, Hargrove RL, Sleisenger MH, Jeffries GH. Eosinophilic gastroenteritis. Medicine (Baltimore). 1970;49:299-319.
7. Reed C, Woosley JT, Dellon ES. Clinical characteristics, treatment outcomes, and resource utilization in children and adults with eosinophilic gastroenteritis. Dig Liver Dis. 2015;47:197-201.
8. Lowichik A, Weinberg AG. A quantitative evaluation of mucosal eosinophils in the pediatric gastrointestinal tract. Mod Pathol. 1996;9:110-4.