Check for updates

ORIGINAL ARTICLE

Outcome of multidisciplinary treatment in laryngeal cancer: A retrospective study with 10-year follow-up

Resultados del tratamiento multidisciplinario en cáncer de laringe. Estudio retrospectivo con seguimiento a 10 años

Héctor Gurrola-Machuca[1], Arturo P. Miranda-Aguirre[1], Michelle Villavicencio-Quejeiro[2], Gabriela Nuñez-Guardado[2], and Alejandro Juárez-Ramiro[3]*

[1]Department of Surgical Oncology; [2]Radiotherapy Department; [3]Department of Medical Oncology. Head and Neck Tumor Multidisciplinary Clinic, Centro Médico Nacional 20 de Noviembre, Instituto de Seguridad y Servicios Sociales de los Trabajadores del Estado, Mexico City, Mexico

Abstract

Background: *In laryngeal cancer, multidisciplinary treatment improves the patient's quality of life and the possibility of preserving the larynx. Most cases occur in a locally advanced stage. The aim is to present the results according to the stage.* **Method:** *A retrospective study which analyzed the clinical stage, type of primary treatment, outcomes, and survival was analyzed.* **Results:** *A total of 451 patients were included in the study. The median age was 66 years. The majority of the tumors presented in advanced stage (72%) and the most affected subsite was the glottis (84.5%). In the early stage, the most frequent treatment was radiotherapy as the only treatment modality. In Stages III and IVA, 65% were resectable. In Stage IVB, the management was non-surgical, with control in 26% of the cases. Survival at 10 years was related to the clinical stage: 81.7% for Stage I and 0% for Stages IVB and IVC.* **Conclusions:** *Patients with laryngeal cancer should be treated according to the clinical stage, through a multidisciplinary approach. Long-term follow-up showed a worse prognosis for advanced clinical stages.*

Keywords: *Larynx neoplasm. Laryngectomy. Induction chemotherapy. Chemoradiotherapy. Bioradiotherapy. Head-and-neck neoplasm.*

Resumen

Antecedentes: *En cáncer de laringe, el tratamiento multidisciplinario mejora la calidad de vida del paciente y la posibilidad de preservar la laringe. La mayor parte de estos cánceres se presentan localmente avanzados. El objetivo es presentar los resultados de acuerdo con la etapa.* **Método:** *Estudio retrospectivo en el que se analizaron la etapa clínica, el tipo de tratamiento primario, los resultados y la sobrevida.* **Resultados:** *Se incluyeron 451 pacientes. La mediana de edad fue de 66 años. El mayor porcentaje de los tumores se presentó en etapa avanzada (72%) y el sitio más afectado fue la glotis (84.5%). En etapa temprana, el tratamiento más frecuente fue la radioterapia. En las etapas III y IVA, el 65% fueron operables. En la etapa IVB el manejo fue no quirúrgico, con control en el 26% de los casos. La supervivencias a 10 años se relacionaron con la etapa clínica: 81.7% para la etapa I y 0% para las etapas IVB y IVC.* **Conclusiones:** *Los pacientes con cáncer de laringe deben ser tratados de acuerdo con la etapa clínica y mediante un abordaje multidisciplinario. El seguimiento a largo plazo demostró un peor pronóstico para las etapas clínicas avanzadas.*

Palabras clave: *Neoplasias de laringe. Laringectomía. Quimioterapia de inducción. Tratamiento concomitante. Biorradioterapia. Neoplasias de cabeza y cuello.*

Correspondence:
*Héctor Gurrola-Machuca
E-mail: gurrolamah@prodigy.net.mx

Date of reception: 30-08-2019
Date of acceptance: 09-12-2019
DOI: 10.24875/CIRUE.M20000154

Cir Cir (Eng). 2020;88(4):450-455
Contents available at PubMed
www.cirugiaycirujanos.com

2444-0507/© 2019 Academia Mexicana de Cirugía. Published by Permanyer. This is an open access article under the terms of the CC BY-NC-ND license (http://creativecommons.org/licenses/by-nc-nd/4.0/).

Introduction

Head-and-neck squamous cell carcinoma accounts for 6% of all neoplasms, both globally and nationally. Laryngeal cancer is the second most common neoplasm of the upper aerodigestive tract and accounts for 2% of all cancer cases in the world; in our country, it has been estimated at around 1%[1]. Squamous cell carcinoma is the most common histology, with 98.7% of cases[2]. Laryngeal cancer treatment has significantly changed in recent years due to the development of laryngeal preservation procedures, radiotherapy methods and introduction of chemotherapy (induction and concomitant), as well as to the addition of new drugs such as targeted therapy[3]. Multidisciplinary management through a coordinated oncology team improves patient care, quality of life, and the possibility for the larynx to be preserved[4,5]. The risk factors that have been most involved are alcohol, tobacco, and the combination of both[6]. Increasing evidence indicates that some viruses are involved in the genesis of head-and-neck squamous cell carcinoma, especially the human papillomavirus, which is present in 20-30% of laryngeal cancer cases[7,8]. Most cases (up to 70% in Mexico) are at locally advanced stage, that is, III-IVB[9].

The purpose of this study is to report the oncological results of patients with laryngeal cancer, stratified by stage, and treated with a multidisciplinary approach in a tertiary care center, with a long follow-up period.

Methods

A retrospective, retrolective study was conducted, in which the medical records of patients diagnosed with laryngeal cancer in a tertiary care center were reviewed. To be included, patients had to meet the following criteria: being older than 18 years of age, having a confirmed histological diagnosis of squamous cell carcinoma of the larynx, having complete medical records, and having received all the treatment in our hospital center. Confidentiality of the subjects was ensured through coding by subject, avoiding the use of proper names. Approval by the research ethics committee of our institution was obtained. Demographic data were evaluated, including age, gender, subsite, Eastern Cooperative Oncology Group (ECOG) performance status, clinical stage according to the classification of the American Joint Committee on Cancer, eighth edition, the treatment that was used, and overall survival. Survival was analyzed with the Kaplan–Meier test, and factors were compared with the log-rank test to demonstrate significant differences. $p < 0.05$ was considered a statistically significant difference.

Results

Four-hundred and fifty-one patients were included for analysis (85% males), with a median age of 66 years (range: 33-94 years). The most affected subsite was the glottis, in 84.5% of cases, followed by the supraglottis and hypopharynx, with 13.5% and 2%, respectively. Most patients had an ECOG of 1 and 2 (88.2%). Early clinical stage accounted for 28% and locally advanced stages for 72% (Table 1).

- Stage 0: eight cases were reported, out of which seven were treated with external beam radiotherapy because the disease was multicentric, and one with vocal cord stripping. In all cases, the disease was controlled.
- Stages I and II: constituted 118 cases, out of which 82 were at Stage I and 36 at Stage II. Of these, 113 were treated with radiotherapy (95.8%), 4 with cordectomy (3.4%), and one with vertical hemilaryngectomy and post-operative radiotherapy (which was not controlled). Local control was obtained in 117 cases, out of which 27 had recurrence (22.9%). Of the latter, 23 underwent surgery with curative intent, with local control being obtained in 18 (78%); in 17 of them, surgery was radical laryngectomy and only in one was vertical hemilaryngectomy performed.

In contrast, in locally advanced stages, that is, clinical Stages III and IVA, 65.1%, were operable. The glottis was the most affected subsite, in 84.5% of cases. There were 90 recurrences and only in 23 patients (25.5%), the disease could be controlled with curative surgery. The results are broken down as follows:

- Stage III: there were 108 cases and only 102 were treated, given that six patients did not accept any treatment. All treatments had a multidisciplinary approach. The treatments whereby the longest survival was obtained were cetuximab and concomitant radiotherapy, induction chemotherapy with cetuximab-radiotherapy concomitant management, and chemotherapy, cetuximab, and concomitant radiotherapy. Radical laryngectomy with post-operative radiotherapy, radical laryngectomy alone, and sequential chemoradiotherapy

Table 1. Clinical and demographic data of patients with laryngeal cancer

Variable	n = 451
Age, median (range)	66 (33-94)
Gender, males (%)	384 (85.1)
Subsite, n(%)	
Glottis	381 (84.5%)
Supraglottis	61 (13.5)
Hypopharynx	9 (2.0)
ECOG, n (%)	
0	41 (9.1)
I	324 (71.8)
II	74 (16.4)
III	11 (2.4)
IV	1 (0.2)
Clinical stage, n (%)	
0	8 (1.8)
I	82 (18.2)
II	36 (8)
III	108 (23.9)
IVA	186 (41.2)
IVB	28 (6.2)
IVC	3 (0.7)

ECOG: *Eastern Cooperative Oncology Group.*

(CT-RT) obtained lower survival rates than the first mentioned regimens (Fig. 1A). Disease control was obtained in 80% of cases. Twenty-two patients (27%) experienced recurrence, with curative surgery being possible only in 2 (9%). Induction chemotherapy showed a survival increase (mean: 8.23 years; 95% confidence interval [CI], 5.92-10.5) in comparison with those who did not receive it (mean: 2.42 months; 95% CI, 2.14-2.7) (Fig. 1B). For analysis, treatments were categorized into three groups of patients: those who received bioradiotherapy, those who received surgery, and those who received CT-RT. We observed that when cetuximab was added to radiotherapy for locoregional management, survival was longer than with surgery alone or with concomitant CT-RT without the use of this antibody (Fig. 1C).

- Stage IVA: there were 186 cases and 165 patients were treated. Management was multidisciplinary and included 24 different treatment combinations. Those with the longest survival were induction chemotherapy and concomitance with radiotherapy and cetuximab, followed by those treated with surgery, radical neck dissection, and radiotherapy, and in third place, those corresponding to radical laryngectomy (Fig. 2A). Disease control was obtained in 56% of cases, among which 38 patients (41%) had recurrence, and curative surgery could only be performed in 3 patients (8%). The use of induction chemotherapy improved survival (Fig. 2B). As regard locoregional management, either concomitant, with surgery or radiotherapy alone, survival is the same (Fig. 2C).
- Stage IVB: there were 28 cases and only 23 patients were treated with 17 different strategies. The best results were obtained with induction chemotherapy and concomitant CT-RT, or sequential CT/RT. Six patients (26%) were controlled, three recurred, and no one could be rescued.
- Stage IVC: there were three patients and only two were treated; no one could be controlled.

Median (range) follow-up for Stage 0 was 8.39 years (1-21 years); for Stage I, 6.15 years (0-28 years); for Stage II, 6.34 years (0-36 years); for Stage III, 2.67 years (0-31 years); for Stage IVA, 1.51 years (0-17 years); for Stage IVB, 1.08 years (0-9 years); and for Stage IVC, 2.88 years (0-6 years).

Survival by stage at 5 and 10 years was as follows: for Stage 0, 100% in both time periods; for Stage I, 86.3% and 81.7%; for Stage II, 81.2% and 75.8%; for Stage III, 46.5% and 41.3%; for Stage IVA, 28.3% and 24.9%; for Stage IVB, 8.7% and 0%; and for Stage IVC, only one patient survived at 5 years (Fig. 3).

Discussion

In our population, age, gender, and presentation subsite were similar to those reported in world literature[10].

Laryngeal cancer treatment depends on clinical stage (early or advanced), expected functional outcomes, patient wishes, and experience of the multidisciplinary team in the management of laryngeal cancer[4].

At 0, I, and II early stages, the main treatment in our study was external beam radiotherapy, since the same control is obtained as with surgery and voice function results are better[11,12]. In case of recurrence, rescue surgery is offered, with very high disease control[13].

At Stage III, surgery is no longer the first treatment option, given that it has been replaced by organ preservation with concomitant radiotherapy, either with cetuximab or platinum salts[14,15]. Other management options include induction chemotherapy in patients with high tumor load[16], or surgery alone if the patient accepts it, with or without adjuvant radiotherapy[17,18]. In the presence of recurrence, curative surgery is possible in few cases (9%)[19,20].

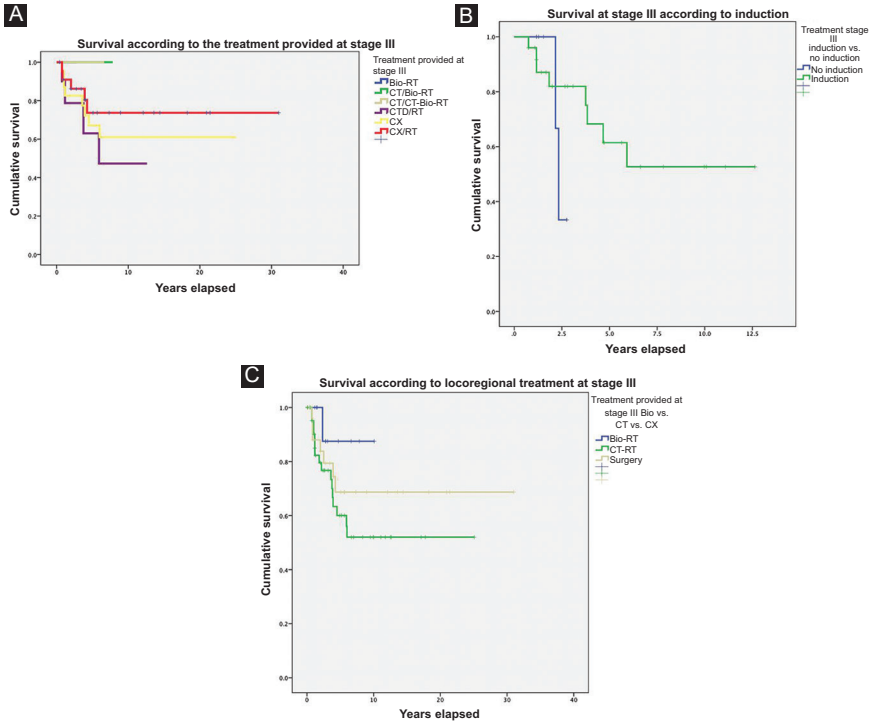

Figure 1. *Survival for Stages III.* **A:** *survival according to the treatment provided with different modalities.* **B:** *survival according to the use of induction chemotherapy.* **C:** *survival according to the use of bioradiotherapy. Bio: cetuximab; CX, surgery; CT, chemotherapy; CTD: doublet; RT: radiotherapy.*

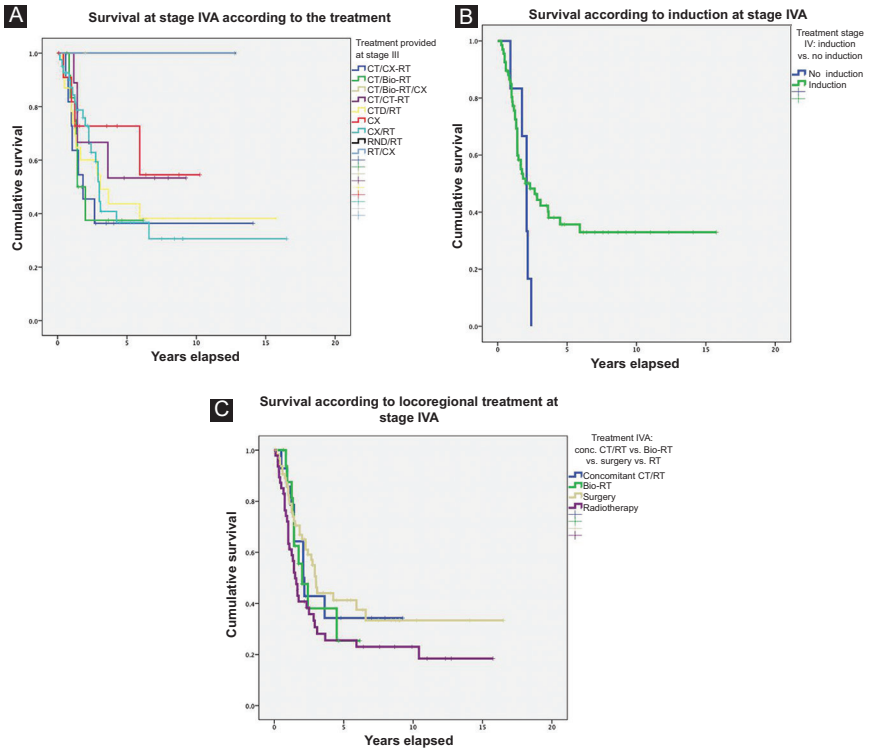

Figure 2. *Survival for Stages IV.* **A:** *survival to the treatment administered with the nine modalities.* **B:** *survival according to the use of induction chemotherapy.* **C:** *survival according to the locoregional treatment strategy. Bio: cetuximab; CX: surgery; RND: radical neck dissection; CT: chemotherapy; QTD: doublet; RT: radiotherapy.*

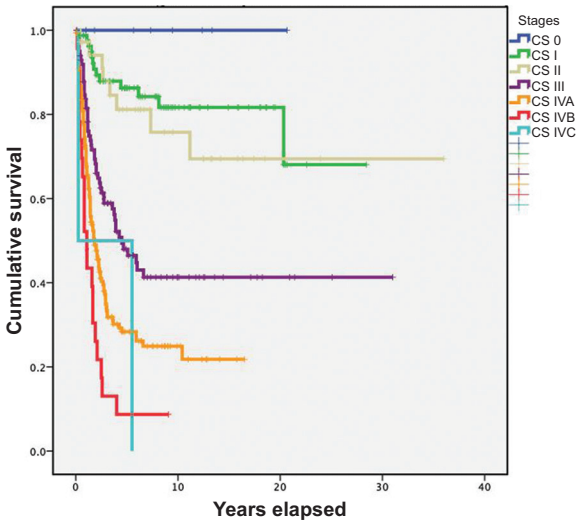

Figure 3. *Survival according to the stage.*

At IVA stage, surgery is indicated[21,22]. However, in patients who reject it, treatment with induction chemotherapy could be considered[16]. If these patients exhibit a response higher than 50%, our recommendation is to continue with concomitant management with cetuximab or platinum salts[15]. If this response is not obtained, they would be candidates for radical laryngectomy[23,24]. No locoregional treatment is superior to the others.

Patients at Stage IVB, due to their high tumor burden, should be treated with induction chemotherapy and subsequent concomitant management with cetuximab or chemotherapy, depending on their performance status[25]. The prognosis is generally poor in the short term.

In our study, there were only two patients at Stage IVC; they received induction chemotherapy without response. This treatment was administered before the results of the extreme study[26] were available, which probably would have changed the therapeutic modality they were offered.

Conclusions

Patients with laryngeal cancer should be treated according to clinical stage, comorbidities, and experience of the multidisciplinary team specialized in head-and-neck cancer.

At clinical Stage 0, if the lesion is localized, it should be treated with vocal cord stripping, or with external radiotherapy in patients with multicentric or recurrent tumors. At Stages I and II, the treatment with the best functional results and voice quality is external beam radiotherapy, although there are also surgical options. At clinical Stage III, the goal is organ preservation, which is why treatment should be concomitant management with cetuximab or chemotherapy. Induction chemotherapy might increase survival at this stage. At clinical Stage IVA, surgery is indicated, although it does not increase survival in comparison with concomitant management. In these patients, induction chemotherapy appears to increase survival. Due to their tumor load, Stage IVB should be treated with induction chemotherapy or concomitant management with cetuximab or chemotherapy, according to patient performance status and comorbidities. Stage IVC should be treated with chemotherapy.

This study has the limitation of being retrospective; for this reason, oncological results should be evaluated in prospective studies, with the proposed treatment guidelines and with long-term follow-up.

Acknowledgments

To the patients, who trusted us.

Conflicts of interests

The authors declare that there were no conflicts of interest during the development and writing of this manuscript.

Ethical responsibilities

Protection of human and animal subjects. The authors declare that no experiments have been performed on humans or animals for this research.

Confidentiality of data. The authors declare that they have followed the protocols of their work place on the publication of patient data.

Right to privacy and informed consent. The authors have obtained informed consent from the patients and/or subjects referred to in the article. This document is in the possession of the corresponding author.

References

1. Global Cancer Observatory. (Consultado el 2/5/2019.) Disponible en: http://gco.iarc.fr
2. Shen Z, Lin L, Cao B, Zhou C, Hao W, Ye D. LZTS2 promoter hypermethylation: a potential biomarker for the diagnosis and prognosis of laryngeal squamous cell carcinoma. World J Surg Oncol. 2018;16:42.
3. Steuer CE, El-Deiry M, Parks JR, Higgins KA, Saba NF. An update on larynx cancer. *CA Cancer J Clin.* 2017;67:31-50.
4. Obid R, Redlich M, Tomeh C. The treatment of laryngeal cancer. Oral Maxillofac Surg Clin N Am. 2019;31:1-11.
5. Rosa V, Fores J, Silva E, et al. Interdisciplinary interventions in the perioperative rehabilitation of total laryngectomy: an integrative review. *Clinics.* 2018;73(Suppl 1). doi:10.6061/clinics/2018/e484s

6. Salvador-Coloma C, Cohen E. Multidisciplinary Care of Laryngeal Cancer. *J Oncol Pract.* 2016;12(8):717-724. doi:10.1200/JOP.2016.014225
7. Gama RR, Carvalho AL, Longatto Filho A, Scorsato AP, López RV, Rautava J, et al. Detection of human papillomavirus in laryngeal squamous cell carcinoma: Systematic review and meta-analysis. Laryngoscope. 2016;126:885-93.
8. Li X, Gao L, Li H, Gao J, Yang Y, Zhou F, et al. Human papillomavirus infection and laryngeal cancer risk: a systematic review and meta-analysis. J Infect Dis. 2013;207:479-88.
9. Herrera-Gómez A. Demografía del cáncer laríngeo en el Instituto Nacional de Cancerología. Cir Cir. 2009;77:353-7.
10. Morse E, Fujiwara RJT, Judson B, Mehra S. Treatment delays in laryngeal squamous cell carcinoma: a national cancer database analysis. Laryngoscope. 2018;128:2751-8.
11. van Loon Y, Hendriksma M, Langeveld TPM, de Jong MA, Baatenburg de Jong RJ, Sjögren EV. Treatment preferences in patients with early glottic cancer. Ann Otol Rhinol Laryngol. 2018;127:139-45.
12. Patel KB, Nichols AC, Fung K, Yoo J, MacNeil SD. Treatment of early stage supraglottic squamous cell carcinoma: meta-analysis comparing primary surgery versus primary radiotherapy. Otolaryngol Head Neck Surg. 2018;47:19.
13. Cheraghlou S, Kuo P, Mehra S, Yarbrough WG, Judson BL. Salvage surgery after radiation failure in T1/T2 larynx cancer: outcomes following total versus conservation surgery. Otolaryngol Head Neck Surg. 2018; 158:497-504.
14. Tang Z-X, Gong J-L, Wang Y-H, Li ZH, He Y, Liu YX, et al. Efficacy comparison between primary total laryngectomy and nonsurgical organ-preservation strategies in treatment of advanced stage laryngeal cancer: A meta-analysis. Medicine (Baltimore). 2018;97:e10625.
15. Mesía R, García-Sáenz JA, Lozano A, Pastor M, Grau JJ, Martínez-Trufero J, et al. Could the addition of cetuximab to conventional radiation therapy improve organ preservation in those patients with locally advanced larynx cancer who respond to induction chemotherapy? An Organ Preservation Spanish Head and Neck Cancer Cooperative Group Phase 2 Study. Int J Radiat Oncol Biol Phys. 2017;97:473-80.
16. Lefebvre JL, Pointreau Y, Rolland F, Alfonsi M, Baudoux A, Sire C, et al. Induction chemotherapy followed by either chemoradiotherapy or bioradiotherapy for larynx preservation: the TREMPLIN randomized phase II study. J Clin Oncol. 2013;31:853-9.
17. Smee R, Williams JR, Kotevski DP. Management of locally advanced T3-4 glottic laryngeal carcinomas. J Laryngol Otol. 2018;132:642-50.
18. Li M, Zhang T, Tan B, Yu M, Zhang B. Role of postoperative adjuvant radiotherapy for locally advanced laryngeal cancer: a meta-analysis. Acta Otolaryngol (Stockh). 2019;139:172-7.
19. Hay A, Simo R, Hall G, Tharavai S, Oakley R, Fry A, et al. Outcomes of salvage surgery for the oropharynx and larynx: a contemporary experience in a UK Cancer Centre. Eur Arch Otorhinolaryngol. 2019;276:1153-9.
20. Pantvaidya GH, Raina S, Mondal A, Deshmukh A, Nair D, Pai P, et al. Total laryngectomy: surgical morbidity and outcomes — a case series. Indian J Cancer. 2017;54:621-5.
21. Francis E, Matar N, Khoueir N, Nassif C, Farah C, Haddad A. T4a laryngeal cancer survival: retrospective institutional analysis and systematic review. Laryngoscope. 2014;124:1618-23.
22. García Lorenzo J, Montoro Martínez V, Rigo Quera A, Codina Aroca A, López Vilas M, Quer Agustí M, et al. Modifications in the treatment of advanced laryngeal cancer throughout the last 30 years. Eur Arch Otorhinolaryngol. 2017;274:3449-55.
23. Gorphe P, Matias M, Blanchard P, Even C, Ferte C, Tao Y, et al. Outcomes following laryngectomy refusal after insufficient response to induction chemotherapy. Laryngoscope. 2017;127:1791-6.
24. Semrau S, Schmidt D, Lell M, Waldfahrer F, Lettmaier S, Kuwert T, et al. Results of chemoselection with short induction chemotherapy followed by chemoradiation or surgery in the treatment of functionally inoperable carcinomas of the pharynx and larynx. Oral Oncol. 2013;49:454-60.
25. Nishikawa D, Hanai N, Ozawa T, Hirakawa H, Suzuki H, Nakashima T, et al. Role of induction chemotherapy for N3 head and neck squamous cell carcinoma. Auris Nasus Larynx. 2015;42:150-5.
26. Vermorken JB, Mesia R, Rivera F, Remenar E, Kawecki A, Rottey S, et al. Platinum-based chemotherapy plus cetuximab in head and neck cancer. N Engl J Med. 2008;359:1116-27.