Check for updates

ORIGINAL ARTICLE

Is it possible to differentiate benign/malignant unilateral sinonasal diseases from clinical and radiological findings? A new algorithm for clinical management

¿Es posible diferenciar las enfermedades sinonasales unilaterales benignas y malignas a partir de los hallazgos clínicos y radiológicos? Un nuevo algoritmo para el manejo clínico

Zülküf Küçüktağ, Bülent Öcal, Cem Saka, Esma Altan, and Emel Çadallı-Tatar*
Department of Otolaryngology Head and Neck Surgery, Etlik City Hospital, Ankara, Turkiye

Abstract

Objective: *The aim of this study is to determine the relationships between demographic, clinical, and radiological characteristics of patients with unilateral sinonasal diseases and the type of pathology, and to present a new algorithm that can help clinicians in the management of these patients.* **Method:** *The study included 243 patients who underwent surgery because of unilateral sinonasal diseases between 2014 and 2022. Patients were first divided into inflammatory and neoplastic groups and the neoplastic group was divided into benign and malignant groups.* **Results:** *Epistaxis and orbital complaints were seen significantly more in the neoplastic group, and anosmia/hyposmia in the inflammatory group. Epistaxis, orbital complaints, and pain were seen significantly more in the malignant group than in the benign group. On computed tomography scan, bone erosion and invasion of adjacent structures were seen significantly more in the neoplastic group and the malignant group.* **Conclusions:** *We present a new algorithm based on our clinical experience that can be used in the clinical management of unilateral sinonasal diseases.*

Keywords: *Unilateral sinonasal diseases. Paranasal sinuses. Endoscopic sinus surgery.*

Resumen

Objetivo: *Determinar las relaciones entre las características demográficas, clínicas y radiológicas de los pacientes con enfermedades sinonasales unilaterales y el tipo de patología, y presentar un nuevo algoritmo que pueda ayudar a los clínicos en el manejo de estos pacientes.* **Método:** *El estudio incluyó 243 pacientes intervenidos quirúrgicamente por enfermedades sinonasales unilaterales entre 2014 y 2022. Los pacientes se dividieron en primer lugar en grupos inflamatorio y neoplásico, y el grupo neoplásico se dividió en grupos benigno y maligno.* **Resultados:** *La epistaxis y las molestias orbitarias se observaron significativamente más en el grupo neoplásico, y la anosmia/hiposmia en el grupo inflamatorio. La epistaxis, las molestias orbitarias y el dolor se observaron significativamente más en el grupo maligno que en el benigno. En la tomografía computarizada, la erosión ósea y la invasión de estructuras adyacentes se observaron significativamente más en el grupo neoplásico y en el grupo maligno.* **Conclusiones:** *Presentamos un nuevo algoritmo basado en nuestra experiencia clínica que puede ser utilizado en el manejo clínico de las enfermedades sinonasales unilaterales.*

Palabras clave: *Enfermedades sinonasales unilaterales. Senos paranasales. Cirugía sinusal endoscópica.*

***Correspondence:**
Zülküf Küçüktağ
E-mail: zkucuk79@yahoo.com

Date of reception: 21-08-2024
Date of acceptance: 25-11-2024
DOI: 10.24875/CIRUE.M24000931

Cir Cir (Eng). 2026;94(2):174-183
Contents available at PubMed
www.cirugiaycirujanos.com

2444-0507/© 2024 Academia Mexicana de Cirugía. Published by Permanyer. This is an open access article under the terms of the CC BY-NC-ND license (http://creativecommons.org/licenses/by-nc-nd/4.0/).

Introduction

Unilateral sinonasal disease has been reported to be relatively rare, with frequency ranging from 2.5% to 6%[1,2]. The patient usually presents with complaints, such as nasal obstruction, purulent discharge, anterior and posterior nasal drainage, anosmia or dysosmia, nasal bleeding, headache, facial pain/pressure, and facial swelling. There may also be accompanying vision loss, limitation of eye movements, and cranial complaints. The etiology is usually an inflammatory disease that can be managed conservatively with medical treatment, but surgical treatment is required if there is no response to medical treatment and in neoplastic cases[3,4].

The presence of unilateral nasal symptoms or pathology should be regarded with caution, as during the early stages of sinonasal neoplasms, they may also present with subtle symptoms that mimic an inflammatory pathology[5]. Some authors have suggested that unilateral sinonasal masses should always be considered neoplastic until proven otherwise[4]. Therefore, early diagnosis and accurate planning are important in the treatment of these patients.

Whether or not an in-office biopsy should be performed in cases of unilateral nasal masses is also a matter of controversy. Harvey and Dalgorf[6], recommended that in-office biopsy be performed in cases of suspected malignant pathology. In contrast, Silva et al.[7] stated that in-office biopsies are nearly always unnecessary because they do not change the subsequent management of these patients.

The number of articles and cases published on unilateral sinonasal diseases are limited. Therefore, a common approach model for the management of these patients has not been established, and each clinic has its own different practices. Moreover, there are only two diagnostic algorithms to guide otorhinolaryngologists in the evaluation of these patients[7,8]. The aim of this study was to determine the complaints, clinical and radiological features, and histopathological results of patients who underwent surgery for unilateral sinonasal disease, and to present a diagnostic algorithm created on the basis of our experience, which would be able to guide the management of these patients.

Method

The study was approved by the ethics committee (AEŞH-EK1-023-107). A retrospective review was made of the medical files of patients who presented with sinonasal complaints, were found to have unilateral sinus opacification on computed tomography (CT) scan, and who then underwent surgery in our clinic between 2014 and 2022. For all patients with unilateral nasal symptoms, a detailed medical history was taken, followed by a complete nasal examination, including nasal endoscopic examination. CT imaging was performed in all patients. Pre-operative biopsy was performed on masses that were not smooth-surfaced, had an irregular surface in the shape of a bunch of grapes, were hard and adhered to the surrounding tissues, and caused damage to the turbinates, septum and/or lateral nasal wall on nasal endoscopic examination, that is, had the potential to be neoplastic, even if there was no bone erosion and extension to the surrounding tissues on radiological imaging. A biopsy was performed after excluding the presence of intracranial herniation and vascular tumor in the mass by endoscopic nasal examination and CT scan. Pre-operative biopsy specimens were obtained using a rigid endoscope and through-cutting forceps. The biopsy specimens were immediately fixed with 10% formalin and sent to the pathology department. The pre-operative CT images were reviewed by an otolaryngologist. This evaluation included the presence of calcification, thickening of the bone wall, bone erosion, and invasion of adjacent structures, and grading of the sinus opacification using the Lund-Mackay scoring system. Endoscopic surgery was performed in cases with inflammatory conditions not responsive to medical treatment and those with neoplastic lesions.

Patients with previous sinus surgery, retentions cysts, bilateral sinonasal diseases, or with incomplete data were excluded from the study. The patients were grouped according to the histopathological diagnosis as inflammatory and neoplastic. The neoplastic group was then divided into two groups as benign and malignant.

Statistical analysis

Data collected in the study were analyzed statistically using SPPS Statistics for Windows vn. 20.0 software (IBM Corp., Armonk, NY, USA). Descriptive analyses were stated as number and percentage for categorical variables, and as mean and standard deviation values for continuous variables. The conformity of continuous variables to normal distribution was assessed with the Shapiro-Wilk test, and the averages

of the paired groups not conforming to normal distribution were compared with the Mann-Whitney U-test. In the analysis of discrete variables, the Fischer Exact Test was applied. Correlations between variables were analyzed with the Kappa Test, evaluated as Kappa value ≤ 0.4 indicating weak agreement, 0.41-0.60 moderate, 0.61-0.80 strong, and 0.81-1.00 as very strong. The level of statistical significance was accepted as $p < 0.05$ in the analyses.

Results

Evaluation was made of a total of 243 patients treated for unilateral sinonasal disease, with complete information available. The patients comprised 163 males and 80 females with a mean age of 42.2 years (range, 9-84 years). The demographic and clinical characteristics of the groups are as shown in table 1. The groups were compared in terms of age, gender, side of pathology, presence of recurrence, magnetic resonance imaging (MRI) and pre-operative biopsy requirement (Table 2). The patients in both groups were separated into 2 age groups as under 50 years old and over 50 years old. In the neoplastic group, 58 (55.2%) patients were aged > 50 years, and 29 (21%) patients in the inflammatory group were aged > 50 years. The difference between the two groups was statistically significant. In addition, the requirement for MRI and pre-operative biopsy was statistically higher in the neoplastic group than in the inflammatory group.

Antrachoanal polyp was found to be the most common inflammatory pathology, inverted papilloma was the most common benign neoplastic pathology, and spindle cell mesenchymal tumor was the most common malignant neoplastic pathology according to the results of definitive pathology (Table 3).

In all groups, the most common complaint on presentation was nasal obstruction (n: 218, 89.7%) and the least common complaint was neurological complaints (Table 4). Only 2 patients in the neoplastic group had neurological complaints, one of which was a patient with meningoencephalocele who presented with dizziness, and the other was a patient with squamous cell carcinoma with symptoms of meningitis. Epistaxis and orbital complaints were significantly more common in neoplastic pathologies than in inflammatory pathologies. Anosmia/hyposmia was present at a significantly higher rate in the inflammatory group than in the neoplastic groups. Significantly higher rates of epistaxis, orbital complaints, and head/facial pain were determined in the malignant neoplastic group than in the benign neoplastic group.

Pre-operative biopsy was required in 73 of the total 243 patients, as 12 determined with inflammatory polyps and 61 with neoplastic pathologies. The pre- and post-operative biopsy results were compatible with each other in all 12 patients in the inflammatory group. In the neoplastic group, the pre- and post-operative biopsy results were inconsistent with each other in 9 patients. The Kappa Test was performed to evaluate the compatibility of pre-operative biopsies with post-operative biopsies in terms of benign and malignancy. The compatibility rate of all the pre- and post-operative biopsy results was found to be 87.7%. A statistically significant and very good agreement was found between the two biopsy results (Kappa = 0.89; $p < 0.001$). In the neplastic group, pre-operative biopsy was performed in 39 of 61 patients because of the presence of bone erosion on CT and in 22 patients because the appearance of the mass on endoscopic nasal examination was suspicious for neoplasm despite the absence of destructive and invasion findings on CT. In the inflammatory group, although there were no suspicious findings on CT scans in 3 of 12 patients who underwent pre-operative biopsy, it was decided to perform a biopsy based on the endoscopic examination findings of the mass.

The pre-operative biopsy gave seriously inaccurate results mainly in 3 patients who were actually malignant but had benign pre-operative biopsy results. In one of these patients, the pre-operative biopsy result was acute inflammation, and the post-operative biopsy result was T/NK cell lymphoma. In another patient with a pre-operative biopsy result of hemangioperistoma, the post-operative biopsy result was renal cell carcinoma metastasis. In the last patient, the pre-operative biopsy result was inverted papilloma and the post-operative biopsy result was non-keratinized squamous cell carcinoma. In 1 of the other 6 patients, the pre-operative biopsy result was olfactory neuroblastoma, while the post-operative biopsy result was solitary plasmacytoma. In the remaining 5 patients, the pre- and post-operative biopsy results were similarly reported as benign. The pre-operative biopsy results of these patients were nasal polyp, granulation tissue, normal mucosa, non-tumoral tissue, and nasal polyp, and the post-operative biopsy results were reported as inverted papilloma, cavernous hemangioma, hamartoma, schwannoma, and hamartoma, respectively.

Paranasal sinus CT was performed on all the patients. The CT findings are as shown in table 5.

Table 1. Demographic and clinical characteristics of the groups

Parameters	Neoplastic		Total neoplastic n (%)	Inflammatory n (%)
	Benign n (%)	Malignant n (%)		
Number of patients	72 (68.5)	33 (31.5)	105 (43.2)	138 (56.8)
Age (years) (mean ± SD)	49.51 ± 16.62	53.0 ± 16.34	50.61 ± 16.54	35.85 ± 16.71
Gender (male/female)	53 (73.6)/19 (26.4)	22 (66.7)/11 (33.3)	75 (71.4)/30 (28.6)	88 (63.8)/50 (36.2)
Side (right/left)	43 (59.7)/29 (40.3)	16 (48.5)/17 (51.5)	59 (56.2)/46 (43.8)	63 (45.7)/75 (54.3)
Involved sinuses				
Maxillary	41 (56.9)	22 (66.7)	63 (60.0)	117 (84.8)
Anterior ethmoid	38 (52.8)	21 (63.6)	59 (56.2)	54 (39.1)
Posterior ethmoid	38 (52.8)	22 (66.7)	60 (57.1)	37 (26.8)
Frontal	30 (41.7)	18 (54.5)	48 (45.7)	32 (23.2)
Sphenoid	19 (26.4)	21 (63.6)	40 (38.1)	15 (10.9)
Type of surgery				
Endoscopic surgery	65 (90.3)	26 (78.8)	91 (86.7)	132 (95.7)
Open and/or combined surgery	7 (9.7)	7 (21.2)	14 (13.3)	6 (4.3)
Recurrence (+)	1 (1.4)	5 (15.2)	6 (5.7)	4 (2.9)
Mean time to recurrence (months)	0.35 ± 2.94	1.09 ± 2.89	0.58 ± 2.93	0.34 ± 2.31
Mean follow-up time (months)	42.49 ± 19.53	45.25 ± 20.64	43.34 ± 19.82	41.78 ± 17.47

SD: standard deviation.

Table 2. Comparison of the clinical characteristics of the groups

Parameters	Neoplastic			Total neoplastic n (%)*	Inflammatory n (%)*	p**
	Benign n (%)*	Malignant n (%)*	p**			
Age				58 (55.2)	29 (21.0)	
≥ 50 years	41 (56.9)	17 (51.5)	0.67	47 (44.8)	109 (79.0)	< 0.001
< 50 years	31 (43.1)	16 (48.5)				
Gender						
Male	53 (73.6)	22 (66.7)	0.49	75 (71.4)	88 (63.8)	0.21
Female	19 (26.4)	11 (33.3)		30 (28.6)	50 (36.2)	
Side						
Right	43 (59.7)	16 (48.5)	0.29	59 (56.2)	63 (45.7)	0.12
Left	29 (40.3)	17 (51.5)		46 (43.8)	75 (54.3)	
Presence of recurrence side	1 (1.4)	5 (15.2)	0.01	6 (5.7)	4 (2.9)	0.33
MRI requirement	22 (30.6)	25 (75.8)	< 0.001	47 (44.8)	12 (8.7)	< 0,001
Preoperative biopsy requirement	38 (52.8)	23 (69.7)	0.13	61 (58.1)	12 (8.7)	< 0.001

*Column percentage.
**Fischer's exact test. MRI: magnetic resonance imaging.

Bony erosion was detected in 39 of 105 (37.1%) patients in the neoplastic group and in 9 of 138 (6.5%) patients in the inflammatory group. Skull base, orbital wall and lateral nasal wall erosion, and invasion of adjacent structures were significantly higher in the neoplastic group than in the inflammatory group. There was no significant difference between the two groups in terms of the presence of calcification and increased thickness of the bone wall.

MRI was requested for 59 (24.2%) patients with orbital wall, lateral nasal wall or skull base erosion on CT scan. MRI was performed on 44 (47.8%) patients in the neoplastic group, 12 (8.7%) patients in the inflammatory group, and on 75.8% of malignant group and 30.6% of benign neoplastic group. There was a statistically significant difference between the all groups in terms of MRI requirement.

Table 3. Distribution of diseases according to the results of definitive pathology

Diagnosis	Number of patients, n (%)
Inflammatory	138 (56.8)
Chronic rhinosinusitis	19 (13.8)
Fungal rhinosinusitis	7 (5.1)
Nasal polyp	38 (27.5)
Antrochoanal polyp	71 (51.4)
Mucocele	3 (2.2)
Neoplastic	105 (43.2)
Benign	72 (68.6)
Inverted papilloma	47 (65.3)
Hemangioma	4 (5.6)
Osteoma	7 (9.7)
Menengioma	3 (4.2)
Schwannoma	1 (1.4)
Meningoencephalocele	1 (1.4)
Hamartoma	3 (4.2)
Ameloblastoma	1 (1.4)
Cystic mass	2 (2.8)
Aneurysmal bone cyst	1 (1.4)
Hemangiopericytoma	1 (1.4)
Rosai dorfman disease	1 (1.4)
Malignant	33 (31.4)
Squamous cell carcinoma	4 (12.1)
Spindle cell mesenchymal tumor	5 (15.2)
NK/T cell lymphoma	1 (3.03)
Other lymphomas	1 (3.03)
Inverted papilloma with malignant change	4 (12.1)
Olfactory neuroblastoma	2 (6.1)
Salivary gland ductal carcinoma	1 (3.03)
Round cell malignant tumor	3 (9.1)
Adenoid cystic carcinoma	4 (12.1)
Solitary plasmacytoma	3 (9.1)
Renal cell carcinoma metastasis	1 (3.03)
Malignant melanoma	3 (9.1)
Small cell malignant tumor	1 (3.03)
Total	243

Discussion

Although unilateral sinonasal diseases are rarely seen, they present a great challenge to clinicians because of the difficulties in diagnosis and treatment. Perhaps the main reason for this is the small number of articles and cases presented on this topic. When the articles were analyzed, this study presented the highest number of patients related to this subject. In addition, the number and diagnostic diversity of neoplastic and especially malignant pathologies in this study was remarkable.

Most unilateral sinonasal pathologies are benign. Lathi et al.[9] reported that 71.4% of cases were inflammatory and 28.6% were neoplastic, and Gomes et al.[8] stated these rates as 67.4% and 21.9%. In another study, these rates were reported as 83.1% inflammatory and 16.9% neoplastic pathologies[10]. The results of the present study showed inflammatory pathology in 56.8% of the cases and neoplastic pathologies in 43.2%.

Inflammatory pathologies are generally seen more in children and at young ages, whereas neoplastic pathologies are seen more at advanced ages. Nair et al.[10] reported that 86.3% of patients in the inflammatory group were aged < 50 years and 55.5% of the neoplastic group were aged > 50 years. It was similarly stated in a study by Lee[4], that the mean age of patients in the neoplastic group was older than that of the inflammatory group. The present study results on this point were similar to those of previous studies. It was seen that 55.2% of the neoplastic group patients were aged > 50 years and 79% of the inflammatory group were aged < 50 years. The mean ages were determined to be 35.8 years in the inflammatory group and 50.6 years in the neoplastic group.

Patients usually present with complaints, such as nasal obstruction, nasal discharge, epistaxis, and head/face pain. Silva et al.[7] determined the complaints on presentation of patients with malignancy to be nasal obstruction in 60%, a feeling of pressure in the face in 40%, headache in 30%, and epistaxis in 10%. The complaint of numbness in the face was present in 20 (13%) of 153 patients, and 4 (20%) of these had malignant disease. In the study by Lee[4], there was reported to be more purulent nasal discharge and foul smell in the inflammatory group; while headache, pain and swelling in the cheek, epistaxis, and exophthalmus

Table 4. Comparison of the complaints on presentation and endoscopic examination findings of the groups

Symptoms	Neoplastic			Total neoplastic n (%)*	Inflammatory n (%)*	p**
	Benign n (%)*	Malignant n (%)*	p**			
Nasal obstruction	64 (88.9)	28 (84.8)	0.54	92 (87.6)	126 (91.3)	0.39
Nasal discharge	4 (5.6)	1 (3.0)	0.90	5 (4.8)	14 (10.1)	0.15
Epistaxis	6 (8.3)	11 (33.3)	0.003	17 (16.2)	1 (0.7)	< 0.001
Anosmia or hyposmia	5 (6.9)	4 (12.1)	0.45	9 (8.6)	32 (23.2)	0.003
Headache or facial pain	9 (12.5)	16 (48.5)	< 0.001	25 (23.8)	28 (20.3)	0.53
Orbital complaints	6 (8.3)	10 (30.3)	0.007	16 (15.2)	3 (2.2)	< 0.001
Neurological complaints	1 (1.4)	1 (3.0)	0.53	2 (1.9)	0	0.18
Nasoendoscopy (polyp/mass)	63 (87.5)	25 (75.8)	0.15	88 (83.8)	106 (76.8)	0.19

*Column percentage.
**Fischer's exact test.

Table 5. Comparison of the computed tomography (CT) findings of the groups

CT findings	Neoplastic			Total Neoplastic n (%)*	Inflammatory n (%)*	p**
	Benign n (%)*	Malignant n (%)*	p**			
Bony erosion	15 (20.8)	24 (72.7)	< 0.001	39 (37.1)	9 (6.5)	< 0.001
Thickening of the bone wall	16 (22.2)	2 (6.1)	0.05	18 (17.1)	24 (17.4)	0.98
Calcifications	3 (4.2)	4 (12.1)	0.20	7 (6.7)	7 (5.1)	0.59
Orbital wall erosion	11 (15.3)	14 (42.4)	0.006	25 (23.8)	4 (2.9)	< 0.001
Skull base erosion	5 (6.9)	9 (27.3)	0.01	14 (13.3)	1 (0.7)	< 0.001
Invasion into adjacent structures	7 (9.7)	16 (48.5)	< 0.001	23 (21.9)	3 (2.2)	< 0.001
Lund-Mackay scores (mean ± Std. deviation) (Z) –2.07	6.53 ± 3.65	8.48 ± 4.95	0.03	7.14 ± 4.18	4.98 ± 3.11	< 0.001 –4.13

*Column percentage.
**Fischer's exact test.
***Mann Whitney U-test.

were seen more in the neoplastic group. Gomes et al.[8] reported a significantly higher rate of epistaxis, facial pain, and numbness in the cheek in the neoplastic group and of nasal discharge and post-nasal discharge in the inflammatory group. In the present study, epistaxis and orbital complaints were seen to be findings specific to the neoplastic group, and anosmia/hyposmia to the inflammatory group. Furthermore, epistaxis, orbital complaints and head/facial pain were significantly higher in the malignant neoplastic group than in the benign neoplastic group.

In some studies, there has been shown to be a greater probability that the presence of polyp in nasal endoscopic examination will be neoplastic rather than inflammatory[4,7,8]. However, in this study no significant relationship was found between the presence of polyp in endoscopic examination and whether the pathology was inflammatory/neoplastic or benign/malignant.

There is ongoing debate on the subject of the need for MRI and when it should be performed in unilateral sinonasal diseases. Many surgeons request an additional imaging method following suspicious findings on CT scans. Rudralingam et al.[2] recommended that MRI is requested for every patient determined with bone erosion on CT. Harvey and Dalgorf[6] stated that CT and MRI are

complementary tests, and performing the two together provides the physician with more information about potential pathologies than either test can present alone, and therefore claimed that both CT and MRI are necessary in most cases. In contrast, Silva et al.[7] stated that MRI did not provide new information to that obtained on CT, and was therefore required for very few patients. Of the 153 patients evaluated by Silva et al. only 10 required MRI. This was performed following CT in patients with bone erosion in the lateral nasal wall or skull base, or those with central nervous system and/or orbital invasion. Of these 10 cases, new information that could not be obtained on CT was provided in 4 cases.

In the present study, MRI was performed on a total of 59 (24.2%) patients; 29 with orbital wall erosion, 15 with skull base erosion, and 15 with invasion outside the sinonasal area. The results of the study by Silva et al.[7] are naturally of great value as MRI is more expensive and time-consuming than CT, and as stated, MRI may not change the surgical approach. However, the question here is not whether or not new information can be obtained with MRI, but whether the relationship of the pathology with surrounding tissues and vascular structures can be fully revealed, and confirm the CT findings. MRI is also more superior in the differentiation of the mass and secretion. Therefore, CT and MRI findings should be evaluated together in selected patients.

Unilateral sinonasal masses should be evaluated as neoplastic until proven to the contrary. Therefore, it is important to know what the pathology is before surgery to plan the treatment. Nasal biopsies should be performed after physical examination and discounting meningoencephalocele and vascular mass with radiological imaging[11]. Harvey and Dalgorf[6] recommended that unless contraindicated, biopsy should be performed from the mass when malignant pathology is suspected and stated that this is an important step before making the treatment decision. The most striking study about the use of pre-operative biopsy in unilateral sinonasal masses is the study by Segal et al.[11] In this study, the accuracy of pre-operative biopsy of unilateral sinonasal masses was reported to be extremely high. In the study by Segal et al. of 46 patients with unilateral nasal mass who were operated on after biopsy was performed, the results of the pre-operative endoscopic biopsy were consistent with the results of the post-operative biopsy in 40 (86.9%). Tabaee et al.[12] compared 28 pre-operative biopsy samples with the final pathology. Pre-operative biopsy was found to have 71% sensitivity, 93% specificity, false positivity rate of 9%, and false negativity rate of 24%. Han et al.[13] reported nasal biopsy sensitivity of 43.7% and specificity of 98.9% for malignant tumors, and 78.2% and 96.2%, respectively, for benign tumors. Gomes et al.[8] reported inconsistency with the post-operative biopsy in only 3 of 40 patients who underwent pre-operative biopsy, and stated that generally there was very good agreement between the results of the two biopsies.

In contrast to previous studies, Silva et al.[7] claimed that pre-operative nasal biopsies were almost always unnecessary as they did not change the treatment method. In that study, pre-operative biopsy was not recommended for patients accepted as standard cases according to the physical examination and imaging results (no bone erosion on CT or neurological findings in the physical examination). According to Silva et al.[7] although pre-operative biopsy can provide a definitive diagnosis in some cases, the result for malignancy will not change the surgery to be applied whether it is negative or positive, and ultimately the mass will need to be surgically removed. This is also valid for patients who will receive post-operative chemotherapy and/or radiotherapy. Exceptions to this situation are only a few cases where there are evident findings of malignancy during the physical examination and a confirmative pre-operative biopsy can change the surgical approach. Silva et al.[7] reported that pre-operative biopsy was performed in only 1.5% of the study patients and the results did not affect the diagnosis and treatment method. It was also stated in the same study that pre-operative biopsy led to unnecessary costs and loss of time.

In the present study, the rate of agreement between the pre-operative and post-operative biopsy results was determined to be 87.7%. There was statistically significant very good agreement between the two biopsy results (Kappa = 0.89, $p < 0.001$). There is no need to perform a biopsy in cases with a smooth-surfaced mass resembling an inflammatory polyp not adhering to surrounding tissues determined in the endoscopic examination. There is also no need to perform a biopsy from masses resembling mucocele with regular borders causing expansion in the sinuses with a typical antrachoanal polyp appearance on CT imaging. However, biopsy must be performed for masses causing significant pain and

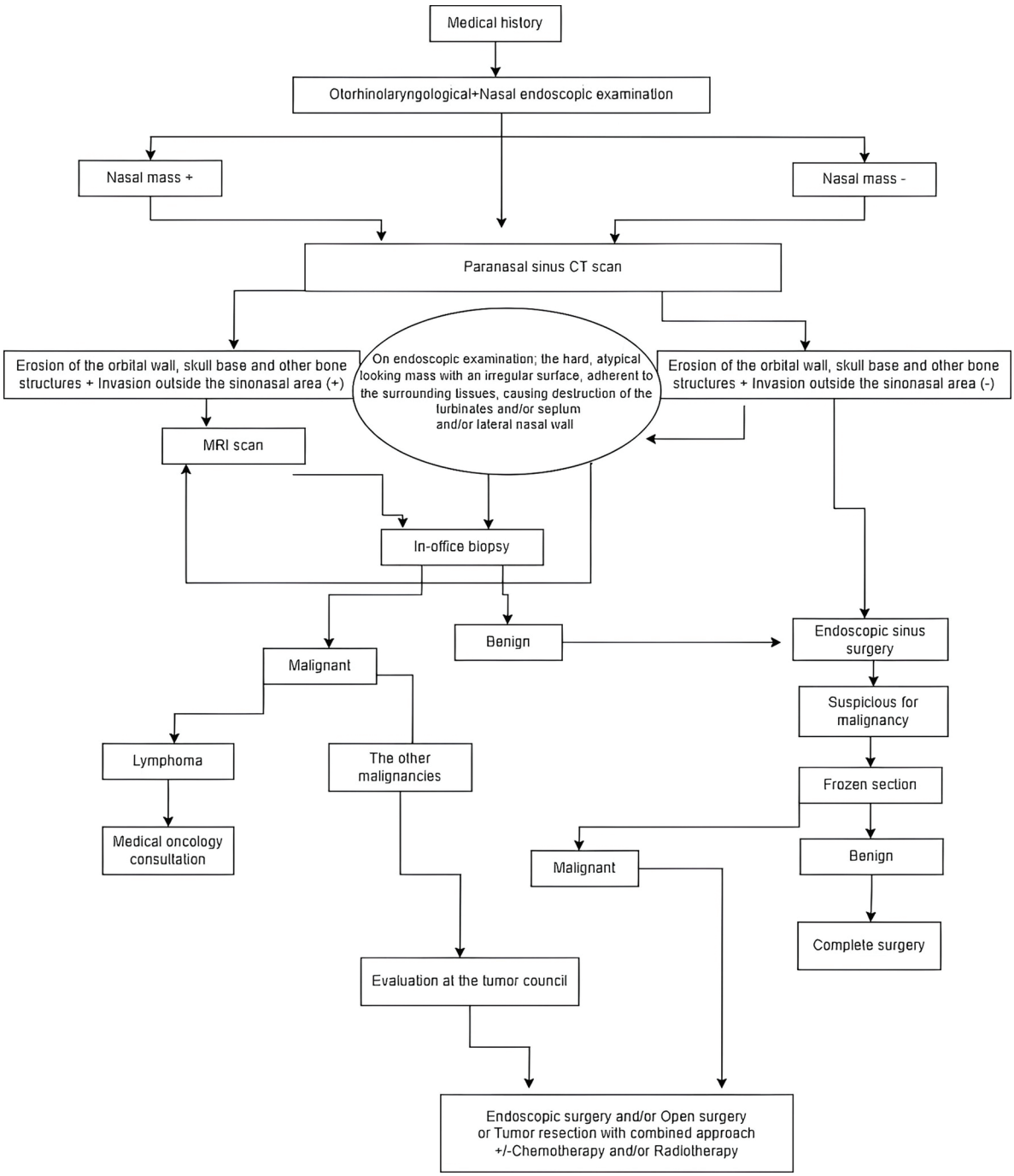

Figure 1. *Algorithm for the management of unilateral sinonasal diseases.*

swelling in the face, and orbital and cranial complaints, masses that on endoscopic examination do not have a smooth surface, are shaped like a bunch of grapes, are hard and adherent to the surrounding tissues, completely filling the nasal cavity and causing destruction in the turbinates, and for masses showing bone erosion and extension to surrounding tissues on radiological imaging, which are accepted as neoplastic. In our clinical practice, it is recommended that pre-operative biopsy is performed in masses with the above-listed characteristics in endoscopic nasal examination, even if there is no bone erosion on CT. Pre-operative biopsy may not change the type of surgery to be applied in most patients as stated by Silva et al.[7] However, it may affect the borders and extent of the surgery to be

applied. For example, to prevent recurrence if the pre-operative biopsy result is inverted papilloma, it is necessary to take an amount of bone from the place of origin of the mass together with excision of the mass. This is because papilloma enters between the trabeculae of the bone at the place of origin, and it is known that recurrence can develop from this. When the pre-operative biopsy result is lymphoma, medical and/or radiation oncology must be consulted before surgical treatment.

Bone erosion in unilateral sinonasal pathologies is almost only seen in neoplastic diseases, and some studies have even reported that bone erosion is a typical finding of malignancy[1,2,14,15]. However, Lee[4] determined bone erosion in 46.7% of benign patients and reported that most of these were mucocele. In the same study, it was stated that as mucocele is cystic with evident borders and causes regular bordered expansion in the sinus, it can be differentiated from malignant pathologies. Gomes et al.[8] stated that there was a significantly greater increase in bone erosion, bone remodeling, and periostal thickness in the neoplastic group. It was stated in the same study that the increase in calcification, bone remodeling, and periostal thickness was usually associated with benign neoplastic pathologies, whereas bone erosion and invasion of surrounding tissues were associated with malignant pathologies. In the present study; bone erosion, especially erosion of the orbital wall and skull base, invasion to adjacent structures, and the Lund-Mackay scores were seen to be significantly greater in the malignant group than in the benign group.

The different algorithms have been defined in the management of unilateral sinonasal diseases. The most well-known of these algorithms were presented by Silva et al.[7] and Gomes et al.[8] Taking our clinical experience into consideration, the aim of this study was to create a new algorithm which would be helpful to clinicians in the management of these patients. The new algorithm is shown in the figure 1. The most important difference of the new algorithm from the previous ones is that the appearance of the mass on endoscopic nasal examination is considered as important as other diagnostic tools in the management of these patients. MRI must be requested and pre-operative biopsy should be taken, not only for patients with bone erosion on CT, but also from masses with findings raising the suspicion of neoplasm in the endoscopic examination.

Conclusions

The results of this study have shown that epistaxis, orbital complaints, and head/face pain should suggest neoplastic pathologies, and hyposmia and/or anosmia, inflammatory pathologies. The visualization of bone erosion on CT, including the orbital wall and skull base, and the invasion of adjacent structures should firstly suggest neoplastic pathologies, especially malignant pathologies. Each center has a different clinical approach in the management of patients with unilateral sinonasal disease. Therefore, there is a need for further studies to be able to reach a consensus on this subject, and to be able to form a standard approach model.

Funding

The authors declare that they have not received funding.

Conflicts of interest

The authors declare no conflicts of interest.

Ethical considerations

Protection of human subjects and animals. The authors declare that no experiments involving humans or animals were conducted for this research.

Confidentiality, informed consent, and ethical approval. The authors have obtained approval from the Ethics Committee for the analysis of routinely collected and anonymized clinical data; therefore, individual informed consent was not required. Relevant ethical recommendations have been followed.

Declaration on the use of artificial intelligence. The authors declare that no generative artificial intelligence was used in the writing or creation of the content of this manuscript.

References

1. Ahsan F, El-Hakim H, Ah-See KW. Unilateral opacification of paranasal sinus CT scans. Otolaryngol Head Neck Surg. 2005;133:178-80.
2. Rudralingam M, Jones K, Woolford TJ. The unilateral opaque maxillary sinus on computed tomography. Br J Oral Maxillofac Surg. 2002; 40:504-7.
3. Kaplan BA, Kountakis SE. Diagnosis and pathology of unilateral maxillary sinus opacification with or without evidence of contralateral disease. Laryngoscope. 2004;114:981-5.
4. Lee JY. Unilateral paranasal sinus diseases: analysis of the clinical characteristics, diagnosis, pathology, and computed tomography findings. Acta Otolaryngol. 2008;128:621-6.

5. Karthikeya P, Mahima VG, Bhavna G. Sinonasal verrucous carcinoma with oral invasion. Indian J Dent Res. 2006;17:82-6.
6. Harvey RJ, Dalgorf DM. Chapter 10: sinonasal malignancies. Am J Rhinol Allergy. 2013;27 Suppl 1:S35-8.
7. Silva MP, Pinto JM, Corey JP, Mhoon EE, Baroody FM, Naclerio RM. Diagnostic algorithm for unilateral sinus disease: a 15-year retrospective review. Int Forum Allergy Rhinol. 2015;5:590-6.
8. Gomes P, Gomes A, Salvador P, Lombo C, Caselhos S, Fonseca R. Clinical assessment, diagnosis and management of patients with unilateral sinonasal disease. Acta Otorrinolaringol Esp (Engl Ed). 2020;71:16-25.
9. Lathi A, Syed MM, Kalakoti P, Qutub D, Kishve SP. Clinico-pathological profile of sinonasal masses: a study from a tertiary care hospital of India. Acta Otorhinolaryngol Ital. 2011;31:372-7.
10. Nair S, James E, Awasthi S, Nambiar S, Goyal S. A review of the clinicopathological and radiological features of unilateral nasal mass. Indian J Otolaryngol Head Neck Surg. 2013;65 Suppl 2:199-204.
11. Segal N, Gluck O, Bavnik Y, Plakht Y, Yakirevitch A. The usefulness of preoperative biopsy in unilateral nasal masses. Allergy Rhinol (Providence). 2014;5:53-5.
12. Tabaee A, Hsu AK, Kacker A. Indications, technique, safety, and accuracy of office-based nasal endoscopy with biopsy for sinonasal neoplasm. Int Forum Allergy Rhinol. 2011;1:225-8.
13. Han MW, Lee BJ, Jang YJ, Chung YS. Clinical value of office-based endoscopic incisional biopsy in diagnosis of nasal cavity masses. Otolaryngol Head Neck Surg. 2010;143:341-7.
14. Silver AJ, Baredes S, Bello JA, Blitzer A, Hilal SK. The opacified maxillary sinus: CT findings in chronic sinusitis and malignant tumors. Radiology. 1987;163:205-10.
15. Lehnerdt G, Weber J, Dost P. Unilateral opacification of the paranasal sinuses in CT or MRI: an indication of an uncommon histological finding. Laryngorhinootologie. 2001;80:141-5.