Check for updates

CLINICAL CASES

Solitary fibrous tumor of the abdominal wall: a new case with literature review

Tumor fibroso solitario de la pared abdominal: un nuevo caso con revisión de la literatura

María L. Ruiz-Juliá[1], Virgilio Ruiz-Luque[1], Macarena Ariza-Estepa[2], Jorge Díaz-Roldán[1], and Pablo Parra-Membrives[1]*

[1]Department of General and Digestive Surgery; [2]Department of Pathology. Valme University Hospital, Seville, Spain

Abstract

Objective: *We present a solitary fibrous tumor (SFT) of the abdominal wall treated laparoscopically.* **Method:** *We will discuss the clinicopathologic characteristics and will present a review of the literature.* **Results:** *SFTs are rare neoplasms of mesenchymal origin. Its location in the abdominal wall is extremely rare. To the best of our knowledge, only 20 cases have currently been described in the literature.* **Conclusions:** *Complete surgical resection is the main therapy for all cases. A laparoscopic approach is safe. Clinical-radiological follow-up must be carried out due to its uncertain behavior, and perioperative treatment may be necessary in high-risk patients.*

Keywords: *Extrapleural solitary fibrous tumor. Solitary fibrous tumor. Mesenchymal neoplasm.*

Resumen

Objetivo: *Presentamos un caso de tumor fibroso solitario de pared abdominal tratado por vía laparoscópica.* **Método:** *Se discuten las características clinicopatológicas y se presenta una revisión de la literatura.* **Resultados:** *Los tumores fibrosos solitarios son neoplasias raras de origen mesenquimatoso. Su localización en la pared abdominal es extremadamente rara. Hasta donde sabemos, solo se han descrito 20 casos en la literatura.* **Conclusiones:** *La resección quirúrgica completa es la terapia principal para todos los casos. El abordaje laparoscópico es seguro. Debe realizarse un seguimiento clínico-radiológico debido a su comportamiento incierto, pudiendo ser necesario un tratamiento perioperatorio en pacientes de alto riesgo.*

Palabras clave: *Tumor fibroso solitario extrapleural. Tumor fibroso solitario. Neoplasia mesenquimatosa.*

***Correspondence:**
María L. Ruiz-Juliá
E-mail: mlrj84@gmail.com

Date of reception: 13-04-2022
Date of acceptance: 03-06-2022
DOI: 10.24875/CIRUE.M22000801

Cir Cir (Eng). 2024;92(6):803-808
Contents available at PubMed
www.cirugiaycirujanos.com

2444-0507/© 2022 Academia Mexicana de Cirugía. Published by Permanyer. This is an open access article under the terms of the CC BY-NC-ND license (http://creativecommons.org/licenses/by-nc-nd/4.0/).

Introduction

Solitary fibrous tumor (SFT) is a rare neoplasm of mesenchymal origin. They are usually located at the intrathoracic level[1]. Other locations have been described[2], although, there are very few cases described based on the abdominal wall[1-15]. We present the case of an SFT of the abdominal wall (SFT-AW). We review its clinicopathologic characteristics based on current literature.

Case report

A 54-year-old woman suffering from renal lithiasis, that was referred to us due to an incidental finding on a computed tomography scan of a solid lesion in contact or arising from the major gastric curvature of 57 mm highly, suggestive of gastrointestinal stromal tumor (Fig. 1A). Physical examination was normal. No abdominal mass was palpable. The study was completed with endoscopic ultrasound. Endoscopic ultrasound revealed a 6 × 5 cm hypoechoic lesion with cystic areas. It was seemed to be dependent on the fourth layer of the gastric wall with extraluminal growth. A multidisciplinary team meeting was taken for surgical resection.

During surgery, a 6 cm diameter extraperitoneal tumor coming from the transverse muscle was found in the anterior abdominal wall. The aponeurosis was not affected. The tumor was removed by laparoscopy (Fig. 1B). A combination of two 5 and two 12 mm ports were placed in a semilithotomy position. Neither ascites fluid nor intra-abdominal lesions were visualized. The dissection headed through healthy tissue by electrocoagulation and the excision of tumor was completed by vessel sealer. The specimen was exteriorized through a 6-7 cm transverse incision by extending the 5 mm port on the left flank. The fascial defect was closed by primary repair using a continuous loop PDS suture. The patient was discharged after 24 h without any complications and is currently under disease-free follow-up.

The surgical specimen was fixed in 4% buffered formaldehyde and processed by standard techniques. The immunohistochemistry analysis was performed on the BenchMark ULTRA system (Ventana Medical Systems, Tucson, AZ) and using the following Ventana's antibodies: CD34 (clone QBEnd/10; primary antibody), CD99 (clone O13; mouse monoclonal primary antibody), bcl-2 (clone SP66; rabbit monoclonal primary antibody), S100 (polyclonal, primary antibody), beta-catenin (mouse monoclonal antibody), pan keratin (clone AE1/AE3/PCK26), CD10 (clone SP67; rabbit monoclonal primary antibody), actin smooth muscle (clone 1A4; mouse monoclonal antibody), desmin (clone DE-R-11; primary antibody), Ki-67 (clone 30-9; rabbit monoclonal primary antibody), and CD117/c-KIT (clone 9.7; primary antibody).

The external surface of the nodular surgical specimen was smooth with well-defined contours and marked vascularization. It measured 6 × 5 × 5 cm and showed mostly homogeneous solid whitish areas, of elastic consistency, with a microgranular surface. Multiple cystic formations with serous content were described, the largest one measuring 2 cm in maximum axis. A 2.5 cm solid pole of greater consistency was also identified. It presented a fine intact capsule.

The anatomopathological examination showed a markedly cellular formation with mild pleomorphism without necrosis, and also a hemangiopericytoma pattern with isolated outbreaks of hemorrhage (Fig. 2). The mitotic index was 2-3 mitotic/10 HPF. Immunohistochemistry revealed Ki-67 of ~7% (Fig. 3), strong positivity for CD34 (Fig. 4) and bcl-2, and weak for CD99. It was negative for CKAE1/AE3, smooth muscle actin, CD117, CD10, desmin, S-100, and beta-catenin. With these data, it was reported as SFT-AW.

Discussion

SFTs are rare neoplasms of spindle cell with fibroblastic or myofibroblastic characteristics, so any organ composed of mesenchymal cells has the potential to develop this type of neoplasm[11,13]. The most frequent extrathoracic location is in the abdomen (intraperitoneal, retroperitoneal, and pelvis). SFTs-AW represents < 2% of all soft-tissue tumors[2] and, to the best of our knowledge, 20 cases have currently been described in the literature (Table 1). SFTs have similar incidence in men and women, although SFTs-AW predominates in women[2]. Huang et al.[11] proposed a possible role of sex steroid hormones in the initiation or maintenance of these tumors. The most commonly diagnosis age is in the 50s and 60s[1]. In our review, we observed a wide age range of 21-79 years.

SFTs-AW usually appears as slow-growing and often asymptomatic masses, found as incidental discovery, as happened in our case. Therefore, they are

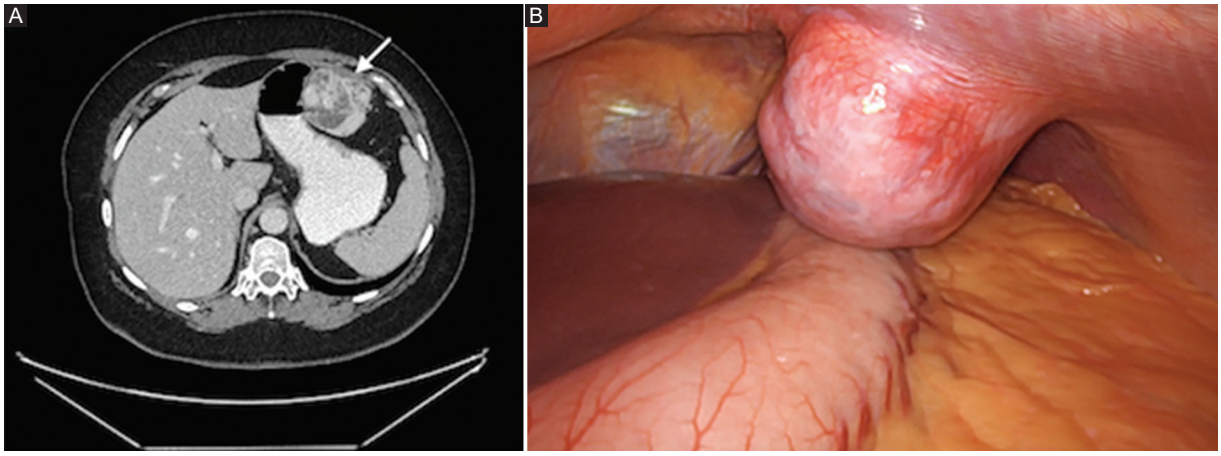

Figure 1. A: *computerized tomography: mass in intimate contact with the greater gastric curvature with dimensions of 6.1 × 6.3 × 5.4 cm in its transverse, anteroposterior, and craniocaudal axes, respectively. This lesion shows well-defined contours as well as a significant enhancement, delimiting hypodense areas inside it, probably due to necrosis.* **B:** *laparoscopic view of the tumor arising from the anterior abdominal wall.*

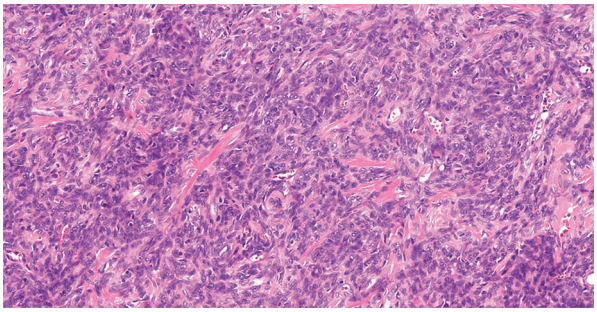

Figure 2. *Hematoxylin-eosin, ×20. Spindle cells with a patternless architecture, interspersed with collagen bundles with cracking artifact, and a characteristic hemangioperycitoid vascular pattern with staghorn vessels. This neoplasia is predominantly hypercellular with hypocellular areas, well-circumscribed, and with hemorrhagic areas with no evidence of necrosis.*

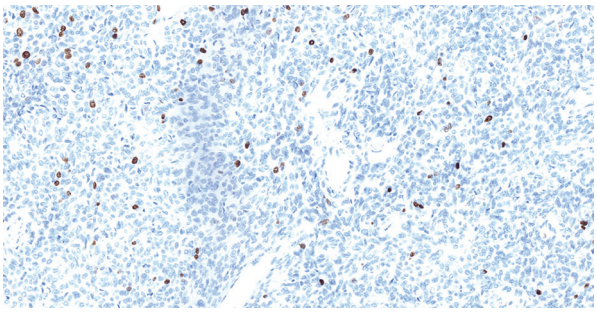

Figure 3. *Ki67 proliferative index of 7%.*

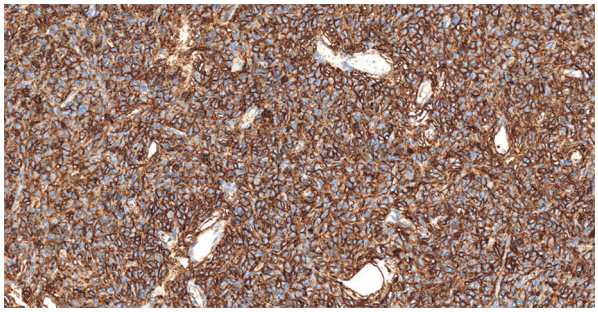

Figure 4. *Strong and diffuse positive immunostaining for CD34.*

difficult to diagnose and can simulate other mesenchymal neoplasms, both benign and malignant[2,13,16]. Both show radiological characteristics similar to other soft-tissue tumors and there are no specific pathognomonic findings for SFTs[1]. Neither fine-needle aspiration nor core-needle biopsy usually achieve a definitive diagnosis[1,14], requiring histological confirmation of the surgical specimen[1,16,17].

For an appropriate surgical resection, it must be considered that these neoplasms are encapsulated by a thin membrane that often contains small satellite lesions. If this capsule is not completely removed, residual satellite lesions can develop into deposits of micrometastases. Positive surgical resection margins are responsible for up to 40% of local recurrences and 75% of metastatic disease[16]. In our case, the resection was carried out safely and efficiently by laparoscopy, observing in the macroscopic study a fine whitish intact capsule and negative surgical margins.

Immunohistochemistry allows us to distinguish SFTs from other tumors. They are positive for CD34 in 90-95% of cases and for bcl-2 in 96% of cases. Other

Table 1. Reported cases of SFTs-AW

Case nº	Author	Age (years)/ Sex	Symptoms	Size (cm)	Treatment	Follow-up (months)	Recurrence	Metastases	IHQ CD34/ bcl-2	Malignancy
1	Mentzel et al.[5] (1997)	51/M†	Abdominal mass	4,8	Laparotomic surgical resection	NA§	NA	NA	+/NA	NA
2	Nielsen et al.[7] (1997)	NA	NA	NA	Laparotomic surgical resection	NA	-	-	+/NA	+
3	Vallat-Decouvelaere et al.[3] (1998)	50/F‡	Abdominal mass	1,9	Laparotomic surgical resection	13	-	-	+/NA	+
4	de Saint Aubain Somerhausen et al.[6] (1999)	45/F	Abdominal mass	14	Laparotomic surgical resection	ND	-	-	+/NA	-
5	de Saint Aubain Somerhausen et al.[6] (1999)	35/F	Painful abdominal mass	11,5	Laparotomic surgical resection	recent case	-	-	+/NA	-
6	Hasegawa et al.[9] (1999)	50/F	Abdominal mass	3	Laparotomic surgical resection	38	-	-	+/+	-
7	Hasegawa et al.[9] (1999)	60/F	Abdominal mass	5,5	Laparotomic surgical resection	156	-	-	+/+	-
8	Lee et al.[4] (2001)	67/M	Tumor in left inguinal hernia sac	1	Laparotomic surgical resection and hernia repair	39	-	-	-/NA	-
9	Lee et al.[4] (2001)	44/F	Tumor in ventral hernia sac	4,5	Laparotomic surgical resection and hernia repair	6	-	-	-/NA	-
10	Huang et al.[11] (2002)	50/F	Abdominal mass	4	Laparotomic surgical resection	14	-	-	+/+	-
11	Huang et al.[11] (2002)	38/F	Abdominal mass	7,5	Laparotomic surgical resection	12	-	-	+/+	-
12	Sawada et al.[8] (2002)	45/F	NA	3	Laparotomic surgical resection	NA	NA	NA	+/NA	NA
13	Ouazzani et al.[15] (2008)	66/M	Painless Abdominal mass	16	Laparotomic surgical resection	6	-	-	+/+	+
14	Migita et al.[13] (2009)	74/F	Abdominal mass	12	Laparotomic surgical resection	10	-	-	+/+	-
15	Mosquera et al.[10] (2009)	50/F	Abdominal mass	6,4	Laparotomic surgical resection	12	-	-	+/NA	-
16	Bi et al.[2] (2017)	79/F	Abdominal mass	15	Laparotomic surgical resection	48	-	+	NA	+
17	Testa et al.[12] (2019)	64/M	Abdominal mass	4,8	Laparotomic surgical resection	6	-	-	+/+	-
18	Fernández-Sanmillán et al.[14] (2018)	62/H	AUR‖	20	Laparotomic surgical resection	6	-	-	+/+	-
19	Ros et al.[1] (2020)	43/H	Micturition disorders	6	Laparotomic surgical resection	24	-	-	+/+	-
20	Ros et al.[1] (2020)	21/H	Supraumbilical lump	4	Laparotomic surgical resection	12	-	-	+/+	-

M: male; F: female; NA: not available; AUR‖: acute urinary retention.

common markers include vimentin and CD99 (70%). They usually show negative staining for cytokeratin, smooth muscle actin, desmin, S-100 protein, early membrane antigen, and c-kit[1,13].

The behavior of SFTs is usually benign, although local recurrence and even the appearance of metastasis are possible in 5-10% of patients, even 10 years after initial surgery, histologically benign SFTs included[12,18]. The mortality rate reported is 1%[16]. Histological characteristics related to malignancy include tumor size > 10 cm, high cellularity, and pleomorphism, more than 4 mitoses/10 HPF, presence of hemorrhage and necrosis, and incomplete resection[13,14]. Demicco et al.[19] developed a risk stratification model based on age, tumor size, and mitotic index, stratifying the study population into three groups: low risk, intermediate risk, and high risk. Distant metastases or deaths were not reported in the low-risk group. Disease-free survival at 5 years in the moderate and high-risk groups was 77% and 15%, respectively. Overall survival at 5 years in the moderate and high-risk groups was 93 and 60%, and 93 and 0% at 10 years, respectively.

The follow-up of these patients should be carried out with imaging tests every 3-6 months for the first 2-3 years and subsequently every 6-12 months up to 5 years, depending on the characteristics of tumor malignancy determined by histology and surgical resection margins[1]. Local recurrences can be controlled by new resection. However, the disseminated disease of SFTs does not usually respond to adjuvant treatments[20].

Conclusion

SFTs-AW is extremely rare mesenchymal tumors. Complete surgical resection is the main therapy for all cases, either through an open or laparoscopic approach. Clinical-radiological follow-up must be carried out due to its uncertain behavior, and perioperative treatment may be necessary in high-risk patients.

Funding

The authors declare that no funding was received.

Conflicts of interest

The authors have no related conflicts of interest to declare.

Responsabilidades éticas

Protección de personas y animales. Los autores declaran que los procedimientos seguidos se conformaron a las normas éticas del comité de experimentación humana responsable y de acuerdo con la Asociación Médica Mundial y la Declaración de Helsinki.

Confidencialidad de los datos. Los autores declaran que han seguido los protocolos de su centro de trabajo sobre la publicación de datos de pacientes.

Derecho a la privacidad y consentimiento informado. Los autores han obtenido el consentimiento informado de los pacientes y/o sujetos referidos en el artículo. Este documento obra en poder del autor de correspondencia.

Uso de inteligencia artificial para generar textos. Los autores declaran que no han utilizado ningún tipo de inteligencia artificial generativa en la redacción de este manuscrito ni para la creación de figuras, gráficos, tablas o sus correspondientes pies o leyendas.

References

1. Ros A, Cortés J, Belda T, Magan A, Illán-Gambín FJ, Aracil E, et al. Fibrous solitary tumor, a rare and ubiquitous neoplasy. J Surg Case Rep. 2020;6:rjaa156.
2. Bi X, Zhai J, Chun CD. Solitary fibrous tumor of the abdominal wall re-surfacing as unilateral pleural effusion and mass: a case report and review of the literature. Respir Med Case Rep. 2017;23:4-7.
3. Vallat-Decouvelaere AV, Dry SM, Fletcher CD. Atypical and malignant solitary fibrous tumors in extrathoracic locations: evidence of their comparability to intra-thoracic tumors. Am J Surg Pathol. 1998;22: 1501-11.
4. Lee JR, Hancock SM, Martindale RG. Solitary fibrous tumors arising in abdominal wall hernia sacs. Am Surg. 2001;67:577-81.
5. Mentzel T, Bainbridge TC, Katenkamp D. Solitary fibrous tumour: clinicopathological, immunohistochemical, and ultrastructural analysis of 12 cases arising in soft tissues, nasal cavity and nasopharynx, urinary bladder and prostate. Virchows Arch. 1997;430:445-53.
6. De Saint Aubain Somerhausen N, Rubin BP, Fletcher CD. Myxoid solitary fibrous tumor: a study of seven cases with emphasis on differential diagnosis. Mod Pathol 1999;12:463-71.
7. Nielsen GP, O'Connell JX, Dickersin GR, Rosenberg AE. Solitary fibrous tumor of soft tissue: a report of 15 cases, including 5 malignant examples with light microscopic, immunohistochemical, and ultrastructural data. Mod Pathol. 1997;10:1028-37.
8. Sawada N, Ishiwata T, Naito Z, Maeda S, Sugisaki Y, Asano G. Immunohistochemical localization of endothelial cell markers in solitary fibrous tumor. Pathol Int. 2002;52:769-76.
9. Hasegawa T, Matsuno Y, Shimoda T, Hasegawa F, Sano T, Hirohashi S. Extrathoracic solitary fibrous tumors: their histological variability and potentially aggressive behavior. Hum Pathol. 1999;30:1464-73.
10. Mosquera JM, Fletcher CD. Expanding the spectrum of malignant progression in solitary fibrous tumors: a study of 8 cases with a discrete anaplastic component--is this dedifferentiated SFT? Am J Surg Pathol. 2009;33:1314-21.
11. Huang HY, Sung MT, Eng HL, Lee TY, Ko SF, Wang CC, et al. Solitary fibrous tumor of the abdominal wall: a report of two cases with immunohistochemical, flow cytometric, and ultrastructural studies and literature review. APMIS. 2002;110:253-62.
12. Testa DC, Selvaggi F, Andreano T, Mazzola L, Cortellese R. Solitary fibrous tumor of the anterior abdominal wall. A case report and review of the literature. Ann Ital Chir. 2019;8:13;8:1-5.
13. Migita K, Watanabe A, Nakagawa K, Ohyama T, Sekigawa S. Solitary fibrous tumor of the abdominal wall. Int J Clin Oncol. 2009;14:555-9.
14. Fernández-Sanmillán D, De Melo Santos DM, Fernandez EL, Hernandez JR. Acute urinary retention due to solitary fibrous tumor of the abdominal wall. Turk J Urol. 2018;45:471-3.

15. Ouazzani A, Delrée P, De Saint Aubain N, Ceuterick M, Boudaka W. Malignant solitary fibrous tumor of the abdominal wall in a man. Ann Chir Plast Esthet. 2008;53:517-20.
16. Kayani B, Sharma A, Sewell MD, Platinum J, Olivier A, Briggs TW, et al. A review of the surgical management of extrathoracic solitary fibrous tumors. Am J Clin Oncol. 2018;41:687-94.
17. Orue-Echebarria MI, Garciafília L, Rodriguez-Bachiller L, Díaz-Zorita B, Velasco E, Ramón E, et al. Solitary extrapleural fibrous tumor with hepatic bilobar metastases: multimodal approach treatment. Clin Sarcoma Res. 2020;10:23.
18. Ronchi A, Cozzolino I, Marino FZ, Accardo M, Montella M, Panarese I, et al. Extrapleural solitary fibrous tumor: a distinct entity from pleural solitary fibrous tumor. An update on clinical, molecular and diagnostic features. Ann Diagn Pathol. 2018;34:142-50.
19. Demicco EG, Park MS, Araujo DM, Fox PS, Bassett RL, Pollock RE, et al. Solitary fibrous tumor: a clinicopathological study of 110 cases and proposed risk assessment model. Mod Pathol. 2012;25:1298-306.
20. Wilky BA, Montgomery EA, Guzzetta AA, Ahuja N, Meyer CF. Extrathoracic location and "borderline" histology are associated with recurrence of solitary fibrous tumors after surgical resection. Ann Surg oncol. 2013;20:4080-9.